

We are IntechOpen, the world's leading publisher of Open Access books Built by scientists, for scientists

7,300

Open access books available

192,000

International authors and editors

210M

Downloads

Our authors are among the

154

Countries delivered to

TOP 1%

most cited scientists

14%

Contributors from top 500 universities



WEB OF SCIENCE™

Selection of our books indexed in the Book Citation Index
in Web of Science™ Core Collection (BKCI)

Interested in publishing with us?
Contact book.department@intechopen.com

Numbers displayed above are based on latest data collected.
For more information visit www.intechopen.com



Complications in Scoliosis Surgery

Femenias Rosselló Juan Miguel and Llabrés Comamala Marcelino
*Department of Orthopaedic Surgery and Traumatology
Hospital Son Espases
Palma de Mallorca,
Spain*

1. Introduction

The surgical treatment of all types of scoliosis pursues correction of the deformity, get a solid spinal fusion and balance the trunk in the sagittal and coronal plane. For this it is necessary to perform technically demanding surgery, long lasting, with great exposure of the surgical field, high blood loss and ultimately extremely aggressive. No doubt we can say that scoliosis surgery is one of the more complex interventions that are performed in orthopedic surgery. This makes complications of these surgeries not uncommon and potentially very serious.

Constant improvement of fixation systems, evolution of anesthesiology techniques as well as the Intensive Care Services have helped to reduce and better manage the complications that may arise from these surgeries, but it is also true that for these same causes more complex patients go after surgery.

The purpose of this chapter will be to conduct a review of the literature published complications from the surgery of scoliosis develop and deepen their study.

2. General

Scoliosis is defined as a three-dimensional deformity of the spine as torsion about its longitudinal axis. Lateral tilt occurs in the frontal plane resulting in a curve. The deformity must be accompanied by vertebral rotation. Vertebral body rotates toward the convexity, while the spinous processes rotate toward the concavity. When the curve in the frontal plane is not accompanied by rotation we speak of scoliotic attitude, which is never a permanent deformity.

The transmission of loads in scoliosis is not uniform. The asymmetry of the pressures on the vertebrae because of its tilt and rotation determines a wedge with its vertex in the concavity and its base in the convexity.

When ossification of the wedge vertebrae is completed and ligament and disc deformity is fixed, we talk of a structured curve, which is stiff and difficult to modify by gravity action or traction maneuvers.

In order to systematize the etiology, course and prognosis of scoliotic deformities, the Scoliosis Research Society has developed a universally accepted classification.

2.1 Idiopathic scoliosis

Constitute over 80% of all scoliosis and its cause is unknown. It is more common in girls by a ratio of 7:1. Depending on the age in which it is diagnosed is divided into three types:

- Infantile idiopathic scoliosis: from birth to 3 years old.
- Juvenile idiopathic scoliosis: between 4 and 9 years.
- Adolescent idiopathic scoliosis: from 10 years and skeletal maturity.

2.2 Congenital scoliosis

Vertebral deformities caused by birth. They can be caused by defects of formation (hemivertebra) or segmentation defects.

2.3 Neuromuscular scoliosis

Are due to primary neurological alterations or muscle disorders that cause loss of control of the trunk because of weakness or paralysis.

- Neuropathic. Due to upper motor neuron affection (cerebral palsy is the most common) or lower motor neuron affection (polio, spinal muscular atrophy, etc).
- myopathic. Secondary to muscular dystrophy (the most common is Duchenne muscular dystrophy), arthrogyrosis, congenital hypotonia, and so on.

2.4 Other

Secondary to connective tissue diseases, neurofibromatosis, traumatic or intra or extradural spinal tumours, etc...

Although in all cases of scoliosis surgery can occur both intra-and postoperative complications, there are multiple factors that increase the risk of such complications.

Neurological and connective tissue diseases scoliosis are often associated with congenital heart disease and with severe restrictions on the patient's respiratory vital capacity. This fact, coupled with the high blood loss that occurs during surgery can lead to severe hemodynamic failure.

Adult scoliosis is defined as the occurrence of scoliosis deformity after the patient has reached skeletal maturity. Surgical treatment of scoliosis in the adult has a much higher rate of complications when compared to the correction of the same type of deformity in the adolescent. Some factors that contribute to this higher rate of complications are:

- Important bleeding because of the difficult subperiosteal detachment of the muscles of the rear column.
- Higher structural stiffness of the curves.
- Less rigid anchoring of the instrumentation due to osteoporosis of the bone.
- Increased difficulty to accomplish fusion in the elderly patients.

- Appearance of medical complications during and after the intervention due to the greater duration of the same, the increased risk of infection and the risk of deep vein thrombosis and pulmonary sequelae.
- Patient's nutritional depletion following major spinal reconstruction that makes necessary optimize the patient's nutritional status.

Although all types of complications can occur in scoliosis of any etiology, in healthy subjects with idiopathic scoliosis, the incidence of complications can't be as high as in patients with neuromuscular diseases. In a systematic review of the literature in PubMed on the rate of complications in scoliosis surgery (Rudolf Weiss & Goodall, 2008) the rate of complications for the different causes was specified (Table I). This study found that those fusions extended to the pelvis in idiopathic scoliosis showed higher complication rate (73%).

	Studies	Average rate	Range
Neuromuscular Scoliosis	22	35% SD(21)	0-89%
Adult Scoliosis	11	44% SD(24)	10-78%
Idiopathic Scoliosis	11	20% SD (22)	0-73%
Early Onset Scoliosis	1	48%	
Congenital Scoliosis	4	14% SD (23)	0-48%
Congenital Heart Disease	1	27%	

Table 1. Hans Rudolf Weiss & Deborah Goodall. Scoliosis 2008. Complications rate for the different causes of scoliosis.

Therefore, it is imperative to have a thorough knowledge of the preoperative characteristics of each patient to know the possible complications that may arise during or after surgery.

3. Preoperative assessment of patients with scoliosis

Complications in the surgical treatment of scoliosis can occur in all patients, but are especially important in patients with neuromuscular diseases. Because of this a comprehensive assessment of all patients that will be operated on for scoliosis must be made preoperatively, but especially in neurological patients because in these cases the deformity of the spine may be associated with, in some cases, respiratory function and heart alterations. These changes, along with the pathology of the disease itself, cause of the deformity (for example deformities secondary to neuromuscular disease) are risk factors that modify the anesthetic-surgical prognosis of patients with scoliosis.

Respiratory disturbances, cardiovascular abnormalities and multiple changes experienced by patients with scoliosis secondary to neurological diseases are a very important risk factor in patients about to undergo surgery for scoliosis.

It is essential to have a thorough understanding of the characteristics of each patient regarding the etiology of the scoliosis to know the possible complications that may arise, with particular attention to nutritional status, assessment of respiratory and cardiovascular function and neurological status preoperatively.

3.1 Nutritional status

It is necessary to make an assessment of patient's nutritional status prior to surgery. In neurological patients is very common that nutritional status is poor and therefore they are at increased risk of infections and wound dehiscence. It is very important to optimize the nutritional status of the patient before surgery, although in these cases is very difficult. It may be necessary to place a feeding jejunostomy tube when it is insufficient by mouth. In the postoperative period it may be useful the administration of parenteral-nutrition.

3.2 Respiratory function

It is known that respiratory restriction in idiopathic scoliosis is low, except in high-grade scoliosis.

It is important to note that respiratory function is mainly affected in thoracic scoliosis. There is a direct relationship between impaired lung function test and the magnitude of the thoracic curve. It has been observed that significant changes in lung function are found when the deformity curves have a Cobb angle greater than 70-80°. In these cases, diaphragm function is impaired, so respiratory function depends on a greater degree of accessory muscles.

In major thoracic scoliosis, the deformity alters the position of the ribs decreasing the anteroposterior diameter of the chest producing a defect of coupling between the respiratory muscles and rib cage which results in a decreased mobility of the chest and a loss of respiratory mechanics ability to adapt to rapid respiratory changes (Colomina & Godet 2005).

This alteration in respiratory mechanics results in a restrictive pattern. This involves a small lung volume, increased work of breathing, high energy costs, hypoxemia, respiratory acidosis by hypoventilation, inadequate ventilatory response to hypoxic stimulus, pulmonary hypertension, limitation of the development of lung parenchyma and anomalous relationship between lung function and respiratory muscle mechanics (Molina et al., 2003).

The prognosis of scoliosis secondary to neuromuscular disease is worse than idiopathic scoliosis, and in fewer years it will evolve into respiratory failure. Curves over 30 degrees can have a severe respiratory impairment as it happens in muscular dystrophies.

The causes that influence respiratory disturbances in patients with neuromuscular diseases have been studied (Colomina & Godet 2005).

- A disturbance in the central control of breathing
- Myopathies and nerve damage in these patients have the effect of an alteration of muscle function. The loss of respiratory muscle strength has a direct effect on respiratory function.

The deterioration of respiratory function is progressive and depends on the loss of respiratory muscle strength, which may affect both the inspiration and the expiration. It is shown that in Duchenne muscular dystrophy vital capacity decreases by 8% per year (Galaska et al., 1992).

Abnormalities of respiratory function may also be aggravated by joining the alteration of the defense mechanisms of the airway, with loss of laryngeal and pharyngeal reflexes, which along with muscle weakness will condition an ineffective cough and lung facility, and anomalous relationship between lung function and respiratory muscle mechanics.

The relationship between the magnitude of the thoracic curve and a lower respiratory vital capacity is amply demonstrated in idiopathic scoliosis, but in neuromuscular scoliosis this relationship is not as clear, as we have seen, there are a multitude of factors that influence in the impairment of respiratory function.

It has been shown that scoliosis surgery produces immediate and transient decrease in vital capacity (CV) of up to 40% in almost all patients undergoing surgery (Koumbourlis, 2006). The reasons for this decline are many, including the duration of the operation, the patient positioning and surgical trauma to various muscle groups (especially when it has practiced a thoracotomy). Given that the CV is usually much lower than normal before surgery, any further reduction can easily lead to respiratory failure. This risk is significantly higher in patients with neuromuscular scoliosis for reasons already explained.

As a result of this, during the preanesthetic visit a thorough assessment of respiratory function by physical examination, detailed previous history, and specific additional examination (respiratory function tests, arterial blood gases) must be conducted. In many neurological patients can be very difficult to perform pulmonary function tests, so it is very important the opinion and experience of the patient's usual pulmonologist.

3.3 Cardiovascular function

As the alteration of respiratory function, cardiovascular abnormalities occur primarily in thoracic scoliosis. In large deformities of the thoracic spine there is an alteration of the position and function of the mediastinal structures affecting the pericardium and great vessels and may mimic constrictive pericarditis, pulmonary hypertension and right ventricular failure (Colomina & Godet 2005).

Congenital scoliosis is often associated with primary heart disease or cardiac conduction disorders. This is due to the embryonic disorder that causes the appearance of this type of scoliosis. In Marfan syndrome is frequent valvular disease, especially mitral valve. Friederich's ataxia is often associated with hypertrophic cardiomyopathy and arrhythmias. They may also have dilated cardiomyopathy because of myocardial degeneration in the muscular dystrophies. Other malformations that are frequently associated with congenital scoliosis are tetralogy of Fallot, transposition of great arteries, ductus, etc..

To rule out the existence of these cardiac abnormalities is necessary to conduct a systematic cardiological examination with ECG and echocardiography, especially in the preoperative exam in patients with congenital scoliosis.

3.4 Neurological status

Congenital scoliosis has an incidence of up to 40% of intraspinal abnormalities. Some of these abnormalities are lipomas, benign fatty tumors of the spinal canal, scar tissue within the spinal canal, osteocartilaginous bone spicules that can cause a diastematomyelia, and so on.

A thorough clinical examination of neurological status of the patient and cranial and complete spine MRI are essential in the preoperative evaluation of patients with congenital and neuromuscular scoliosis.

4. Classification of the complications of scoliosis surgery

The appearance of complications in scoliosis surgery itself or derived from it is not uncommon for many reasons already discussed. It is very difficult to systematize and collect all the complications of scoliosis surgery described in the literature. Some authors classify them according to severity. Others depending on the time of appearance (intraoperative, immediately after surgery or belated). We will follow the scheme proposed by Hawes in 2005, modified.

- Vascular and visceral injuries.
- Hemodynamic complications.
- Neurological complications.
- Gastrointestinal complications.
- Infections.
- Failure of instrumentation and nonunion.
- Decompensation and increased deformity.
- Pathology of adjacent level.
- Other complications.

4.1 Vascular and visceral

Scoliosis surgery often requires anterior approach of the column involving laborious dissection of visceral and vascular structures in contact with the spine.

Although vascular and visceral injuries occur more frequently in the anterior approach they can also occur in other situations. In the posterior approach of the thoracic spine, pleural damage may occur. If so, it is advisable placing a pleural drainage tube. It's also been described in the literature gluteal artery injury caused by removing large amounts of graft from the iliac crest.

The placement of pedicle screws can also cause vascular and visceral injuries. This technique is not free from risks due to the close anatomical relationship between the spine and the aorta and other major retroperitoneal structures. The risk of misplacement of pedicle screws is increased in scoliosis surgery, especially of high magnitude, compared to other surgeries of the spine due to anatomical changes caused by vertebral rotation. Vascular injuries may occur during insertion of pedicle screws or deferred usually presented as pseudoaneurysms. All such injuries occur as a result of injury of the anterior or lateral cortical of the pedicle. Exceptionally injuries can also occur during surgery pedicle screw removal. Our team has published a case of gonadal and renal vein injury and duodenal ulcers during the attempt of removal of a malpositioned pedicle screw in an adult scoliosis. There was a violent migration of the screw toward the anterior part of the vertebral body, coming to stay in the abdominal cavity. It was necessary to turn the patient in the supine position, a laparotomy to locate the screw at the root of the mesentery and then extraction of the screw and reparation of vascular and duodenum lesions were performed (Femenias et al., 2009).

4.2 Hemodynamic complications

As already mentioned in the introduction of this chapter, scoliosis surgery is surgery of long duration, with great exposure and high blood loss. If this high blood loss is not properly answered it can lead to hemodynamic failure. To minimize blood loss is very important a meticulous surgical technique with respect to hemostasis and frequent hemostatic plugs during skeletonization, but there are circumstances that may aggravate the bleeding.

Patients with neurofibromatosis present hyper vascularization around neurofibromas, patients with coagulopathy or cardiac malformations also have a high risk of bleeding.

All the situations already described along with the need to curettage large bone areas or the need of vertebral osteotomies can produce excessive bleeding leading to severe hemodynamic failure and even death of the patient.

The decrease in respiratory vital capacity occurs especially in severe scoliosis and neuromuscular scoliosis with the appearance of atelectasis due mainly to severe pain after surgery, the chest tightness and weakening of the defense mechanisms of the air way, with loss of laryngeal and pharyngeal reflexes and muscle weakness together cause hypoxemia. This situation of hypoxemia along with the excessive bleeding that can result from factors already discussed certainly leads to hemodynamic instability.

Another situation that can lead to hemodynamic failure is intraoperative hypothermia as it can trigger an arrhythmia and myocardial depression. It is important to prevent hypothermia, the patient must be adequately covered in the unexposed areas, warming the skin and administering all fluids with temperature.

The advancement of endoscopic techniques has its impact on the evolution of surgical treatment and the lower incidence of hemodynamic complications. The advent of thoracoscopy has greatly decreased the need for thoracotomy to ease the thoracic spine. With this technique, surgical aggression is much lower, reducing analgesic requirements, bleeding and respiratory affectation.

In these patients during the surgical procedure, the controlled hypotension and self-transfusion techniques are very important for greater hemodynamic stability, blood loss savings and reduction of the number of blood units for transfusion.

4.3 Neurological complications

Neurological injuries are perhaps the most feared injuries in scoliosis surgery, with devastating results for the patient and his family.

To monitor and try to combat the onset of these complications is very important neurological intraoperative monitoring through the awaking test and electrophysiological monitoring with evoked potentials. Neurophysiological monitoring in spine surgery should be considered mandatory not only for surgical reasons but also due to the adjuvant techniques used such as controlled arterial hypotension.

Probably the most traditional method used to monitor neurological function test is Stagnara awakening. This test is performed after completion of the reduction maneuvers for scoliosis, and the goal is to reduce the level and depth of anesthesia to achieve a state of waking of the

patient enough to move his limbs. Once the test is finished, a level of deep anesthesia is obtained to allow completion of the intervention (Vauzelle et al., 1973). However it is known that this test has many limitations among which the failure to prevent possible early injury, is not sensitive enough to small fluctuations of medullary function and that evaluates only the anterior spinal cord.

Lonstein group in a 1980 study placed the incidence of neurological injury from 3.7 to 6.9%. With the advent of intraoperative neurophysiological monitoring techniques spine surgeons have reduced the incidence figures to 0.5% and now is possible to detect alterations in the function of the spinal cord at an early stage so the surgeon can correct the situation before irreversible damage occurs. Neurophysiological monitoring of somatosensory PES and motor PEM evoked potentials is done by analyzing the latency and amplitude of the response to the stimulus caused. The PES analyzes the integrity of the posterior way from the peripheral nerves to the cerebral cortex. The PEM is the result of stimulating the cortex or the medulla and collecting the response in the peripheral nerves or muscles directly innervated by these nerves. Keep in mind that these potentials may be affected by hypothermia and hypoxia.

The causes that can produce these neurological complications may be due to reduced vascular blood flow, metabolic or mechanical direct contusion or stretching. Depending on the cause, the injuries can range from mild root injury to paraplegia and quadriplegia (Hawes, 2005). In rare cases it may also present as a cauda equina syndrome when working distally to L3. It also may occur infrequently dural tears when performing the way for the insertion of sublaminar hooks (Fig. 1).

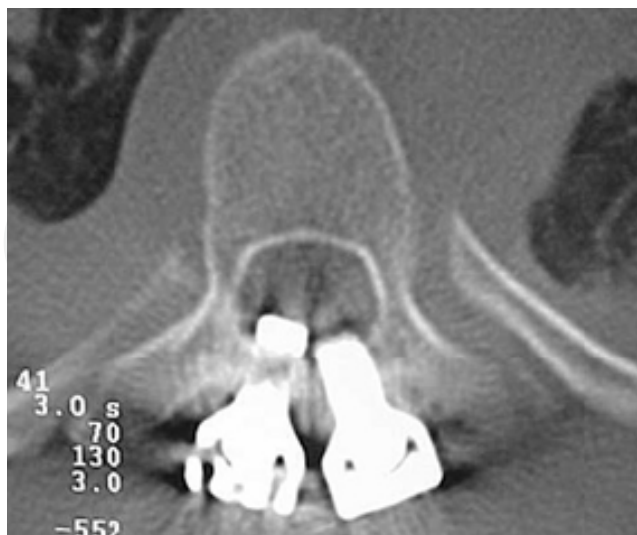

Fig. 1. CT Scan showing the intimate connection between sublaminar hooks and the spinal cord.

The critical point to cause spinal cord injury during surgery is when derotation and distraction maneuvers of the spine are performed to correct scoliosis. There is risk of generating excessive traction and cause spinal cord damage due to tension changes in the vessels supplying the spinal cord which can alter blood flow and produce a spinal cord dysfunction. Direct contusion is also a very important cause of neurologic injury. There are published cases of bone graft migration into the spinal canal, penetration of instrumentation into the spinal canal, compressive phenomena because of hematomas and nerve compression by the components of the implants.

The type of instrumentation used also has a direct relationship to neurological damage. During the Harrington instrumentation era, incidence was lower than the highly invasive instrumentation such as Luque and variants. With increasing use of pedicle screws root injuries have increased. The pedicle screw may violate the medial pedicle wall and invade the spinal canal or break the lateral wall (Fig. 2). It is important intraoperative radiographic control to ensure correct placement of pedicle screws as well as stimulating each screw to rule changes in the neurophysiological recording. If there's a suspicion that a screw may cause nerve irritation it should be removed or relocated.

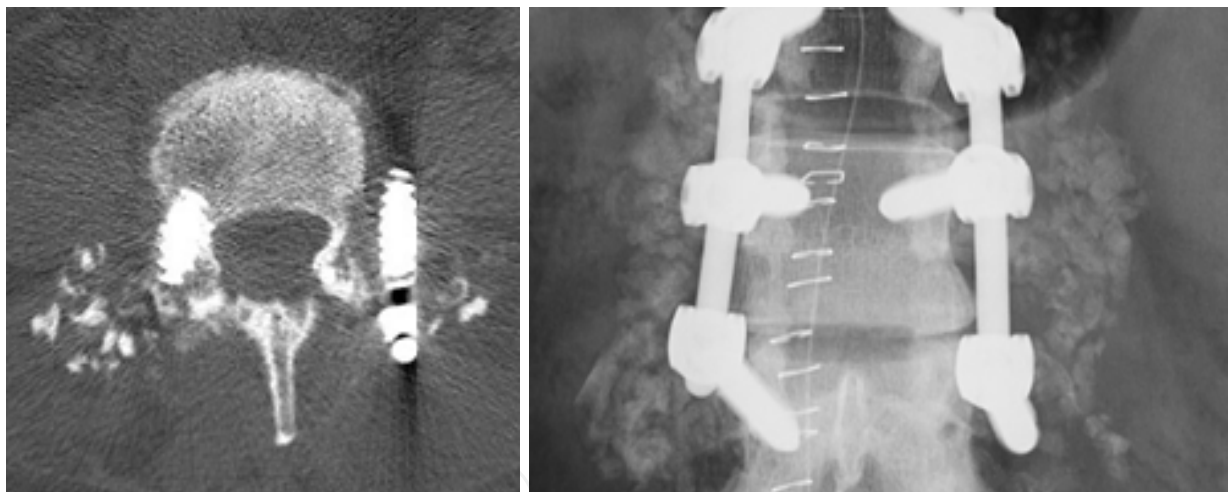


Fig. 2. Radiographic and CT image showing the extrapedicular position of the screw.

When a neurological disorder at the time of awakening test or a change in the amplitude or latency of the SSEP is noted, the correction should be decreased until the patient move his limbs normally and / or recovers potentials.

It can happen that a patient in the postoperative period does not present any neurological problems but afterwards develops paralysis within a few hours. In this case is very important to check blood pressure. If there is a problem of hypotension is important to correct it because as blood pressure increases improves the paralysis. If not, patient must be taken to the operating room immediately to cut the bars or revoke the instrumentation.

4.4 Gastrointestinal complications

Digestive complications are not uncommon in scoliosis surgery. It can be found in the literature paralytic ileus, stress ulcers, pancreatitis and superior mesenteric artery syndrome.

Postoperative ileus is frequently present in the instrumentation of the spine and scoliosis surgery in particular. When distraction mechanisms to reduce scoliosis are performed, peritoneum suffers a mechanism of traction and along with the use of opioids produces an intestinal paralysis.

Stress ulcers, like all major surgery can occur after surgery for scoliosis. It is important the administration of gastric protectors to prevent this complication.

Pancreatitis appears as a postoperative complication of scoliosis surgery in children and young adults. Etiology is unknown but is related to the patient's position, anemia, anesthetic agents, metabolic factors and autonomic nervous system abnormalities that could affect pancreatic secretion. It should be suspected with the appearance of vomiting and abdominal pain. If there's suspicion, blood test should be requested to evaluate amylase and lipase levels in serum. The evolution is usually favorable with prolonged postoperative fasting and parenteral nutritional support if required.

The syndrome of the superior mesenteric artery (SAMS) is produced by a closure of the exit angle of the superior mesenteric artery from the aorta that causes extrinsic compression of the third portion of duodenum. This is attributed to excessive stretching of the spine or extrinsic compression with corrective casts. The symptoms are rather nonspecific. These patients may present in postoperative nausea, permanent bilious vomiting, pain and bloating. To confirm the diagnosis, abdominal radiography showing gastric and first portions of the duodenum dilatation should be taken. Also intestinal transit study with the presence of obstruction of the contrast at the second or third portion of the duodenum where it intersects with the spine is defining. Medical treatment with fluid therapy, parenteral nutrition and nasogastric tube is usually the solution. In extreme cases, given the failure of medical treatment, a duodenojejunostomy should be practiced. Almost all cases reported in the literature are related to the implementation of Harrington device. Currently, its occurrence is exceptional.

4.5 Infectious complications

Infection rates in scoliosis surgery range between 2 and 6% (Hilibrand et al., 2003). There are multiple risk factors that influence in the occurrence of postoperative infections. The prolonged duration of surgery, severe blood loss, morbid obesity, scoliosis requiring multiple procedures or stages, malnutrition, etc.

In a report from the Scoliosis Research Society Morbidity and Mortality Committee (Smith et al., 2011) the reported rate of postoperative spine infection in scoliosis surgery is analyzed including subdiagnosis, patient age, spinal level, primary versus revision surgery, and surgical approaches to determine the corresponding rates of infection and to assess for potential factors associated with the occurrence of infection.

It is very important, in cases with high risk of infection, to optimize the patient's ability to heal following surgery for scoliosis, especially with adequate nutritional replacement.

We recommend a lymphocyte count greater than 1500 cells/mm³ and an albumin level greater than 3.4 g / dL to make the risk of infection due to immunodeficiency in these patients not too high.

The general recommendation for antibiotic prophylaxis is to administer first generation cephalosporin 20 to 30 minutes before surgery and then 3 doses postoperatively. If one keeps the antibiotic longer it may appear resistance to the antibiotic.

The recommendation for using first-generation cephalosporins is because it provides broad coverage against *Staphylococcus aureus* and *Staphylococcus epidermidis* which are the organisms that are isolated more frequently in infections in scoliosis surgery. Cefazolin is a first generation cephalosporin and is recommended as first choice because it reaches peak serum level and does so during the first 20 minutes after administration and has a long half-life compared to other first-generation cephalosporins.

Infections in surgery of scoliosis can occur immediately after surgery or late. Early infections occur during the first 7-10 days of postoperative period and present with fever, wound erythema, pain and drainage. If you perform a blood test is usually seen a rise in Erythrocyte Sedimentation Rate (ESR) and C-reactive protein (CRP).

In case of occurrence of an early infection cures of the wound are recommended daily, making crops for specific antibiotic treatment and, if not resolved, it requires a wide surgical debridement with copious irrigation of the wound, removal of slough and closing the surgical wound leaving drainage. In these cases, the instrumentation should not be removed. Then, once you have the antibiogram result, specific intravenous antibiotics should be instituted according to it.

In late infections after a symptom-free period, patients begin with localized inflammation of the wound, pus out and the presence of sinus tracts. In these cases the surgical strategy consists of debridement and cleaning as in early infection and it may be necessary to remove the implants if loosening is proved.

It may sometimes happen that a debridement is not enough and is needed repeated debridement of the wound until the resolution of the infection.

If that is associated with extensive skin necrosis or severe wound dehiscence which makes impossible to close, it may be necessary surgical mobilization of the muscle and skin for closure or, in more advanced cases, plastic surgery techniques consisting of flaps or expanders.

4.6 Instrumentation bugs and nonunions

To correct and stabilize scoliosis correction accomplished, spinal instrumentation is essential. A fault in the instrumentation inevitably entails the development of pain and loss of correction obtained.

Implant failures may occur due to poor location of the same or by having to resist excessive tension to hold the achieved correction of scoliosis

We have seen how the pedicle screws placed outside the pedicle can cause neurological symptoms or vascular compression, but besides that these screws have less gripping force

and compromise the stability of the reduction. Pedicle hooks can also migrate if not properly hooked on the pedicle. Laminar hooks under excessive kyphosis pressure can dislodge because a fracture of the lamina and, like it happens with screws, compromise mounting stability especially if the bars are placed with excessive tension. In all these cases, if stability is compromised or if the bar produces a protrusion on the skin that bothers the patient, the implant must be repositioned.

In the long term, instrumentation failure can occur as we have seen because the emergence of infections. Another cause of failure of the instrumentation is the debris of particles of the implants. This particle release stimulates autoimmune responses that result in deterioration of bone quality and in loosening of the implants. These inflammatory responses to metallic instrumentation can occur independently or associated with infection (Fig. 3).

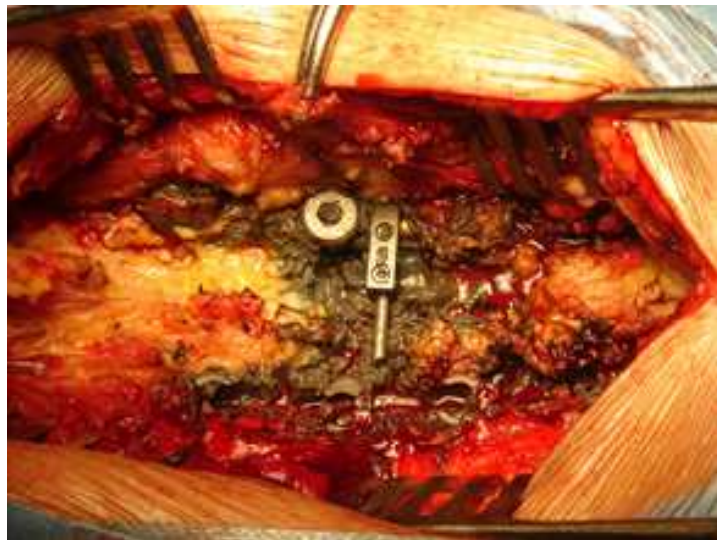


Fig. 3. Image of metallosis due to particle debris.

Although it may seem paradoxical, fewer mobilizations and material failure were seen in the past. This is because fewer implants were used as anchor points in the column and most stringent postoperative containment methods were adopted, such as casting and prolonged rest. Today, thanks to the improved quality of implants and to changes in evolution in the quality of life of society these uncomfortable patient immobilization systems will not be faced and the trend is towards to an early rehabilitation and a quick return to the normal daily activity. In general terms, and to try to prevent these failures of the material, we recommend limiting the sport until 6 months after surgery and, if mentioned sport requires contact or lifting this limitation can be extended to the year.

The late failure of the instrumentation is often associated with nonunion. The nonunion indicates a failure in the aim of the intervention since no solid spinal fusion is achieved. The consequence is that the instrumentation must assume all the forces and suffers permanent micromotion coming to be insufficient, so it results in material failure and rupture of the implants. The form of expression is the appearance of pain and progression of the deformity.

There are local, general and technique causes that increase the risk of developing pseudarthrosis. Locally there are areas of the spine more predisposed to defects such as lumbosacral areas (Edwards et al., 2004). Among the general causes we can enumerate old age, malnutrition and nicotine use which affect in a higher incidence of nonunion and postoperative infections. With regard to technical considerations, the existence of previous laminectomy or dysraphism limits the field to make a good fusion.

Advances in instrumentation and fusion techniques have produced a steady decline in the rate of nonunion. In adolescent idiopathic scoliosis nonunion rate is approximately 0,5-1% (Hicks et al., 2010). However, this percentage is higher in neuromuscular scoliosis (Reames et al., 2011).

If a nonunion is diagnosed, it must be repaired by defect curettage and new bone grafting or it may be necessary to perform an anterior approach to ensure a circumferential fusion.

4.7 Increase decompensation and sagittal deformity

The alteration of the sagittal profile is a major problem when there is a reduction of scoliosis. Classically it was very common when using Harrington stems acting on distraction which did not correct the vertebral rotation. The result was a loss of lumbar lordosis due to the correction of the sagittal lumbar plane (flat back syndrome). This fixed sagittal imbalance syndrome is characterized by progressive lumbosacral pain, forward bending of the trunk, inability to maintain an upright position and a serious aesthetic alteration. In extreme cases it could lead to obstructive lung problems.

When we started correcting scoliosis by rotation of the vertebral bodies the incidence of flat back decreased significantly but other causes of imbalance appeared, such as the selective application of fusion in special cases trying to preserve lumbar curves that should be fused to avoid long arthrodesis. In these cases, due to poor planning, it can occur progression of the non-fused curve resulting in high imbalances of the trunk.

The use of anterior mountings can also cause an alteration of the sagittal profile as it is known to have a recognized kyphosis effect. Surgeon must know very well the anterior instrumentation indications and try to avoid them in case of thoracic kyphosis above 40°.

Another source of imbalance is crankshaft phenomenon (Dubousset et al., 1989). Occurs after posterior spinal fusion in immature patients (Risser less than 1 and less than 10 years) and is attributed to the constant growth of the vertebral body in the anterior part which takes the posterior fixed structures as the axis of rotation. The consequence is an increase in the angular value of the curve and an increase in the thoracic hump. The thoracic hump deteriorates mainly due to the fact the surgical treatment improves the central axis, that is the spinal curve, but it is not affecting the deleterious forces acting on the thorax, which probably lead to the deformity (Grivas et al., 2008). In these very immature patients is advisable to perform surgery involving anterior and posterior fusion to prevent this phenomenon.

4.8 Pathology of adjacent levels

The appearance of disc and intervertebral joints degeneration above or below the instrumentation is a common complication of scoliosis surgery, especially if there is a

sagittal imbalance. Some of the patients experiencing this problem may require revision surgery to perform an extension of the arthrodesis.

Another adjacent level pathology described in the literature is the occurrence of acute vertebral fractures at the end of long instrumentation after spinal deformities surgery. These fractures are especially common in adult scoliosis due to the high rate of osteoporosis that can present these patients. It has been reported the incidence of this event in 4.9% (O'Leary et al., 2009). These fractures may be accompanied by severe neurological deficits.

4.9 Other complications

There are many other complications been reported in patients undergoing scoliosis surgery. Many of these complications are common to any other major surgery. The syndrome of inappropriate secretion of antidiuretic hormone, cholelithiasis, cervical pain, recurrent meningitis, renal failure due to ureteral compression by the implants, blindness caused by occlusion of the central retinal artery, thromboembolism, urinary infections, etc..

Many of the complications we have discussed, in extreme cases can lead to the most serious complication which is patient's death. The incidence of death as a complication of scoliosis surgery in healthy patients is less than 1%. Life expectancy in patients undergoing neuromuscular scoliosis with complex pathologies dramatically decreases.

5. Conclusions

Spinal deformities are a problem that affects a heterogeneous group of patients. The surgery required to correct or stabilize these deformities is in all cases very demanding and aggressive for the patient and has frequent complications with different incidence depending on the etiology of scoliosis.

It is very important, when there is an indication of surgery for scoliosis, to inform the patient and the family of the objectives pursued with this surgery, but also be very objective and clear about the complexity of the surgery, alert about the high incidence of complications that can appear during surgery and record it by making an informed consent for the surgery.

6. References

- Barois A. Les problèmes respiratoires des scolioses graves. *Bull Acad Natl Med* 1999;183(4):721-730.
- Bradford DS, Kay BKB & Hu SS. Adult scoliosis: surgical indications, operative management, complications and aoutcomes. *Spine* 1999;24:2617-2629.
- Colomina MJ & Godet C. Anestesia para la cirugía de la escoliosis. Estudio preoperatorio y selección de pacientes de riesgo en la cirugía de las deformidades raquídeas. *Rev. Esp. Anesthesiol. Reanim.* 2005;52:24-43.
- Crowther MA, Webb PJ & Eyre-Brook IA. Superior mesenteric artery syndrome following surgery for scoliosis. *Spine* 2002;27(24):E528-533.
- Dubousset J, Schufflebarger HL & Herring JA. The crankshaft phenomenon. *J Pediatr Orthop* 1989; 9:541-550.

- Edwards CC, Bridwell KH, Patel A, Rinella AS, Berra A & Lenke LG. Long adult deformity fusions to L5 and the sacrum. A matched cohort analysis. *Spine* 2004;29:1996-2005.
- Gainé WJ, Andrew SM, Chadwick P, Cooke E, Williamson F & Bradley R. Late operative site pain with Isola posterior instrumentation requiring implant removal: infection or metal reaction. *Spine* 2001, 26:583-587.
- Galasko CSB, Delaney C & Morris P. Spinal stabilisation in Duchenne muscular dystrophy. *Journal of Bone and Joint Surgery, British Volume* 1992;74(2):210-211.
- Grivas TB, Dangas S, Polyzois BD & Samelis P. The double rib contour sign (DRCS) in lateral spinal radiographs: aetiologic implications for scoliosis. *Stud Health Inform.* 2002;88:38-43.
- Grivas TB, Vasiliadis ES, Mihas C, Triantafyllopoulos G & Kaspiris A. Trunk asymmetry in juveniles. *Scoliosis* 2008 Sep 23;3:13.
- Hawes M. Impact of spine surgery on sign and symptoms of spinal deformity. *Pediatric Rehabilitation* 2006;9(4):318-339.
- Hicks JM, Singla A, Shen FH & Arlet V. Complications of pedicle screw fixation in scoliosis surgery. A systematic review. *Spine* 2010;35(11):E465-E470.
- Hilibrand AS, Quartararo LG & Moulton MJ. 2004. Infecciones de la columna vertebral. In: *Orthopaedic Knowledge Update Spine Spanish Edition*, Kenneth J. Koval, 625-635, AAOS, B-50.672-2003. Spain.
- Koumbourlis AC. Scoliosis and the respiratory system. *Paediatr Respir Rev.* 2006 Jun;7(2):152-60.
- Laplaza FJ, Widmann RF, Fealy S, Moustafellos E, Illueca M & Burke S et al. Pancreatitis after surgery in adolescent idiopathic scoliosis: incidence and risk factors. *J Pediatr Orthop* 2002;22(1):80-83.
- Lonstein JE, Winter RB, Moe JH, Bradford DS, Chou SN & Pinto WC. Neurologic deficits secondary to spinal deformity . A review of the literature and report of 43 cases. *Spine* 1980;5(4):331-355.
- Molina A, Ramírez M, García-Casas O, Puig LL, Cáceres-Palou E, Gea J & Bagó J. New approaches to the surgical treatment of severe thoracic cage diseases with respiratory repercussions. *Arch Bronconeumol* 2003; 39:507-513.
- O'Leary PT, Bridwell KH, Lenke LG, Good CR, Pichelmann MA, Buchowski JM.; Kim YJ & Flynn J. Risk factors and outcomes for catastrophic failures at the top of long pedicle screw constructs. *Spine* 2009;34:2134-2139.
- Reames DL, Smith JS, Fu K-MG, Polly Jr DW, Ames CP, Berven SH, Perra JH, Glassman SD, McCarthy RE, Knapp Jr RD, Heary R, Shaffrey CI & Scoliosis Research Society Morbidity and Mortality Committee. Complications in the surgical treatment of 19,360 cases of pediatric scoliosis. *Spine* 2011;36(18):1484-1491.
- Rihn JA, Lee JY & Ward WT. Infection after the surgical treatment of adolescent idiopathic scoliosis. *Spine* 2008; 33(3):289-294.
- Smith JS, Shaffrey CI, Sansur CA, Berven SH, Fu K-MG, Broadstone PA, Choma TJ, Goytan MJ, Noordeen HH, Knapp Jr RD, Hart RA, Donaldson III WF, Polly Jr DW, Perra JH & Boachie-Adjei O. Rates of infection after spine surgery based on 108,419 procedures. A Report from the Scoliosis Research Society Morbidity and Mortality Committee. *Spine* 2011;36(7):556-563.
- Taylor BA & Webb PJ et al. Delayed postoperative paraplegia with hypotension in adult revision scoliosis surgery. *Spine* 19:470-474, 1994.


Tsirikos AI, Chang WN, Dabney KW, Miller F & Glutting J. Life expectancy in pediatric patients with cerebral palsy and neuromuscular scoliosis who underwent spinal fusion. *Dev Med Child Neurol.* 2003 Oct; 45(10):677-82.

Vauzelle C, Stagnara P & Jouvinroux P. Functional monitoring of spinal cord activity during spinal surgery. *Clin Orthop* 1973;93:173-78.

Weiss HR & Goodall D. Rate of complications in scoliosis surgery. A systematic review of the Pub Med literature. *Scoliosis* 2008,3:9.

IntechOpen

IntechOpen



Recent Advances in Scoliosis

Edited by Dr Theodoros Grivas

ISBN 978-953-51-0595-4

Hard cover, 344 pages

Publisher InTech

Published online 09, May, 2012

Published in print edition May, 2012

This book contains information on recent advances in aetiology and pathogenesis of idiopathic scoliosis, for the assessment of this condition before treatment and during the follow-up, making a note of emerging technology and analytical techniques like virtual anatomy by 3-D MRI/CT, quantitative MRI and Moire Topography. Some new trends in conservative treatment and the long term outcome and complications of surgical treatment are described. Issues like health related quality of life, psychological aspects of scoliosis treatment and the very important "patient's perspective" are also discussed. Finally two chapters tapping the untreated early onset scoliosis and the congenital kyphoscoliosis due to hemivertebra are included. It must be emphasized that knowledgeable authors with their contributions share their experience and enthusiasm with peers interested in scoliosis.

How to reference

In order to correctly reference this scholarly work, feel free to copy and paste the following:

Femenias Rossello Juan Miguel and Llabres Comamala Marcelino (2012). Complications in Scoliosis Surgery, Recent Advances in Scoliosis, Dr Theodoros Grivas (Ed.), ISBN: 978-953-51-0595-4, InTech, Available from: <http://www.intechopen.com/books/recent-advances-in-scoliosis/complications-in-scoliosis-surgery>

INTECH
open science | open minds

InTech Europe

University Campus STeP Ri
Slavka Krautzeka 83/A
51000 Rijeka, Croatia
Phone: +385 (51) 770 447
Fax: +385 (51) 686 166
www.intechopen.com

InTech China

Unit 405, Office Block, Hotel Equatorial Shanghai
No.65, Yan An Road (West), Shanghai, 200040, China
中国上海市延安西路65号上海国际贵都大饭店办公楼405单元
Phone: +86-21-62489820
Fax: +86-21-62489821

© 2012 The Author(s). Licensee IntechOpen. This is an open access article distributed under the terms of the [Creative Commons Attribution 3.0 License](#), which permits unrestricted use, distribution, and reproduction in any medium, provided the original work is properly cited.

IntechOpen

IntechOpen