



Pathological Study on Female Reproductive Affections in Dogs and Cats at Alexandria Province, Egypt

Maggie F.Tawfik, Samah S. Oda, Mahmoud S. El-Neweshy and El-Sayed M. El-Manakhly

Department of Pathology, Faculty of Veterinary Medicine, Alexandria University

Key words

Uterus, Ovary, Dogs, Cats, Histopathology, Egypt.

ABSTRACT:

Reproductive lesions are commonly seen in small animal practice. This study aimed to assess the reproductive disorders in bitches and queens. During the period from March 2013 to March 2015, 7 bitches and 28 queens of different breeds and ages (7 months up to 13 years) were collected from Alexandria Veterinary Medicine Directorate and Alifa Vet. Clinic, Alexandria, Egypt. They were examined clinically and by ultrasonography then ovariohysterectomy was performed for affected cases. Tissue specimens from uteri (n=35) and ovaries (n=20) were collected for both gross and histopathological examination. Results revealed that the most commonly recorded pathological conditions in the examined uteri were chronic endometritis (cats 67.85%, dogs 50%) followed by uterine neoplasms (cats 10.71%, dogs 37.5%), acute endometritis (cats 14.28%, dogs 12.5%) and disturbance in circulation (cats 7.14%). Cystic Ovaries was the most prevalent pathological conditions among the recorded ovarian lesions (cats 35.29%, dogs 50%) represented mainly by follicular cysts (cats 35.29%, dogs 16.66%), cystic corpus luteum (dogs 16.66%) and cystic rete ovarii (dogs 16.66%) followed by ovarian neoplasms (cats 35.29%) represented mainly by papillary cystadenoma (29.41%) and Granulosa theca cell tumor (5.88%) followed by persistent corpus luteum (cats 11.76%, dogs 50%), circulatory disturbance (cats 11.76%) and oophoritis (5.88%). In conclusion, the female reproductive disorders were significantly recorded in cats than in dogs. The uterine lesions were the most frequent estimated affections, than while the ovarian lesions were found the second. Mostly, animals with uterine lesions were associated with ovarian lesions particularly, cystic ovaries.

Corresponding Author: maggie foud tawfik (maggiéfouad@yahoo.com)

1. INTRODUCTION

Reproductive lesions are commonly seen in small animal practice. Lesions in the ovaries, uterus, and vagina may seriously influence normal reproductive capacity of dogs and cats and may put at risk the general health of the patients. Cystic lesions in the uteri of bitches and queens developed from the uterine serosa, myometrium or endometrium and include serosal inclusion cysts, adenomyosis, endometrial polyps, cystic remnants of mesonephric ducts and cysts associated with endometrial hyperplasia (Schlafer and Gifford, 2008).

Pyometra is the accumulation of purulent material in the uterus, secondary to bacterial infection. This condition is well described in domestic dogs and cats and is hormonally mediated, occurring during diestrus. Moreover, pyometra happens secondary to cystic endometrial hyperplasia, which is thought to result from chronic progesterone exposure. Cystic endometrial hyperplasia is followed by secondary

bacterial overgrowth of normal vaginal flora that enters the uterus during proestrus and estrus (Feldan, 2000). Bitches and queens with pyometra may present either with a vaginal discharge (open-cervix pyometra) or without a vaginal discharge (closed-cervix pyometra) (Schlafer and Gifford, 2008).

Endometrial polyps are focal tumour-like growths projecting into the uterine lumen and consisting of endometrial glands and connective tissue stroma (Kennedy et al., 1998). Animals with endometrial polyps are often asymptomatic, but can show mucopurulent or bloody vaginal discharge (Chambers et al., 2011). The uterine lumen may contain mucus or blood-tinged pus. If pyometra is present, the clinical signs may include abdominal distension, dehydration and anemia (Gumber et al., 2010). Endometrial polyps with a long pedicle can prolapse through the cervix into the vagina and may be visible during physical examination or by vaginoscopy (Lein, 1986).

Ovarian cysts have been reported to be common and their frequency increases with age (Johnston et al., 2001). In the bitch, follicular cysts, luteal cysts, germinal cysts, cystic corpora lutea, cystic rete ovarii, cystic atretic follicles, cystic granulosa cell tumours and cysts of the subsurface epithelial structures have been documented (Kennedy et al., 1998; Johnston et al., 2001). Follicular cysts that arise from mature or atretic follicles are reported to be the most common type; however, their etiology in spontaneous diseases is unknown (Johnston et al., 2001). In the veterinary literature, mostly follicular cysts have been studied probably due to the fact that these cysts secrete various amounts of hormone either causing overt clinical signs and/or oestrus irregularities (Johnston et al., 2001).

The present study aimed to assess the reproductive disorders in female dogs and cats at Alexandria province on the bases of the gross and histopathological findings.

2. MATERIAL AND METHODS

A total number of 35 animals (7 bitches and 28 queens). They were of different breeds. The examined bitches were 1-10 years old and queens 7months to 13 years old. The cases were admitted to Alexandria Veterinary Medicine Directorate and Alifa Vet. Clinic, Alexandria, Egypt. The study was done during the period from March 2013 to March 2015. Ultrasonographical examination was carried out and ovariohysterectomy was performed either for the purpose of spaying (n=4) or because of clinical signs indicative of pyometra as vaginal discharge and distension of the abdomen (n=30) or because of uterine prolapse (n=1). Some cats were treated earlier with progesterone derivates (Depo-Provera) for estrous suppression. The removed uterus (n=35) and ovaries (n=20) from bitches and queens were grossly examined and were collected and fixed in 10% buffered neutral buffered formalin solution for histopathology. Tissue specimens were processed as followings, dehydrated in ascending concentration of ethanol, cleared in xylene, embedded in paraffin wax and sectioned at 5 micron thickness. Prepared slides sections were stained by hematoxylin and eosin (Bancroft and Gamble, 2013).

3. RESULTS

The ultrasonographical examination revealed fluid filled organ with thickened uterine wall (Fig. 1). The detected histopathological findings in the

examined female reproductive organs were illustrated in dogs (Table 1) and in cats (Table 2).

3.1. Uterine lesions

3.1.1. Acute endometritis

It was detected in five animals [four cats (14.29%), one dog (12.5%)]. Macroscopically, three cats showed enlarged uterus with severely congested mucosa. Multifocal areas of petechial hemorrhages with thick mucoid turbid exudate on the endometrium were found. One case showed vulvar bloody discharge and on cross section, the uterus was inflamed and serosanguinous fluid was found inside the lumen. Microscopically, there were necrosis and desquamation of the lining epithelium of endometrium (Fig. 2) with degeneration of the endometrial glandular epithelium. Congestion of the endometrial blood vessels with multiple areas of hemorrhages was noticed. Golden yellow to brown granules were deposited interstitially indicative of tissue hemosiderosis. Moreover, there were numerous neutrophils in the interstitium and to lesser extent mononuclear cell infiltrates. Edema in the endometrial mucosa and submucosa was noticed. Moreover, myometrium was congested and hypertrophied.

3.1.2. Chronic endometritis

It was detected in 23 cases [19 cats (67.85%), four dogs (50%)] and it was accompanied by:

Cystic endometrial hyperplasia

Seven cats (25%) and three dogs (37.5%) had chronic endometritis that accompanied by cystic endometrial hyperplasia. Macroscopically, the affected cases showed cysts of varying size in the endometrium which had irregular thickened wall (Fig. 3). Yellowish to greenish sticky material or serosanguinous fluid was found in the uterine lumina. Three cases showed creamy to bloody pus vulvar discharge. Microscopically, there was cystic dilatation of some endometrial glands as they increased in the size and number (Fig. 4). Endometrial glands were lined by cuboidal or flattened epithelial cells. Lumina of some endometrial glands contained necrotic debris (Fig. 5). Mononuclear inflammatory cell infiltrates were found in the endometrial stroma mainly lymphocytes, plasma cells and macrophages. Endometrial fibrosis was detected; particularly around the endometrial glands. Mild to severe congestion of both the endometrium and myometrium was found. In

one bitch, some endometrial glands showed papillary cystic adenocarcinoma.

Endometrial Polyps

Five cats (17.85%) and one dog (12.5%) showed chronic endometritis associated with endometrial polyps. Macroscopically, the endometrium was thickened and corrugated with cream-like pus in the lumen of the uterus. On cross section, the uterus was segmented with pedunculated growths protruding into the uterine lumen. One case showed blood discharge through the vulva. Microscopically, there were multiple polypoid-like projections with diffuse thickening of the endometrial mucosa (Fig. 6). These projections contained ectatic and hyperplastic endometrial glands within a connective tissue stroma. The lining epithelial cells varied from columnar to squamous. Chronic inflammatory cells infiltration mainly lymphocytes, plasma cells and macrophages in the endometrial stroma and in some polyps were detected. Moreover, necrotic debris was seen inside the lumina of some glands.

Pyometra

Macroscopically, seven cats (25%) showed greatly distended uterus (Fig. 7) with large amount of thick creamy whitish, greenish or even bloody pus. Uterine mucosa was thickened and congested. One case showed vulvar bloody discharge. Microscopically, there were moderate to large infiltration of the endometrium and to lesser extent the myometrium by neutrophils, lymphocytes, plasma cells and macrophages. Necrosis of the endometrial mucosal epithelium, congestion and extensive hemorrhage were evident. Uterine lumina contained purulent exudates (Fig. 8). In addition, there was hyperplasia of the endometrial epithelium producing papillary proliferation. Some endometrial glands were cystically dilated and lined by flattened epithelium and contained eosinophilic homogenous structureless material. Hypertrophy of myometrium was observed.

3.1.3. Circulatory disturbances

Macroscopically, uterus of two cats (7.14%) showed severely congested mucosa. Microscopically, there were severe congestion and multiple areas of extravasated erythrocytes in the endometrium and myometrium. Focal areas of hemosidrosis were evident.

3.1.4. Tumors

Fibroadenoma

Macroscopically, the uterus of one cat (3.57%) had a tumor mass of apple size. The tumor appeared pale to white mass, pedunculated, firm and encapsulated with reddish area. Microscopically, the mass consisted of proliferating fibroepithelial tissue, including well-differentiated ducts surrounded by whorls and interlacing bundles of abundant loose fibrovascular stroma (Fig. 9). The ductal epithelium was composed of single or double layer of well-differentiated cuboidal to columnar epithelial cells. Some ductal structures showed cystic dilatation and papillary projections that protruded into the lumen.

Papillary cystadenocarcinoma

Two cats (7.14%) and three dogs (37.5%) exhibited papillary cystadenocarcinoma. Macroscopically, uterus of three cases contained multiple rounded swelling small hen egg size filled with blood. The lumen of the uterus filled with large amount of thick creamy purulent exudate. Microscopically, there were thickened endometrium with cystic and papillary projections into the lumen and irregular shaped dilated endometrial gland lined by two or multiple layers of columnar neoplastic cells which had abundant cytoplasm and large vesicular or hyperchromatic nuclei with mitotic figures (Fig. 10). Some neoplastic cell showed squamous metaplasia. Multiple solid masses resulting from infiltration of neoplastic cells in abundant connective tissue stroma were observed. Moreover, accumulation of homogenous eosinophilic secretion in lumens of some dilated cysts. Also, there were necrosis of the endometrial lining epithelium, congestion of the endometrial blood vessels and multifocal areas of extravasated erythrocytes infiltrated that were associated with focal areas of hemosidrosis.

3.2. Ovarian lesions

3.2.1. Circulatory disturbance

Macroscopically and microscopically, two cats (11.76%) showed mild to severe congested ovary.

3.2.2. Persistent corpus luteum

Macroscopically, two cats (11.76%) and three dogs (50%) showed only congested ovary. Microscopically, it was identical to that of a normally functioning corpus luteum. Granulosa lutein cells derived from the granulosa cell layer are larger and

less darkly stained than the theca lutein cells. Mild to severe congestion was observed.

3.2.3.Ovarian cysts

Follicular cysts

Macroscopically, six cats (35.29 %) one dog (16.66%) showed multiple cysts of variable size on the ovary. Their walls were thin with presence of clear serous fluid. Microscopically, there were multiple cysts of variable size. Their cavities contained homogenous eosinophilic fluid (Fig. 11). Most of these cysts have thin wall and lined by a layer of cuboidal or flattened cells. Some of these cysts especially larger ones resulted in pressure atrophy of the adjacent ovarian tissues. Mild to severe congestion was seen.

Cystic rete ovarii

Macroscopically, one dog (16.66%) showed visible cysts on ovary with congested wall. Microscopically, cysts were within the ovary and at the tubal extremity of the ovary (Fig. 12). The cyst was lined by single cuboidal to flattened layer of epithelium, ciliated and nonciliated. As cystic distention of the rete tubules increased, the cortex of the ovary became compressed. Congestion was present.

Cystic corpus luteum

Macroscopically, one dog (16.66%) had congested ovary with presence of single cyst on the ovary. Microscopically, the cyst had an irregular wall that lined by few layers of granulosa lutein cells (Fig. 13). Homogenous eosinophilic fluid was seen in the center of the corpus luteum. Severe congestion was observed.

3.2.4. Oophoritis

Macroscopically, one cat (5.88%) showed congested ovaries with single cyst contained free blood with thick wall. Microscopically, there was severe congestion. Some follicles contained eosinophilic fluid with infiltration of numerous neutrophils and moderate number of mononuclear cells. Tissue hemosiderosis was evident. The stroma aggravated the same lesion.

3.2.5.Tumors

Papillary cystadenoma

Macroscopically, five cats (29.41%) ovaries had cauliflower-like masses and multiple thin walled cysts contain clear watery fluid. Dark red spots were seen on the ovarian surface. Microscopically, there were papillary projections and cysts were lined by single layer of cuboidal or flattened cells (Fig. 14). The stroma was sparse and consisted of a vascular frame work. Severe congestion was observed.

Granulosa theca cell tumor

Macroscopically, one cat (5.88%) ovary was cystic with white solid areas and hemorrhage. Microscopically, the tumor was consisted of cystic and solid areas. The neoplastic cells were polyhedral with foamy cytoplasm and round hyperchromatic nucleus resemble normal granulosa cells. These cells were arranged in diffuse sheets surrounding varying sized cystic spaces with clear fluid. A pathognomonic call-exner bodies consisting of a small central round, to oval space with eosinophilic follicular fluid surrounded by a collar of radially arranged granulosa cells were observed (Fig. 15).

Table (1): Histopathological findings of female reproductive organs in dogs

Uterine lesions	No. of lesions	% of lesions	Species	Age	Associated Ovarianlesions	No. of lesions	% of lesions
1.Acute Endometritis	1	12.5	Griffon	10y	Follicular cysts cystic rete ovarii persistent corpus luteum	1 1	16.66 16.66 16.66
2.Chronic Endometritis	4	50					
a- Cystic Endometrial Hyperplasia	3	37.5	Yorkshire terrier Pekingese	4-5y 1y	Cystic corpus luteum	1	16.66
b-Endometrial Polyps	1	12.5	Bichon	12y			

3. Papillary cystadenocarcinoma	3	37.5	Pekingese Griffon	1-7y 5y	Persistent corpus luteum	2	33.33
Total lesions	8					6	

Table (2): Histopathological findings of female reproductive organs in cats

Uterine lesions	No. of lesions	% of lesion	Species	Age	Associated Ovarian lesions	No. of lesions	% of lesions
1.Acute Endometritis	4	14.29	Persian Native- breed Turkish angora	1.5-13y 1y unknown	Follicular cysts	1	5.88
2.Chronic Endometritis	19	67.85					
a- Cystic Endometrial Hyperplasia	7	25	Persian Native-breed Siamese	1-2y 7y 13y	Papillary cystadenoma Persistent corpus luteum Follicular cysts Granulosa cell tumor	1 1 2 1	5.88 5.88 11.76 5.88
b-Endometrial Polyps	5	17.85	Persian Mixed-breed	2-4y 5-6y	Follicular cysts Persistent corpus luteum	2 1	11.76 5.88
c-Pyometra	7	25	Persian Siamese Mixed-breed	7m-5y 8y 7y	Oophoritis Circulatory disturbance Papillary cystadenoma	1 1 3	5.88 5.88 17.64
3.Disturbance in circulation	2	7.14	Turkish angora Mixed-breed	3y 4y	Circulatory disturbance Papillary cystadenoma	1 1	5.88 5.88
4.Tumors	3	10.71					
a-Fibroadenoma	1	3.57	Persian	11y			
b-Papillary cystadenocarcinoma	2	7.14	Native-breed Persian	8y 2y			
Total lesions	28					17	

4. DISCUSSION

Reproductive disorders in pet animal are rapidly becoming a major part of the veterinary care. The present study indicated that the uterine affections were the most frequent estimated affections, while the ovarian lesions were found the second. The most common recorded pathological conditions in the examined uteri were chronic endometritis (cats 67.85%, dogs 50%) followed by uterine neoplasms (cats 10.71%, dogs 37.5%), acute endometritis (cats 14.28%, dogs 12.5%) and disturbance in circulation (cats 7.14%). Almost all uterine infections began as endometritis. Mild cases of acute endometritis were not detected grossly. Microscopically, a few or many neutrophils were in the stroma and in the glands, with epithelial changes varied from mild to severe necrosis of the endometrium.

Mild lesions resolved completely or incompletely with residual changes of cystic glands and periglandular fibrosis (Helen, 2001). In chronic endometritis, polypoid represented (cats 17.85%, dogs 12.5%) while cystic (cats 25%, dogs 37.5%).

There was infiltration of lymphocytes, plasma cells and macrophages. There were polypoid-like projections with thickening of the mucosa. This was diagnosed as chronic polypoid endometritis. There was cystic dilatation of endometrial glands as they

increased in the size and number. This condition was diagnosed as chronic cystic endometritis. These results were parallel with those of Rama, (2011). Pyometra represented (cats 25%) among the examined uteri. It occurs after estrogen stimulation followed by prolonged progesterone dominance.

Progesterone-primed conditions influence hyperplasia of the endometrium and endometrial glands, decrease myometrial contractions, and inhibit the local leukocyte response to infection, which allows for bacterial proliferation within the uterine lumen. Moreover, ovarian cystic fluid also contains estradiol, which enhances the number of estrogen and progesterone receptors in the endometrium that activated the endometrium gland to secrete endometrium fluid. Additionally, during the early luteal phase, the increased progesterone concentration suppresses cellular immunity (Sugiura et al., 2004).

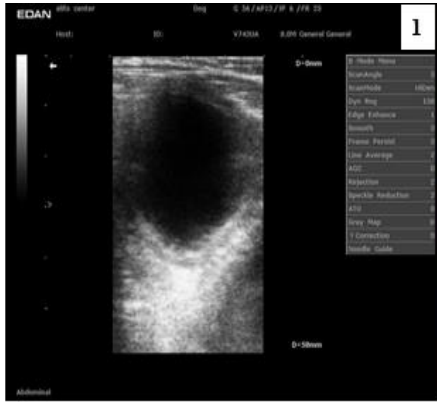

Fig.1. A sonographic view of uterus of Grifflon dog 10-years old showing: Hypoechoic and thickened uterine wall. The luminal content was homogenous and filled with anechoic fluid.

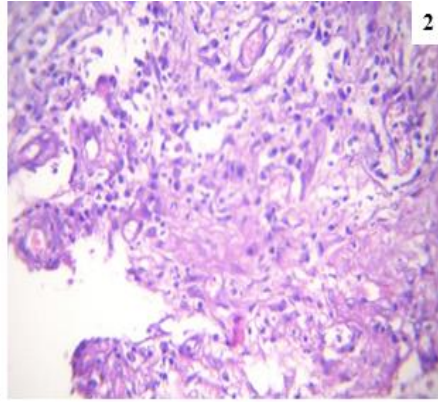


Fig. 2. A uterus of a Persian cat 13- years old with acute endometritis showing: Endometrial epithelial necrosis. H&E. X400.

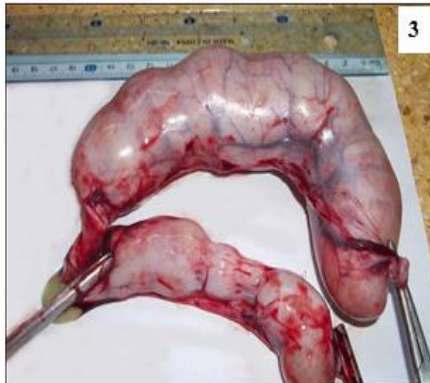

Fig. 3. A uterus of a Persian cat two-years old showing: Cystic Endometrial Hyperplasia. Thickened irregular uterine wall. homogenous and filled with anechoic fluid.

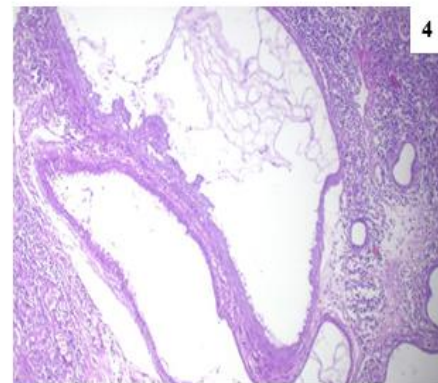


Fig. 4. A uterus of Pekingese dog one-years old showing: Cystic dilatation of endometrial gland that lined by flattened or cuboidal cells with homogenous eosinophilic fluid in their lumina, H&E. X100.

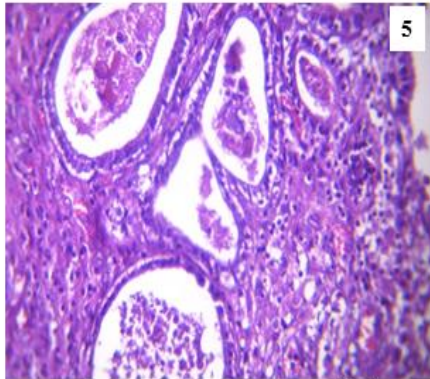


Fig. 5. A uterus of a Persian cat two-years old showing: Cystic Endometrial Hyperplasia. Necrotic debris Inside the lumina of endometrial glands. H&E. X400.

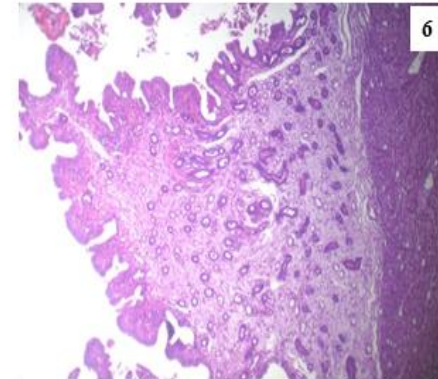


Fig. 6. A uterus of Bichon dog 12-years old with endometrial Polyps showing: Polypoid-like projections with diffuse thickening of the endometrial mucosa. H&E. X100..

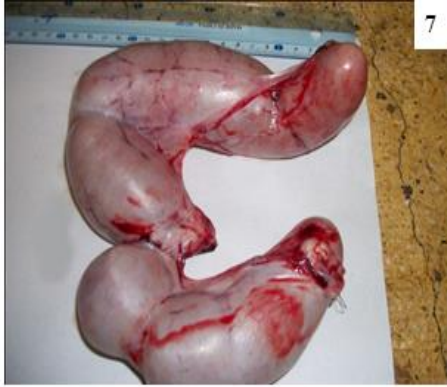

Fig. 7. A uterus of a Persian cat seven-months showing: Great distension of uterus with pus..

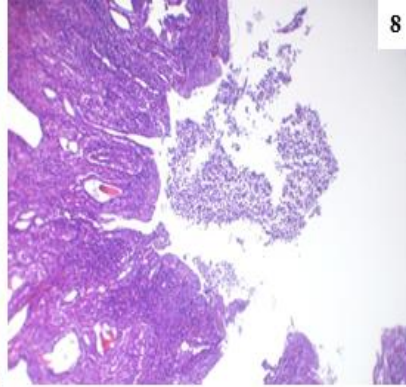


Fig. 8. A uterus of Persian cat three-years old with pyometra showing: Presence of purulent exudates in the uterine lumen (asterisk) with endometrial hyperplasia. H&E. X100..

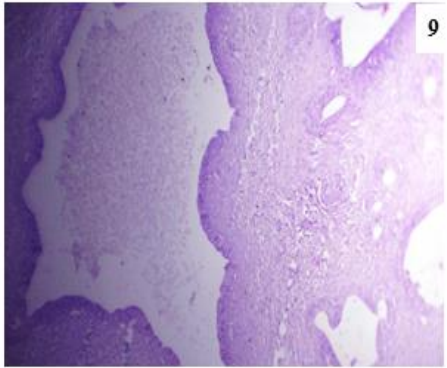


Fig. 9. A uterus of a Persian cat 11-years old with fibroadenoma showing: Well-differentiated ducts (A) surrounded by interlacing bundles of fibrovascular stroma (asterisk). H&E. X100..

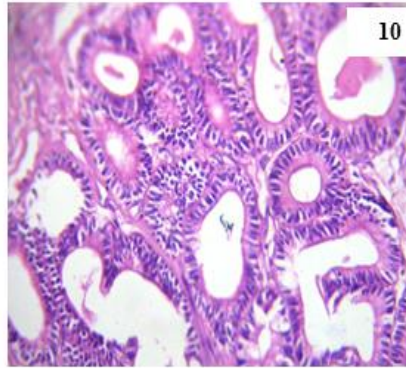


Fig. 10. A uterus of Pekingese dog seven-years old showing: Papillary cystic adenocarcinoma. H&E. X400..

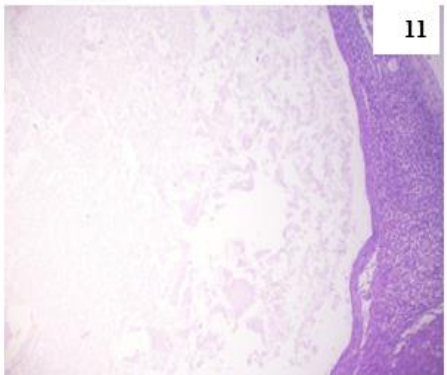


Fig. 11. An ovary of a Persian cat two-years old showing: Follicular cyst with homogenous eosinophilic fluid. H&E. X100..

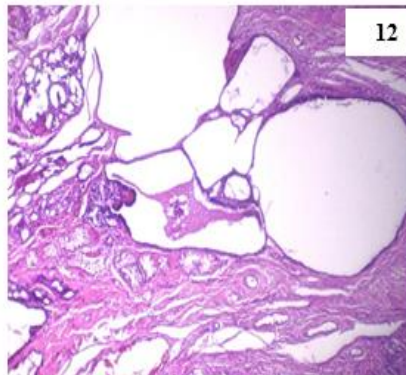


Fig. 12. An ovary of Griffon dog 10-years old showing: Cystic rete ovarii. Presence of multiple cysts that lined by single layer of flattened or cuboidal cells. H&E. X100..

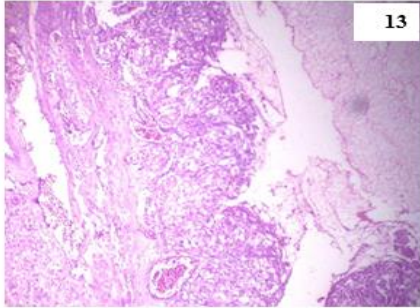


Fig. 13. An ovary of Yorkshire terrier dog four-years old showing: Cystic corpus luteum. Thickened irregular wall that lined by few layers of granulosa lutein cells (arrows) with homogenous eosinophilic fluid inside the lumen (asterisk). H&E. X100.

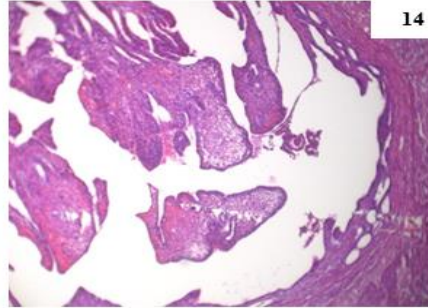


Fig. 14. An ovary of a Persian cat three-years old showing: Papillary cystadenoma. Papillar projections lined by single layer of flattened or cuboidal cells. H&E. X100.

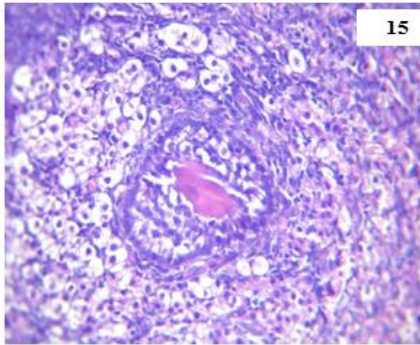


Fig.15. An ovary of Native-breed cat seven-years showing: Granulosa cell tumor. A pathognomonic Call-Exner body (arrow). H&E. X400.

Clinical signs of pyometra appeared in one case after mated by 10 days. Smith, (2006) explained that estradiol causes cervical dilation during estrous, and therefore allows bacteria that are part of the normal flora of the vagina (especially *E. coli* and *Streptococcus spp.*) to ascend into the uterus. The combination of reduced local immunity and favorable uterine conditions for these pathogens allow for bacterial colonization and proliferation. Recently, it was reported that inoculation of *E. coli* into the uterus on days 11 to 20 and 20 to 30 after the luteinizing hormone peak caused canine pyometra, because at that time the uterus is most susceptible to infection. Endometrial hyperplasia is the result of cystic deformation of endometrial glands and stromal proliferation of fibroblasts with inflammatory reaction (De Bosschere et al., 2001). Although uterine tumors are rare in the dog and cat, uterine neoplasms [Fibroadenoma (cats 3.57 %), papillary cystadenocarcinoma (cats 7.14%, dogs 37.5%)] represented a considerable incidence among uterine lesions in our study. However, Joanna and Jane, (2001) reported that endometrial carcinoma/adenocarcinoma is more common in the cat than the dog. Tumors arise from the endometrial

glands, often filling the uterine lumen and expanding outwards through the uterine wall. Histologically, neoplastic cells may be multinucleated and invade the myometrium singly, in cords or in glandular formation as well as squamous metaplasia may occur. Cystic Ovaries was the most prevalent pathological conditions among the recorded ovarian lesions (cats 35.29%, dogs 50%) represented mainly by follicular cysts (cats 35.29%, dogs 16.66%), cystic corpus luteum (dogs 16.66%) and cystic rete ovarii (dogs 16.66%) followed by ovarian neoplasms (cats 35.29%) represented mainly by papillary cystadenoma (29.41%) and Granulosa theca cell tumor (5.88%) followed by persistent corpus luteum (cats 11.76%, dogs 50%), circulatory disturbance (cats 11.76%) and oophoritis (5.88%). The excess secretion of estrogens by ovarian cysts or by tumor cells frequently lead to shortened interestrous intervals with prolonged heats, and often even to persistent estrus. The secretion of high quantity of estrogens may act on the uterus as a potential factor towards the cystic endometrial hyperplasia – pyometra complex (Fontbonne, 2011). Follicular cysts are thin-walled structures containing clear, serous fluid. Follicular cysts may be single or multiple; if multiple cysts are present in one ovary,

the cysts do not communicate (Johnston et al., 2001). The treatment of choice of ovarian follicular cysts is ovariectomy or ovariohysterectomy when the uterus is damaged (Wright and Watts, 1998). Granulosa Cells tumors represent 23 to 52 % of the ovarian tumors (Johnston et al., 2001). They occur mainly in bitches in the second part of life, with a mean age of diagnosis of 7.2 years. These tumors are mainly unilateral, but bilateral cases have been published (Fontbonne, 2011).

In conclusion, the female reproductive disorders were significantly recorded in cats than in dogs. The uterine lesions were the most frequent estimated affections, than while the ovarian lesions were found the second. Mostly, animals with uterine lesions were associated with ovarian lesions particularly, cystic ovaries.

5. REFERENCES

- Bancroft, J.D., Gamble, M. 2013. Theory and practice of histological techniques. 7th ed. Churchill Livingstone, Edinburgh, London, Melbourne and New York; 2013, p. 252.
- Chambers, B.A., Laksito, M.A., Long, F., Yates, G.D. 2011. Unilateral uterine torsion secondary to an inflammatory endometrial polyp in the bitch. *Aust. Vet. J.* 89: 380-384.
- De-Bosschere, H., Ducatelle, R., Vermeirsch, H., Van-Den, Broeck, W., Coryn, M. 2001. Cystic endometrial hyperplasia-pyometra complex in the bitch: Should the two entities disconnected? *Theriogenology.* 55: 1509–1519.
- Feldman, E. C. The cystic endometrial hyperplasia/pyometra complex and infertility in female dogs. In: Ettinger SJ, Feldman EC, editors. *Textbook of Veterinary Internal Medicine: Diseases of the Dog and Cat.* 5th ed. WB Saunders Company, Philadelphia, Pennsylvania; 2000, p.1549–1555.
- Fontbonne. 2011. Infertility in bitches and queens: recent advances. *Rev. Bras. Reprod. Anim. Belo Horizonte.* 35:202-209.
- Gumber, S., Springer, N., Wakamatsu, N. 2010. Uterine endometrial polyp with severe hemorrhage and cystic endometrial hyperplasia-pyometra complex in a dog. *J. Vet. Diagn. Invest.* 22: 455-458.
- Helen MA. 2001 The female reproductive system. In: McGavin MD, Carlton W, Zachary JF, editors. *Thomson's Special Veterinary Pathology.* 3rd ed. Mosby; 2001, p. 605-610.
- Joanna, M., Jane, D. Genital Tract. 2001. In: *Small animal oncology;* , p.169-170.
- Johnston SD, Kustritz MV, Olson PN. *Canine and Feline Theriogenology.* 1st ed. WB Saunders Company, Philadelphia; 2001.
- Kennedy, P.C., Cullen, J.M., Edwards, J.F., Goldschmidt, M.H., Larsen, S. 1998. *Histological Classification of Tumors of the Genital System of Domestic Animals.* Second Series Vol. IV, Armed Forces Institute of Pathology and World Health Organization, Washington DC. p. 34-35.
- Lein HD. Infertility and reproductive diseases in bitches and queens. In: Roberts SJ, editors. *Veterinary Obstetrics and Genital Diseases (Theriogenology),* Woodstock; 1986, p. 740-741.
- Rama R. The reproductive system. In: Ganti AS, editors. *Veterinary pathology.* 7th ed, College of veterinary science, Tirupati; 2011, p.434-435.
- Schlafer, D.H., Gifford, A.T. 2008. Cystic endometrial hyperplasia, pseudo-placentational endometrial hyperplasia and other cystic conditions of the canine and feline uterus. *Theriogenology.* 70: 349-358.
- Smith, F.O. 2006. Canine pyometra. *Theriogenology.* 66: 610–612.
- Sugiura, K., Nishikawa, M., Ishiguro, K., Tajima, T., Inaba, M., Torii, R., Hatoya, S., Wijewardana, V., Kumagai, D., Tamada, H., Sawada, T., Ikehara, S., Inaba, T. 2004. Effect of ovarian hormones on periodical changes in immune resistance associated with estrous cycle in the beagle bitch. *Immunobiology.* 209: 619–927.
- Wright P, Watts JR. The infertile female. In: *BSAVA Manual of Small Animal Reproduction and Neonatology,* England and Harvey: B