

Pseudomonas aeruginosa Community Acquired Pneumonia with Septicemia in a Previously Healthy Woman

Yoshiro Imai, Ryo Iida, Masahiko Nitta, Akira Takasu

Department of Emergency Medicine, Osaka Medical College, Osaka, Japan

Email: sur141@osaka-med.ac.jp

How to cite this paper: Imai, Y., Iida, R., Nitta, M. and Takasu, A. (2016) *Pseudomonas aeruginosa* Community Acquired Pneumonia with Septicemia in a Previously Healthy Woman. *Case Reports in Clinical Medicine*, 5, 335-341.

<http://dx.doi.org/10.4236/crcm.2016.59051>

Received: August 11, 2016

Accepted: September 26, 2016

Published: September 29, 2016

Copyright © 2016 by authors and Scientific Research Publishing Inc. This work is licensed under the Creative Commons Attribution International License (CC BY 4.0).

<http://creativecommons.org/licenses/by/4.0/>



Open Access

Abstract

A previously healthy 53-year-old woman was urgently hospitalized due to septic shock. She was diagnosed with bacterial pneumonia based on chest radiograph and computed tomography findings of right upper lobe consolidation. Sputum Gram-stain at the time of admission showed gram-negative rods with phagocytosis. Intravenous meropenem was immediately initiated as empiric antibacterial therapy. Bacterial culture specimens from sputum and blood were positive for *Pseudomonas aeruginosa*. Following appropriate antibiotic therapies, the patient recovered from a shock state and gradually became well. There has been no evidence of recurrence at 6 months after discharge. *P. aeruginosa* community acquired pneumonia with septicemia is rapidly progressive and often fatal. The choice of initial empiric antibiotic treatment that is active against *P. aeruginosa* is critical in improving outcome.

Keywords

Pseudomonas aeruginosa, Community Acquired Pneumonia, Septicemia

1. Introduction

P. aeruginosa is a frequent pathogen causing hospital-acquired pneumonia and health-care-associated pneumonia, but is a rare cause of Community Acquired Pneumonia (CAP) in an immune competent host [1]. However, *P. aeruginosa* CAP is prone to develop septicemia, is often rapidly progressive, and may be fatal [2]. Appropriate initial empiric antibiotic treatment is crucial in improving outcomes. We herein report a case of *P. aeruginosa* CAP with septicemia in a previously healthy woman who was success-

fully treated by appropriate antibiotic treatment.

2. Case Report

A 53-year-old woman was brought by ambulance to the emergency department of our hospital due to fever and right shoulder pain for a few hours. She had no pertinent past medical history, family history, or recent history of overseas travel. However, she had been a smoker of 20 cigarettes per day for 30 years. On examination, her body temperature was 36.3°C, blood pressure was 90/40 mmHg, pulse rate was 100 beats/min, respiratory rate was 22 breaths/min, and oxygen saturation was 97% at an oxygen support of 10 L/min by face mask. Auscultation of the chest revealed coarse crackles on the right upper lobe. Initial laboratory tests revealed white blood cell (WBC) count of 6740 cells/ μ L, and elevations of C-reactive protein (CRP; 2.94 mg/dl), procalcitonin (PCT; 37.73 ng/ml). And arterial blood gas revealed lactic acidosis (pH; 7.363, base excess; -0.5 mmol/L, lactate; 22.6 mg/dl). Chest radiograph showed right upper lobe consolidation and computed tomography (CT) scan showed air space consolidation in the posterior segment of the right upper lobe (Figure 1).

Figure 2 summarizes her clinical course in the hospital. She was diagnosed as septic shock due to lobar pneumonia. Treatment with bolus infusion of lactated Ringer's solution and norepinephrine (0.3 μ g/kg/min) was started at the emergency room. She did not require emergency intubation, but she was transferred to the intensive care unit. Sputum Gramstain on admission showed Gram-negative rods with phagocytosis. At the emergency room, empiric antibiotic treatment with intravenous meropenem (MEPM) at 3 g/day was immediately started. The results of blood and sputum cultures were positive for *P. aeruginosa*. An acid-fast stain of the sputum was negative. After the 4th day of hospitalization, cardiovascular stabilization was achieved and norepinephrine drip was discontinued. Subsequently, her clinical symptoms and the level of CRP improved and her body temperature normalized. On the 7th day of hospitalization, antibiotic treatment was de-escalated to intravenous ciprofloxacin (CPFEX) at 0.6 g/day.

A repeat chest CT scan on the 11th hospital day showed reduction of air space consolidation, but anew cavity formation was observed (Figure 3). Although not detected in any of the specimens, co-infection with an anaerobe was suspected and intravenous clindamycin (CLDM) at 2.4 g/day was added and continued for 10 days. Follow-up chest radiograph and CT scan on the 24th hospital day revealed further improvement of the consolidation and resolution of the cavity (Figure 4). Intravenous CPFEX was continued until discharge on the 28th hospital day and oral CPFEX was prescribed for one more week after discharge. Six months after discharge, there were no clinical symptoms of recurrence and follow-up chest radiograph revealed resolution of the infiltrates (Figure 5).

3. Discussion

P. aeruginosa is a frequent pathogen causing hospital-acquired pneumonia and health-care-associated pneumonia [1] [3]. However, CAP secondary to *P. aeruginosa* is un-

common, with an incidence of only 0.6%, as shown in Sibila's cohort study on 62,689 pneumonia patients aged ≥ 65 years old [4]. It is often rapidly progressive and may be fatal [4], with a 30-day mortality rate of 17.4% [4].

There have been only 12 case reports found in PubMed on *P. aeruginosa* CAP with septicemia in patients without comorbidities (Table 1) [3] [5]-[13]. The clinical characteristics of these cases were pleuritic chest pain and right upper lobe predilection; in addition, mortality rate was high. The outcome was shown to be dependent on initiation of appropriate antibiotic therapy against *P. aeruginosa* within the first 48 hours of

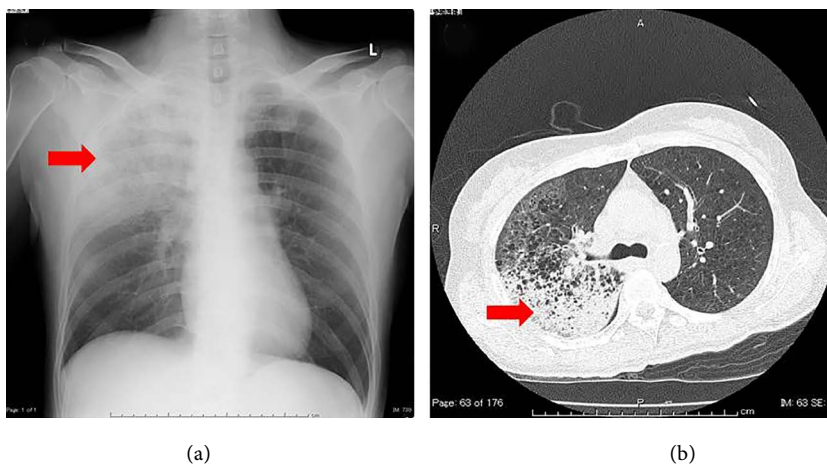


Figure 1. Chest radiograph and computed tomography (CT) scan of the chest. (a) Chest radiograph obtained at the emergency room shows right upper lobe consolidation (red arrow); (b) CT scan of the chest showed air space consolidation in the posterior segment of the right upper lobe (red arrow).

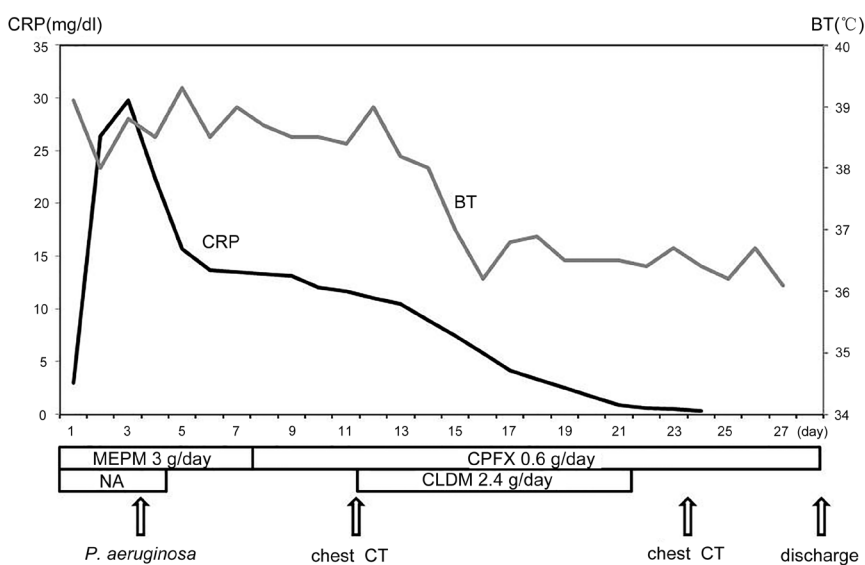


Figure 2. Course of treatment. The level of C-reactive protein (CRP) improved and her body temperature normalized. MEPM: meropenem, CPFX: ciprofloxacin, CLDM: clindamycin, NA: norepinephrine.

admission [14], therefore, timely appropriate empiric antibiotic treatment is crucial [14]. For this patient, we chose MEPM because the main target of treatment was septicemia due to lobar pneumonia and based on the presence of gram-negative rods on sputum. Gramstain is the most commonly performed microbiology test that can immediately identify the cause of a bacterial infection. Henderson *et al.* [10] suggest that *P. aeruginosa* CAP should be suspected in any patient who has gram-negative bacilli seen on sputum sample. Gram-negative bacteria include *P. aeruginosa*, which is reported to be one of the risk factors for death in CAP patients [15].

P. aeruginosa CAP may sometimes progressive to cavitary pneumonia [2] [3] or lung abscess; for the latter, anaerobes are the major pathogens involved and may co-infect

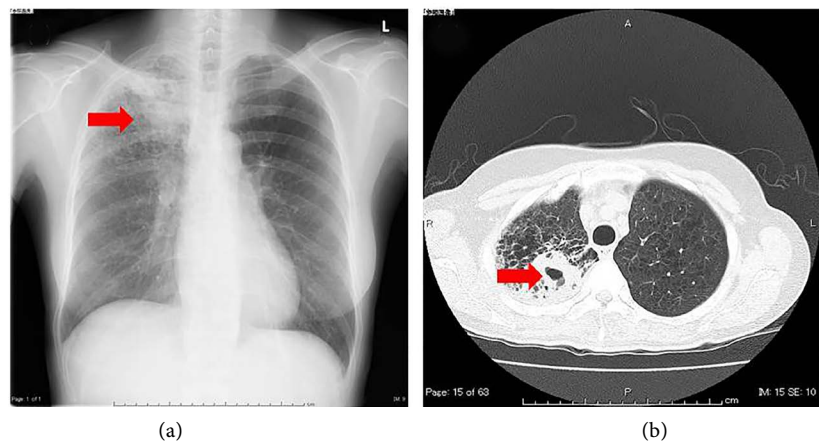


Figure 3. Follow-up chest radiograph and CT scan of the chest. (a) Follow-up chest radiograph on the 15th day of hospitalization shows improvement of the right upper lobe consolidation (red arrow); (b) Follow-up CT scan of the chest on the 15th day of hospitalization showed improvement of air space consolidation, but a new cavity on the right upper lobe (red arrow).

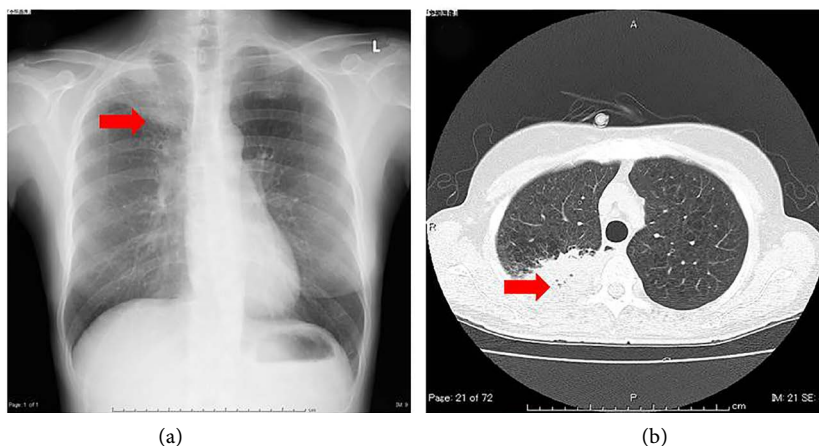


Figure 4. Follow-up chest radiograph and CT scan of the chest. (a) Follow-up chest radiograph on the 24th day of hospitalization shows further improvement of the right upper lobe consolidation (red arrow); (b) Follow-up CT scan of the chest on the 24th day of hospitalization showed stability of the air space consolidation, but resolution of the cavitation (red arrow).

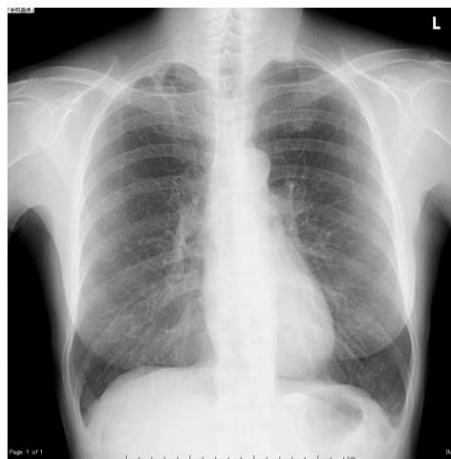

Figure 5. Follow-up chest radiograph. Follow-up chest radiograph 6 months after discharge revealed almost complete resolution of the infiltrates.

Table 1. Laboratory findings in a previously healthy woman who developed *Pseudomonas aeruginosa* pneumonia CRP: C-reactive protein, PCT: procalcitonin.

Reference	Age	Sex	Symptom	Infected location	Treatment	Outcome
Fujii [3]	29	Male	Shoulder pain	Right upper lobe	PIPC	Recovered
Quirk [5]	40	Female	Unknown	Unknown	PC, EM (2d); PIPC, GM, PC, CPFX, CAZ	Recovered
Harris [6]	39	Male	Chest pain	Left lower lobe	ABPC, GM, CLDM, CBPC, GM	Recovered
Govan [7]	49	Male	Unknown	Unknown	PC, ABPC, MC	Death
Hoogwrf [8]	64	Male	Lost consciousness	Right upper lobe	ABPC, GM (3d); CBPC, GM	Recovered
Fishman [9]	29	Male	Unknown	Unknown	GM, EM, CET (3d); CBPC, GM	Recovered
Henderson [10]	52	Male	Cough	Left lower and right upper lobe	GM, ABPC, EM, MFIPC	Death
Henderson [10]	27	Female	Cough	Right upper lobe	PC, GM, EM	Death
Ishihara [11]	48	Female	Back pain	Right upper lobe	PIPC	Recovered
Okamoto [12]	39	Female	Chest pain	Right upper lobe	CTRX (12h); CPFX, MEPM (10d); TAZ/PIPC, AMK	Recovered
Takakura [13]	52	Male	Chest and back pain	Right upper lobe	PAPM/BP, CPFX	Death
Takakura [13]	73	Male	Chest pain	Right upper lobe	TAZ/PIPC, LVFX	Death

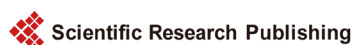the pneumonia [3]. In this case, although anaerobes were not detected in blood and sputum, cavitory pneumonia was seen on follow-up CT scan. Co-infection with anaerobes might have been associated with this disease. In such cases, combination therapy with antibiotics against both *P. aeruginosa* and anaerobes might contribute to resolution of the cavitory pneumonia [3].

We experienced a rare case of *P. aeruginosa* CAP with septicemia in a previously healthy woman. The clinical course might be rapidly progressive and is often fatal. The choice of an initial empiric antibiotic treatment that is active against *P. aeruginosa* is critical in improving outcome.

References

- [1] Mandell, L.A., Wunderink, R.G., Anzueto, A., Bartlett, J.G., Campbell, G.D., Dean, N.C., Dowell, S.F., File Jr., T.M., Musher, D.M., Niederman, M.S., Torres, A. and Whitney, C.G. (2007) Infectious Diseases Society of America/American Thoracic Society Consensus Guidelines on the Management of Community Acquired Pneumonia in Adults. *Clinical Infectious Diseases*, **44**, S27-S72. <http://dx.doi.org/10.1086/511159>
- [2] Hatchette, T.F., Gupta, R. and Marrie, T.J. (2000) *Pseudomonas aeruginosa* Community-Acquired Pneumonia in Previously Healthy Adults: Case Report and Review of Literature. *Clinical Infectious Diseases*, **31**, 1349-1356. <http://dx.doi.org/10.1086/317486>
- [3] Fujii, A., Seki, M., Higashiguchi, M., Tachibana, I., Kumanogoh, A. and Tomono, K. (2014) Community-Acquired, Hospital-Acquired, and Healthcare-Associated Pneumonia Caused by *Pseudomonas aeruginosa*. *Respiratory Medicine Case Reports*, **12**, 30-33. <http://dx.doi.org/10.1016/j.rmcr.2014.03.002>
- [4] Sibila, O., Laserna, E., Maselli, D.J., Fernandez, J.F., Mortensen, E.M., Anzueto, A., Waterer, G. and Restrepo, M.I. (2015) Risk Factors and Antibiotic Therapy in *P. aeruginosa* Community-Acquired Pneumonia. *Respirology*, **20**, 660-666. <http://dx.doi.org/10.1111/resp.12506>
- [5] Quirk, J.A., Beaman, M.H. and Blake, M. (1990) Community-Acquired *Pseudomonas* Pneumonia in a Normal Host Complicated by Metastatic Panophthalmitis and Cutaneous Pustules. *Australian and New Zealand Journal of Medicine*, **20**, 254-256. <http://dx.doi.org/10.1111/j.1445-5994.1990.tb01033.x>
- [6] Harris, A.A., Goodman, L. and Levins, S. (1984) Community-Acquired *Pseudomonas aeruginosa* Pneumonia Associated with the Use of a Home Humidifier. *The Western Journal of Medicine*, **141**, 521-523.
- [7] Govan, J., Reiss-Levy, E., Bader, L. and Schonell, M. (1977) *Pseudomonas* Pneumonia with Bacteraemia. *Medical Journal of Australia*, **1**, 627-628.
- [8] Hoogwrf, B.J. and Khan, M.Y. (1981) Community-Acquired Bacteremic *Pseudomonas* Pneumonia in a Health Adult. *American Review of Respiratory Disease*, **123**, 132-134.
- [9] Fishman, H., Eaton, B., Lipson, A. and Delaney, M.D. (1983) Primary *Pseudomonas aeruginosa* in a Previously Healthy Man. *Southern Medical Journal*, **76**, 260-262. <http://dx.doi.org/10.1097/00007611-198302000-00033>
- [10] Henderson, A., Kelly, W. and Wright, M. (1992) Fulminant Primary *Pseudomonas aeruginosa* Pneumonia Abdominal Septicaemia in Previously Well Adults. *Intensive Care Medicine*, **18**, 430-432. <http://dx.doi.org/10.1007/BF01694348>
- [11] Ishihara, S., Takino, M., Okada, Y. and Mimura, K. (1995) Septic Shock Due to *Pseudomonas aeruginosa* in a Previously Healthy Woman. *Intensive Care Medicine*, **21**, 226-228. <http://dx.doi.org/10.1007/BF01701476>
- [12] Okamoto, M., Yamaoka, J., Chikayama, S., Ohishi, T., Nakajima, T. and Nakashima, T. (2012) Successful Treatment of a Previously Healthy Woman with *Pseudomonas aeruginosa* Community-Acquired Pneumonia with Plasmapheresis. *Internal Medicine*, **51**, 2809-2812. <http://dx.doi.org/10.2169/internalmedicine.51.7921>
- [13] Takakura, A., Katono, K., Harada, S., Igawa, S., Katagiri, M., Yanase, N. and Masuda, N.

- (2015) Two Cases of Rapidly Progressive Community-Acquired Pneumonia Due to *Pseudomonas aeruginosa*. *The Journal of the Japanese Association for Infectious Diseases*, **89**, 56-61.
- [14] Garcia-Vidal, C., Fernández-Sabé, N., Carratalà, J., Díaz, V., Verdaguer, R., Dorca, J., Maresa, F. and Gudiol, F. (2008) Early Mortality in Patients with Community-Acquired Pneumonia: Causes and Risk Factors. *European Respiratory Journal*, **32**, 733-739.
<http://dx.doi.org/10.1183/09031936.00128107>
- [15] Arancibia, F., Bauer, T.T., Ewig, S., Mensa, J., Gonzalez, J., Niederman, M.S. and Torres A. (2002) Community-Acquired Pneumonia Due to Gram-Negative Bacteria and *Pseudomonas aeruginosa*. *Archives of Internal Medicine*, **162**, 1849-1858.
<http://dx.doi.org/10.1001/archinte.162.16.1849>



Scientific Research Publishing

Submit or recommend next manuscript to SCIRP and we will provide best service for you:

Accepting pre-submission inquiries through Email, Facebook, LinkedIn, Twitter, etc.
A wide selection of journals (inclusive of 9 subjects, more than 200 journals)
Providing 24-hour high-quality service
User-friendly online submission system
Fair and swift peer-review system
Efficient typesetting and proofreading procedure
Display of the result of downloads and visits, as well as the number of cited articles
Maximum dissemination of your research work

Submit your manuscript at: <http://papersubmission.scirp.org/>

Or contact crum@scirp.org