

# New Approach in the Management of Adult Epiglottic Abscess—A Case Report

**Ramesh Babu Kalyanasundaram\***, Ganesh Kumar Balasubramanian,  
Ramanathan Thirunavukkarasu, Prabhakaran Saroja Durairaju

Department of ENT and Head & Neck surgery, Thanjavur Medical College, Thanjavur, India  
Email: [k.rameshbabu.ent@gmail.com](mailto:k.rameshbabu.ent@gmail.com), [drganeshkumarb@gmail.com](mailto:drganeshkumarb@gmail.com)

Received 20 March 2015; accepted 14 July 2015; published 17 July 2015

Copyright © 2015 by authors and Scientific Research Publishing Inc.

This work is licensed under the Creative Commons Attribution International License (CC BY).

<http://creativecommons.org/licenses/by/4.0/>



Open Access

---

## Abstract

**Background:** Epiglottic abscess in an otherwise healthy adult is seen as a rare sequelae of acute epiglottitis. It is a life threatening condition which requires emergency management, which if not done early, may result in fatality. Respiratory infections, exposure to environmental chemical or trauma which may lead to inflammation and infection of the structures around the throat which may lead on to epiglottitis, and an epiglottis abscess very rarely. In our case, patient was immediately managed by doing an emergency tracheostomy followed by incision and drainage in the OPD (outpatient department). This emphasizes on need for emergency airway management by doing a tracheostomy there by facilitating incision and drainage in a case of epiglottic abscess as a daycare procedure. **Aim:** The primary aim of this clinical record is to emphasize the need for immediate airway management in epiglottic abscess there by facilitating incision and drainage as an OPD (out-patient department) Procedure. **Case Presentation:** A 45-year-old man presented to the OPD (outpatient department) with complaints of dysphagia, odynophagia, muffled voice, noisy breathing for the previous 7 hours. On clinical examination pt was in stridor & respiratory distress. Since the pt was in stridor, it was immediately shifted to the OT (operation theatre), and an emergency tracheostomy was done and the airway was secured, following which a video laryngoscopic examination was done in the OPD, which revealed oedematous enlarged epiglottis with pus pointing obscuring the laryngeal inlet. Abscess was incised and drained, and pus was sent for culture & sensitivity. Pt was treated with I. V (intravenous) antibiotics as per culture reports and subsequent video laryngoscopic examination revealed near normal epiglottis with an adequate laryngeal inlet. **Conclusion:** Patients with epiglottic abscess are at increased risk of airway compromise, hence in such patients airway should be immediately secured by doing an emergency tracheostomy. This case shows the benefits of an emergency tracheostomy for doing incision and drainage for epiglottic abscess as an OPD procedure.

\*Corresponding author.

**How to cite this paper:** Kalyanasundaram, R.B., Balasubramanian, G.K., Thirunavukkarasu, R. and Durairaju, P.S. (2015) New Approach in the Management of Adult Epiglottic Abscess—A Case Report. *International Journal of Otolaryngology and Head & Neck Surgery*, 4, 290-295. <http://dx.doi.org/10.4236/ijohns.2015.44050>

## Keywords

### Epiglottic Abscess, Epiglottitis, Tracheostomy, Incision and Drainage

## 1. Introduction

Epiglottic abscess is a rare complication of acute epiglottitis. Epiglottitis is an acute inflammation of the supraglottic region of the larynx involving epiglottis, arytenoids, vallecula and aryepiglottic folds. The development of epiglottic abscess from epiglottitis secondary to radiotherapy has previously been described in literature. Epiglottic abscess incidence among patient with acute epiglottitis is around 4%. It is due to respiratory infections, exposure to environmental chemicals and trauma. Previously, the incidence was reportedly more common in children. But recently the incidence of epiglottic abscess is found to be more common in adults. The incidence in adults is 1 case per 100,000 per year. Incidence is more common in males than in females with a ratio of 3:1. We present a case report of a 45-year-old male with epiglottic abscess, managed with emergency tracheostomy followed by endoscopic assisted incision and drainage of the abscess as an OPD (out-patient department) procedure.

## 2. Case Report

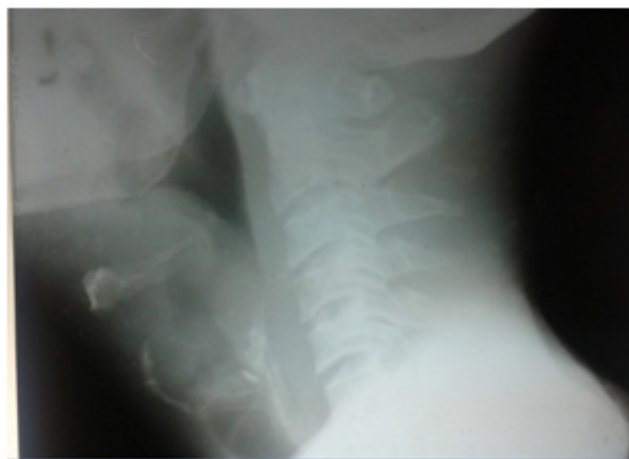A 45-year-old male presented to the OPD (out-patient department) with complaints of dysphagia, odynophagia, muffled voice, noisy breathing for the previous 7 hours. On clinical examination, patient was in stridor, tachycardia. O<sub>2</sub> saturation was 90%. X-Ray STNL (soft tissue neck lateral view) revealed edema of the epiglottis (thumb sign) (**Figure 1**) with airway obstruction.

Since the patient was in stridor, after doing basic investigations, patient was shifted to the OT (operation theatre) and an emergency tracheostomy was done and the airway was secured.

Post tracheostomy (**Figure 2**), In the OPD a video laryngoscopic examination using a 30 degree/4 mm Hopkins rod was done and it revealed an edematous, enlarged yellowish red appearing epiglottis with pus pointing (**Figure 3**) on the lingual surface, obscuring the laryngeal inlet.

Abscess was incised and about 10 - 15 ml of frank pus was drained (**Figure 4**) and the purulent material was sent for culture and antibiotic sensitivity.

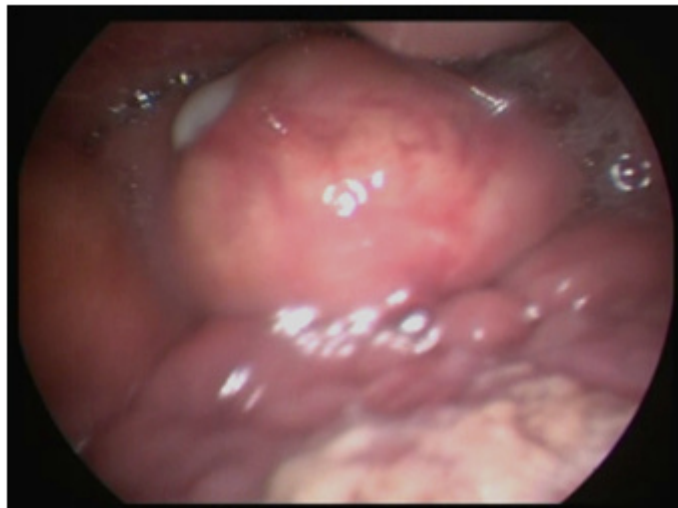In the post operative period, patient was stable and was managed with I.V (intravenous) third generation cephalosporins and I.V metronidazole. Culture report showed *Klebsiella pneumonia* growth, sensitive to ciprofloxacin, co-trimoxazole and ceftriaxone. Four days later, repeat video laryngoscopy was done which revealed a decrease in the edema of the epiglottis, enabling the visualisation of the laryngeal inlet which was found to be adequate. Three days later, another repeat video laryngoscopy revealed a near normal epiglottis (**Figure 5**) with a healthy slough covering. Decannulation was done on the 10<sup>th</sup> POD (**Figure 6**) and the patient was discharged on the 14<sup>th</sup> day (**Figure 7**).



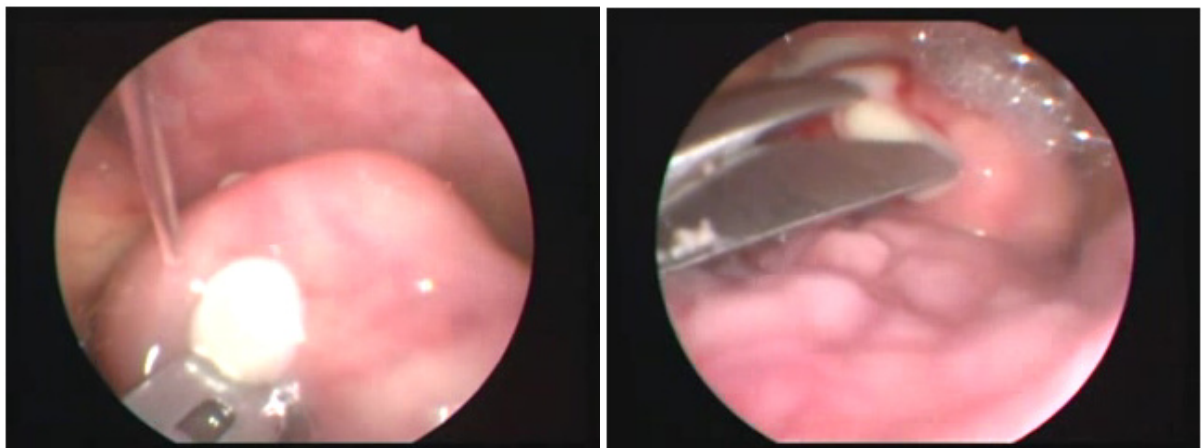
**Figure 1.** X-Ray STNL showing edema of the epiglottis (thumb sign).



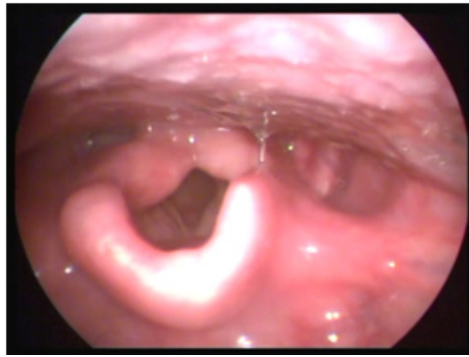
**Figure 2.** Post tracheostomy.



**Figure 3.** Edematous epiglottis with puspointing.



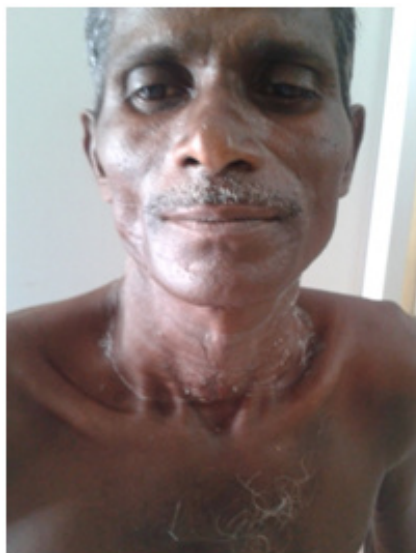**Figure 4.** Incision and drainage.



**Figure 5.** Post operative day 7—near normal epiglottis.



**Figure 6.** Post operative day-10.



**Figure 7.** Post operative day-14.

### 3. Discussion

Epiglottic abscess is a sequelae of acute epiglottitis, precisely known as supraglottitis. Supraglottitis is the acute inflammation involving the epiglottis, arytenoids, vallecula and the aryepiglottic fold. The development of epiglottic abscess from epiglottitis secondary to radiotherapy has previously been described in the literature [1]. Epiglottic abscess incidence among patient with acute epiglottitis is around 4%. It is due to respiratory infections [2], exposure to environmental chemicals and trauma. The rising incidence of adult epiglottic abscess has risen between 1986 and 2000. This seems unrelated to *Haemophilus influenzae* Type B, but related to miscellaneous bacteria [3]. Clinical features include sore throat, respiratory difficulty, dysphagia, change in voice. Fatal air way obstruction can occur without warning, indicating a need for early need for early protection of airway in adults as well in children. Incidence was more common in children previously, but recently there has been a steady increase in incidence in the adults [4]. The decrease in incidence in the pediatric age is probably due to the introduction of the H. influenza B vaccine in children [4]. Incidence is more common in males than in females with a ratio of 3:1, the average age group being 45 years [5]. Physical findings are epiglottic asymmetry, a yellow colored epiglottis, prominent median glossoepiglottic furrow and taut appearing epiglottic mucosa [5]. The organisms causing epiglottic abscess were due to streptococcus hemolyticus which was found in pure culture in most of the cases. other organisms isolated were *Hemophilus influenzae*, *Escherichia coli*, *Pseudomonas aeruginosa*, *Micrococcus catarrhalis*, *Staphylococcus aureus*, *klebsiella pneumoniae* and pneumococci [6]. Risk factors include adult age at onset, diabetes mellitus, presence of foreign body, immune compromised state [6].

A diagnosis of epiglottic abscess should be considered in a patient with sore throat, epiglottitis, dyspnea, stridor. CT and MRI may reveal thickening of the epiglottis, obliteration of the pre-epiglottic fat and thickening of the subcutaneous tissue and muscles [7]. Lateral neck radiographs and CT imaging may be helpful but a prompt and accurate diagnosis can be established with flexible fiberoptic Nasopharyngo laryngoscope. The lingual surface is the most commonly involved site [7]. Differential diagnosis includes abscess of deep neck space, peritonsillar abscess, lingual tonsillitis, laryngitis, ingested foreign body.

The principles of treatment for patients with epiglottic abscess are immediate airway management, direct laryngoscopy with incision and drainage of the abscess and intravenous administration of broad spectrum antibiotics.

### 4. Outcome and Follow Up

By doing an emergency tracheostomy followed by incision and drainage the patient was managed promptly. Patient has been on follow up for the past two months in the OPD and subsequent video laryngoscopic examinations revealed a normal epiglottis with an adequate laryngeal inlet.

### 5. Conclusions

- Patients with epiglottic abscess are at increased risk of airway compromise, hence in such patients airway should be immediately secured by doing an emergency tracheostomy.
- Any undue manipulation would lead to or precipitate glottic spasm.
- In previously managed epiglottic abscesses, incision and drainage were done in the OT under general anesthesia, but we did this procedure in the OPD under local anesthesia.
- This case shows the benefits of an emergency tracheostomy for doing incision and drainage for epiglottic abscess as an OPD procedure.

### References

- [1] Harvey, M., Quagliotto, G. and Milne, N. (2012) Fatal Epiglottic Abscess after Radiotherapy for Laryngeal Carcinoma. *American Journal of Forensic Medicine & Pathology*, **33**, 297-299. <http://dx.doi.org/10.1097/PAF.0b013e318221be6a>
- [2] Ellenbogen Ram, N.C., Raim, J. and Lytton, L. (1955) Abscess of the Epiglottis-Problem in Differential Diagnosis. *JAMA*, **159**, 1289-1290. <http://dx.doi.org/10.1001/jama.1955.02960300035009a>
- [3] Berger, G., Landau, T., Berger, S., Finkelstein, Y., Bernheim, J. and Ophir, D. (2003) The Rising Incidence of Adult Acute Epiglottitis and Epiglottic Abscess. *American Journal of Otolaryngology*, **24**, 374-383.
- [4] Mayo-Smith, M.F., Spinale, J.W., Donskey, C.J., Yukawa, M., Li, R.H. and Sciffman, F.J. (1995) Aute Epiglottitis. *The New England Journal of Medicine*, **108**, 1640-1647.

- [5] Vaileadis, I., Kapetanakis, S., Vaileiadis, D., Petousis, A. and Karatzas, T. (2013) Epiglottic Abscess Causing Airway Obstruction in an Adult. *Journal of the College of Physicians and Surgeons Pakistan*, **23**, 673-675.
- [6] Deepalakshmi, T., Devan, P.P. and Prasad, M. (2014) An Unusual Case of Acute Epiglottic Abscess. *Iranian Journal of Otorhinolaryngology*, **26**, 56.
- [7] Al-Qudah, M., Shetty, S., Alomari, M. and Alqdah, M. (2010) Acute Adult Supraglottitis: Current Management and Treatment. *Southern Medical Journal*, **103**, 800-804.