

Clinico-Radiological Correlation in Children with Ataxia Telangiectasia in Qatar

Mohammad Ehlayel^{1,2*}, Mahmoud F. Elsaid^{1,3}, Rana Shami³, Khalid Salem⁴,
Abdulbari Bener^{5,6}

¹Weill Cornell Medical College, Doha, Qatar

²Section of Pediatric Allergy-Immunology, Department of Pediatrics, Hamad Medical Corporation, Doha, Qatar

³Section of Pediatric Neurology, Department of Pediatrics, Hamad Medical Corporation, Doha, Qatar

⁴Department of Radiology, Hamad Medical Corporation, Doha, Qatar

⁵Department of Biostatistics & Medical Informatics, Cerrahpaşa Faculty of Medicine, Istanbul University, Istanbul, Turkey

⁶Department Evidence for Population Health Unit, School of Epidemiology and Health Sciences, The University of Manchester, Manchester, UK

Email: *mehlaye@gmail.com, *mehlayel@hmc.org.qa

Received 16 February 2015; accepted 12 March 2015; published 17 March 2015

Copyright © 2015 by authors and Scientific Research Publishing Inc.

This work is licensed under the Creative Commons Attribution International License (CC BY).

<http://creativecommons.org/licenses/by/4.0/>



Open Access

Abstract

Introduction: Ataxia telangiectasia (AT) is a rare disease characterized by immunodeficiency and neurological manifestations. Ataxia, resulting from cerebella atrophy, runs a progressive incapacitating course. Clinical monitoring of the disease course is mandatory for early treatment. **Aim:** To study clinical severity of AT and correlate it with the degree of cerebellar atrophy. **Patients and Methods:** We retrospectively studied all children (less than 14 years) with AT seen at Hamad General Hospital Clinics between 1998-2013. We collected basic demographic data, parental consanguinity, family history, AT clinical severity scores, and reviewed CBC with differential counts; alpha-fetoprotein, serum immunoglobulins and lymphocyte subsets. Cranial MRI scans of each subject were reviewed by a neuroradiologist. Cerebellar atrophy was visually and semi-quantitatively scored. **Results:** We analyzed data on 18 AT children (10 males and 8 females), mean age of 76.9 months. 77.8% had a positive family history of AT and 41.7% parental consanguinity. Lymphopenia was observed in 77.8% and high serum alpha-fetoprotein in 87.5% of children. Clinical severity of ataxia was 17.1 ± 8.4 (mean \pm SD); 86.7% of patients were moderate-severe. MRI cerebellar atrophy score was 1.9 ± 1.3 (mean \pm SD), and moderate in 51% of patients. AT clinical severity score correlated (coefficient $r = 0.566$) but not statistically significant ($p = 0.088$) with MRI cerebellar atrophy scores. **Conclusions:** Moderate to severe ataxia and marked cerebellar atrophy are quite common in AT children. There is a correlation between AT clinical severity and cerebellar

*Corresponding author.

atrophy. Larger prospective studies might further determine the significance of our observations and help practicing practitioners monitor the progression of the disease.

Keywords

Ataxia Telangiectasia, Cerebellar Atrophy, MRI, Clinical Severity, Children

1. Introduction

Ataxia telangiectasia (AT) is one of the rare, genetic, primary immunodeficiency diseases [1]. It is mainly characterized by immunodeficiency and neurological manifestations, with increased risk of infections, autoimmunity and malignancy [2]. It is caused by mutations involving ATM (ataxia telangiectasia, mutated) gene [3]. The ATM gene encodes for production of “serine/threonine kinase”, an enzyme that has multiple important functions that lead to tumor suppression and DNA repair [4]. Mutations of ATM make cells prone to degenerative changes, most important of which neurodegeneration. Studies of lymphoblastoid cell lines from AT patients revealed correlation between ATM mutations and clinical phenotype of the disease in these patients [5] [6]. Furthermore, the degree of ATM kinase activity determined the clinical severity of the disease [7].

Neurologic abnormalities of AT include truncal and limbs ataxia, dysarthria, swallowing incoordination, masked faces, ophthalmoplegia, and others such as delayed peripheral and movement disorders [2]. Although severe immunodeficiency may not be apparent in some patients [8], neurological features are constant and start in the first few years of life. Patients become wheelchair-dependent by early adolescence. Cerebellar atrophy, the hallmark of the disease, is related to neurodegenerative changes involving Purkinje cells [4] [9]. Head CT scanning was used in some studies, and MRI imaging is currently used for evaluation of cerebellar atrophy in AT patients [10]-[12]. Positron emission tomography has been utilized to study the functional aspects of the brain in these cases [13]. There are no studies trying to correlate the clinical severity of AT with that of cerebellar atrophy in either children or adults with the disease.

2. Objectives

In this study, we tried to categorize clinical severity of disease among AT children, score degree of cerebellar atrophy, and determine if there is any correlation between the clinical severity and degree of cerebellar atrophy.

3. Methods and Patients

In this retrospective cross-sectional study, we reviewed the medical records of all children, younger than 14 years, who were diagnosed (by ME, MFO) to have ataxia telangiectasia at Ped Allergy-Immunology and Ped Neurology Clinics at Hamad General Hospital between 1998 and 2013.

Each case record of AT children was reviewed, and data collected on a standard form, included patient’s age, sex, nationality, parental consanguinity, and family history of AT.

Scale for assessment and rating of ataxia (SARA) was used with adaptation to be more practical for young ages [14]. Children were considered to be normal if AT Clinical severity score = 0, mild disease if score = 1 - 10, moderate if score = 11 - 20, severe if score = 21 - 30.

Laboratory workup included CBC with differential counts; alpha fetoprotein; and immunological tests (serum IgG, IgA, IgM, IgE, IgG-subclasses, and lymphocyte subpopulations of T-cell subsets (CD3, CD4, CD8), B cell (CD19) and natural killer cell (CD56/16). Patient’s age at time of head MRI was also noted.

Head MRI scan were independently reviewed by a senior experienced neuroradiologist (KS) who for cerebellar atrophy, brain stem, basal ganglia, cerebra, and thoracic spine. Cerebellar atrophy was visually and semi-quantitatively scored and graded into 4 Cerebellar Atrophy Severity Grades (CASG): a) normal CASG = 0, no abnormalities noticed; b) mild CASG = 1, mild, widening of few folia; c) moderate CASG = 2, where several sulci and cisterni are wide and fourth ventricle is prominent; and d) severe CASG = 3, where all sulci and cisterni are markedly wide. Other radiological abnormalities were observed. The Research Ethics Committee at Hamad General Hospital of Hamad Medical Corporation approved this study.

4. Statistical Analysis

Data was analyzed using Statistical Package for Social Sciences (SPSS version 21). Student-t test was used to ascertain the significance of differences between mean values of two continuous variables and confirmed by non-parametric Mann-Whitney test. Spearman's non-parametric correlation coefficient was used for determine the association between the two different scores. The level $p < 0.05$ was considered as the cut-off value for significance.

5. Results

A total of 18 patients with AT were seen during 1998-2013. **Table 1** demonstrates their basic characteristics. They were born to 12 families: 8 (44.4%) children were born to 5 (41.7%, of 12 families) consanguineous families, and 10 (55.6%) children belonged to non-consanguineous marriages. Having a high rate of positive family history of AT in the cohort helped diagnosing 8 patients (44.4%) before age of 5 years and 3 of them were less than 24 months. Elevated serum alpha-fetoprotein was demonstrated in 14 patients (16 of patients tested, 87.5%), and lymphopenia (defined by the presence of <3000 cells/ μL of lymphocytes in peripheral blood in infants younger than 24 months, and <1500 cells/ μL in older children) was observed in 14 (77.8%) patients. We utilized high alpha-fetoprotein and lymphopenia in presence of family history as laboratory markers on possibility of AT diagnosis even before clinical neurological or immunological abnormalities detected.

The median AT clinical severity score was 16, close to the average of 17.1. There was complete data of AT clinical score in 15 patients: 2 patients (11.1%) had mild ataxia, 9 patients (50%) moderate and 4 patients (22.2%) severe. Head MRI was done in 13 patients (72.2%). The average age of patients for head MRI scanning 102 ± 61.8 months (median = 102 months). The average grade of cerebellar atrophy on head MRI was 1.9 ± 1.3 (mean \pm SD), median 2.0. Moderate cerebellar atrophy was noticed in 51% of patients. Sinusitis was incidentally observed in head MRI in 7 patients (38.9%).

Correlation of AT clinical severity score and MRI grade of cerebellar atrophy are shown in **Figure 1**. Ten patients had data on both AT clinical severity score and MRI cerebellar atrophy grades, and revealed correlation (coefficient $r = 0.566$) but it was not statistically significant ($p = 0.088$, 95% CI for $r = -0.2790$ to 0.8321).

Table 1. The demographic and laboratory characteristics of children with AT.

Variable	N = 18 patients
Age (months, mean \pm SD)	76.9 \pm 39.3
Sex:	
Male	10
Females	8
M/F ratio	1.25/1.0
No. of families	6
Family history of AT	
Positive	14 (77.78%)
Negative	4 (22.2%)
White blood cells ($\times 10^3$ cells/ μL) [*]	5180 \pm 1593
Absolute lymphocyte count	1894.0 \pm 1093
Alpha-fetoprotein (mg/L, mean \pm SD)	104.1 \pm 91.7
AT clinical severity score:	
Average (mean \pm SD)	17.1 \pm 8.4
Median	16
Mild	2 (11.1%)
Moderate	9 (50%)
Severe	4 (22.2%)
No data	3 (16.7%)

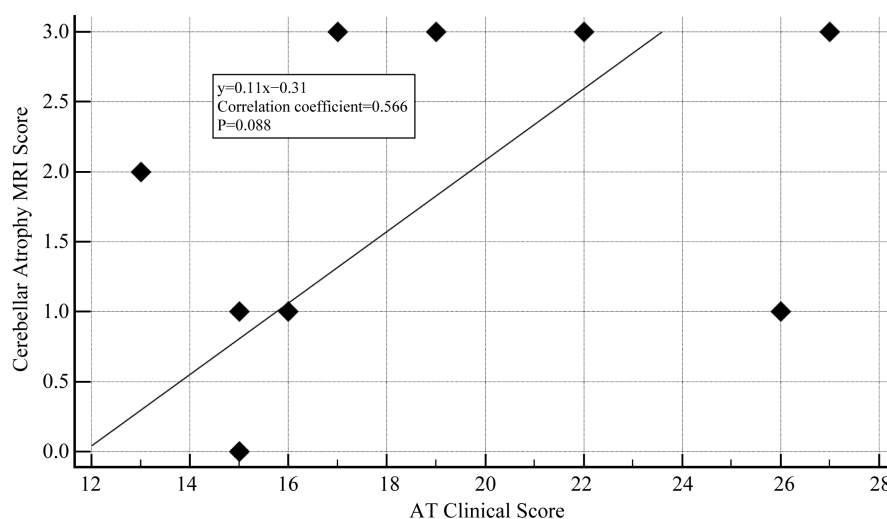


Figure 1. Correlation between clinical severity score AT and MRI cerebellar atrophy in children with AT.

6. Discussion

Among children or adults with AT, there are no studies on distribution of AT according to clinical severity, or any literature trying to correlate clinical severity with cerebellar atrophy. This study, to the best of our knowledge, is the first to describe how common the cerebellar atrophy, and objectively attempt to correlate the AT clinical severity with MRI imaging in this disease among children. More than 80% of our patients had moderate to severe AT, 85% had cerebellar atrophy, 62% of which was moderate to severe.

Medical literature is deficient on distribution of AT according to clinical severity. This could be attributable to lack of simple, quick, and reliable, age-dependent, clinical toolkits. Various studies indicate that clinical severity of AT is determined by type and severity of ATM mutations (e.g. null, missense, or specific types of mutations) affecting level or function of ATM protein [5]. This effect seems to be in a dose-dependent manner where milder phenotypes were reported late and in adults [7] [15] [16]. Different types of clinical severity scales (e.g. A-T Neuro Examination Scale Toolkit, International Cooperative Ataxia Rating Scale, Brief Ataxia Rating Scale) are used to evaluate or monitor the severity of adults-variants AT and other types of ataxias such as (Friedreich spinocerebellar ataxia) [17]-[22]. Validity and reliability of these scales in children with ataxia has recently been determined [23]. They are influenced by child's age [23]. This seems to be a factor that limits their routine clinical use in monitoring progression of AT in children. In our study, majority of patients had moderate-to-severe AT.

The fact that our study revealed a clinical but non-significant correlation between AT clinical score and severity of cerebellar atrophy could be attributed to some factors such as sample size and nature of study. A larger sample and prospective cohort study with serial AT clinical scores simultaneous with MRI scores done at specific age of each child might have increased the significance of the association.

Use of clinical score, as a clinical tool surrogate to MRI neuroimaging, for monitoring AT progression is important. MRI is used as the safe instrument to evaluate cerebellar atrophy in AT [24]. In our cohort, 85% our patients had cerebellar atrophy and correlated, though not statically significant, with clinical severity. The newer MRI-based newer techniques [25]-[27], such proton spectroscopy, functional MR imaging, and various diffusion-related imaging recently used in evaluating progressive ataxia may not be readily available to patients and in a cost-effective manner. Thus development of useful clinical toolkits sensitive to evaluate AT are essential.

Our study has some limitations, the foremost is the small sample size but this is inevitable. In 2014, the total of Qatar population reached 2,123,160 of whom 302,313 are children younger than 14 years [28]. The frequency of AT in Qatar is estimated to be 1 per 16,796 live births, still higher than reported in other regions of the world (in 40,000 to 100,000 people worldwide) [29], and due to high consanguinity rate among primary immunodeficiency diseases in Qatar [30]. Although our study revealed a correlation between clinical severity scales and cerebellar atrophy scores, a larger sample size most likely would have shown a statistical significance. Other limitations include the retrospective and cross-sectional nature of the study.

7. Conclusion

In summary, this study suggests that the majority of children with AT have moderate to severe clinical disease and high rates of cerebellar atrophy. Additionally, our data revealed correlation between clinical severity of the disease and that of cerebellar atrophy, and its statistical non-significance was most likely a result of sample size. Future studies of a larger population with a prospective designs comparing clinical severity with cerebellar structural and/ or functional abnormalities will further determine the significance of our observation. In addition, they would help practicing practitioners utilize clinical scales as a reliable clinical tool in monitoring the disease progression in AT children.

Acknowledgements

The authors would like to thank Hamad Medical Corporation for their support and ethical approval (HMC Research Protocol No. 10078/10).

Authors Contribution

The study proposal was prepared by Ehlayel, and data was collected by Ehlayel, Elsaid, Shami and Salem, analyzed by Bener. The manuscript was drafted, reviewed and approved by all authors.

References

- [1] Rezaei, N., Bonilla, F.A., Sullivan, K.E., de Vries, E. and Orange, J.S. (2008) Chapter 1. An Introduction to Primary Immunodeficiency Diseases. In: Rezaei, N., Aghamohammadi, A. and Notarangelo, L.D., Eds., *Primary Immunodeficiency Diseases, Definition Diagnosis and Management*, Springer-Verlag, Berlin, 1-38. http://dx.doi.org/10.1007/978-3-540-78936-9_1
- [2] (2013) OMIM ATM: 208900. <http://www.omim.org/entry/208900>
- [3] Savitsky, K., Bar-Shira, A., Gilad, S., Rotman, G., Ziv, Y., Vanagaite, L., Tagle, D.A., Smith, S., Uziel, T., Sfez, S., Ashkenazi, M., Pecker, I., Frydman, M., Harnik, R., Patanjali, S.R., Simmons, A., Clines, G.A., Sartiel, A., Gatti, R.A., Chessa, L., Sanal, O., Lavin, M.F., Jaspers, N.G., Taylor, A.M., Arlett, C.F., Miki, T., Weissman, S.M., Lovett, M., Collins, F.S. and Shiloh, Y. (1995) A Single Ataxia Telangiectasia Gene with a Product Similar to PI-3 Kinase. *Science*, **268**, 1749-1753. <http://dx.doi.org/10.1126/science.7792600>
- [4] Hoche, F., Seidel, K., Theis, M., Vlaho, S., Schubert, R., Zielen, S. and Kieslich, M. (2012) Neurodegeneration in Ataxia Telangiectasia: What Is New? What Is Evident? *Neuropediatrics*, **43**, 119-129. <http://dx.doi.org/10.1055/s-0032-1313915>
- [5] Gilad, S., Chessa, L., Khosravi, R., Russell, P., Galanty, Y., Piane, M., Gatti, R.A., Jorgensen, T.J., Shiloh, Y. and Bar-Shira, A. (1998) Genotype-Phenotype Relationships in Ataxia-Telangiectasia and Variants. *American Journal of Human Genetics*, **62**, 551-561. <http://dx.doi.org/10.1086/301755>
- [6] Becker-Catania, S.G., Chen, G., Hwang, M.J., Wang, Z., Sun, X., Sanal, O., Bernatowska-Matuszkiewicz, E., Chessa, L., Lee, E.Y. and Gatti, R.A. (2000) Ataxia-Telangiectasia: Phenotype/Genotype Studies of ATM Protein Expression, Mutations, and Radiosensitivity. *Molecular Genetics and Metabolism*, **70**, 122-133. <http://dx.doi.org/10.1006/mgme.2000.2998>
- [7] Verhagen, M.M., Last, J.I., Hogervorst, F.B., Smeets, D.F., Roeleveld, N., Verheijen, F., Catsman-Berrepoets, C.E., Wulffraat, N.M., Cobben, J.M., Hiel, J., Brunt, E.R., Peeters, E.A., Gomez Garcia, E.B., van der Knaap, M.S., Lincke, C.R., Laan, L.A., Tijssen, M.A., van Rijn, M.A., Majoor-Krakauer, D., Visser, M., van't Veer, L.J., Kleijer, W.J., van de Warrenburg, B.P., Warris, A., de Groot, I.J., de Groot, R., Broeks, A., Preijers, F., Kremer, B.H., Weemaes, C.M., Taylor, M.A., van Deuren, M. and Willemsen, M.A. (2012) Presence of ATM Protein and Residual Kinase Activity Correlates with the Phenotype in Ataxia-Telangiectasia: A Genotype-Phenotype Study. *Human Mutation*, **33**, 561-571. <http://dx.doi.org/10.1002/humu.22016>
- [8] Spacey, S.D., Gatti, R.A. and Bebb, G. (2000) The Molecular Basis and Clinical Management of Ataxia Telangiectasia. *Canadian Journal of Neurological Sciences*, **27**, 184-191. <http://dx.doi.org/10.1017/S031716710000822>
- [9] Fatterpekar, G., Naidich, T.P. and Som, P.M. (2012) The Teaching Files: Brain and Spine Imaging. Elsevier Health Sciences, 102-103.
- [10] Meshram, C.M., Sawhney, I.M.S., Prabhakar, S. and Chopra, J.S. (1986) Ataxia Telangiectasia in Identical Twins: Unusual Features. *Journal of Neurology*, **233**, 304-305. <http://dx.doi.org/10.1007/BF00314163>
- [11] Lin, D.D.M., Barker, P.B., Lederman, H.M. and Crawford, T.O. (2014) Cerebral Abnormalities in Adults with Ataxia-Telangiectasia. *American Journal of Neuroradiology*, **35**, 119-123. <http://dx.doi.org/10.3174/ajnr.A3646>

- [12] Sahama, I., Sinclair, K., Pannek, K., Lavin, M. and Rose, S. (2014) Radiological Imaging in Ataxia Telangiectasia: A Review. *The Cerebellum*, **13**, 521-530. <http://dx.doi.org/10.1007/s12311-014-0557-4>
- [13] Volkow, N.D., Tomasi, D., Wang, G.J., Studentsova, Y., Margus, B. and Crawford, T.O. (2014) Brain Glucose Metabolism in Adults with Ataxia-Telangiectasia and Their Asymptomatic Relatives. *Brain*, **137**, 1753-1761. <http://dx.doi.org/10.1093/brain/awu092>
- [14] Schmitz-Hubsch, T., du Montcel, S.T., Baliko, L., Berciano, J., Boesch, S., Depondt, C., Giunti, P., Globas, C., Infante, J., Kang, J.S., Kremer, B., Mariotti, C., Melegh, B., Pandolfo, M., Rakowicz, M., Ribai, P., Rola, R., Schols, L., Szymanski, S., van de Warrenburg, B.P., Durr, A., Klockgether, T. and Fancellu, R. (2006) Scale for the Assessment and Rating of Ataxia: Development of a New Clinical Scale. *Neurology*, **66**, 1717-1720. <http://dx.doi.org/10.1212/01.wnl.0000219042.60538.92>
- [15] Saviozzi, S., Saluto, A., Taylor, A.M., Last, J.I., Trebini, F., Paradiso, M.C., Grosso, E., Funaro, A., Ponzio, G., Migone, N. and Brusco, A. (2002) A Late Onset Variant of Ataxia-Telangiectasia with a Compound Heterozygous Genotype, A8030G/7481insA. *Journal of Medical Genetics*, **39**, 57-61. <http://dx.doi.org/10.1136/jmg.39.1.57>
- [16] Sutton, I.J., Last, J.I., Ritchie, S.J., Harrington, H.J., Byrd, P.J. and Taylor, A.M. (2004) Adult-Onset Ataxia Telangiectasia Due to ATM 5762ins137 Mutation Homozygosity. *Annals of Neurology*, **55**, 891-895. <http://dx.doi.org/10.1002/ana.20139>
- [17] Burk, K., Schulz, S.R. and Schulz, J.B. (2013) Monitoring Progression in Friedreich Ataxia (FRDA): The Use of Clinical Scales. *Journal of Neurochemistry*, **126**, 118-124. <http://dx.doi.org/10.1111/jnc.12318>
- [18] Crawford, T.O., Mandir, A.S., Lefton-Greif, M.A., Goodman, S.N., Goodman, B.K., Sengul, H. and Lederman, H.M. (2000) Quantitative Neurologic Assessment of Ataxia-Telangiectasia. *Neurology*, **54**, 1505-1509. <http://dx.doi.org/10.1212/WNL.54.7.1505>
- [19] Schmitz-Hubsch, T., Tezenas du Montcel, S., Baliko, L., Boesch, S., Bonato, S., Fancellu, R., Giunti, P., Globas, C., Kang, J.S., Kremer, B., Mariotti, C., Melegh, B., Rakowicz, M., Rola, R., Romano, S., Schols, L., Szymanski, S., van de Warrenburg, B.P., Zdzienicka, E., Durr, A. and Klockgether, T. (2006) Reliability and Validity of the International Cooperative Ataxia Rating Scale: A Study in 156 Spinocerebellar Ataxia Patients. *Movement Disorders*, **21**, 699-704. <http://dx.doi.org/10.1002/mds.20781>
- [20] International Cooperative Ataxia Rating Scale. <http://checkyone.bplaced.net/dokus/ICARS.pdf>
- [21] Saute, J.A., Donis, K.C., Serrano-Munuera, C., Genis, D., Ramirez, L.T., Mazzetti, P., Perez, L.V., Latorre, P., Sequeiros, J., Matilla-Duenas, A. and Jardim, L.B. (2012) Ataxia Rating Scales—Psychometric Profiles, Natural History and Their Application in Clinical Trials. *The Cerebellum*, **11**, 488-504. <http://dx.doi.org/10.1007/s12311-011-0316-8>
- [22] Schmahmann, J.D., Gardner, R., MacMore, J. and Vangel, M.G. (2009) Development of a Brief Ataxia Rating Scale (BARS) Based on a Modified Form of the ICARS. *Movement Disorders*, **24**, 1820-1828. <http://dx.doi.org/10.1002/mds.22681>
- [23] Brandsma, R., Spits, A.H., Kuiper, M.J., Lunsing, R.J., Burger, H., Kremer, H.P. and Sival, D.A. (2014) Ataxia Rating Scales Are Age-Dependent in Healthy Children. *Developmental Medicine & Child Neurology*, **56**, 556-563. <http://dx.doi.org/10.1111/dmcn.12369>
- [24] Sardanelli, F., Parodi, R.C., Ottonello, C., Renzetti, P., Saitta, S., Lignana, E. and Mancardi, G.L. (1995) Cranial MRI in Ataxia-Telangiectasia. *Neuroradiology*, **37**, 77-82. <http://dx.doi.org/10.1007/BF00588526>
- [25] Currie, S., Hadjivassiliou, M., Craven, I.J., Wilkinson, I.D., Griffiths, P.D. and Hoggard, N. (2013) Magnetic Resonance Imaging Biomarkers in Patients with Progressive Ataxia: Current Status and Future Direction. *The Cerebellum*, **12**, 245-266. <http://dx.doi.org/10.1007/s12311-012-0405-3>
- [26] Baldarca, L., Currie, S., Hadjivassiliou, M., Hoggard, N., Jack, A., Jackowski, A.P., Mascalchi, M., Parazzini, C., Reetz, K., Righini, A., Schulz, J.B., Vella, A., Webb, S.J. and Habas, C. (2014) Consensus Paper: Radiological Biomarkers of Cerebellar Diseases. *Cerebellum*, **14**, 175-196.
- [27] Wallis, L.I., Griffiths, P.D., Ritchie, S.J., Romanowski, C.A., Darwent, G. and Wilkinson, I.D. (2007) Proton Spectroscopy and Imaging at 3T in Ataxia-Telangiectasia. *American Journal of Neuroradiology*, **28**, 79-83.
- [28] Ministry of Development, Planning, and Statistics (2013) Qatar Information Exchange. <http://www.qsa.gov.qa/eng/index.htm>
- [29] Genetics Home Reference (2014) Ataxia-Telangiectasia. <http://ghr.nlm.nih.gov/condition/ataxia-telangiectasia>
- [30] Ehlayel, M., Bener, A. and Abu Laban, M. (2013) Effects of Family History and Consanguinity in Primary Immunodeficiency Diseases in Children in Qatar. *Open Journal of Immunology*, **3**, 47-53. <http://dx.doi.org/10.4236/oji.2013.32008>