

Post-Aneurysmal Subarachnoid Hemorrhage Vasospasm, Clinical Correlation between the Aneurysm Site and Clinical Vasospasm

Ahmed Ali, Mohamed A.R. Soliman

Neurosurgery Department, Faculty of Medicine, Cairo University, Cairo, Egypt
Email: moh.ar.sol@kasralainy.edu.eg

How to cite this paper: Ali, A. and Soliman, M.A.R. (2018) Post-Aneurysmal Subarachnoid Hemorrhage Vasospasm, Clinical Correlation between the Aneurysm Site and Clinical Vasospasm. *Open Journal of Modern Neurosurgery*, 8, 306-314.
<https://doi.org/10.4236/ojmn.2018.83025>

Received: June 22, 2018

Accepted: July 21, 2018

Published: July 24, 2018

Copyright © 2018 by authors and Scientific Research Publishing Inc.
This work is licensed under the Creative Commons Attribution International License (CC BY 4.0).

<http://creativecommons.org/licenses/by/4.0/>



Open Access

Abstract

Background: Intracranial vasospasm is a common complication following subarachnoid hemorrhage (SAH). The radiographic vasospasm can reach up to 90% of aneurysmal SAH. **Materials and Methods:** 139 consecutive patients admitted to Cairo University Hospitals from June 2013 to September 2014 with SAH who had been enrolled in a retrospective controlled study were analyzed retrospectively for the occurrence of vasospasm. The data collected from the charts of Cairo University Hospitals were the patient's demographics, clinical presentation, aneurysm location, treatment modality, and Glasgow Outcome Scale (GOS) scores. We excluded 24 patients with nonaneurysmal SAH, 3 internal carotid artery (ICA) aneurysms, 7 with multiple aneurysms and 4 patients died before treatment. **Results:** 72 males and 29 females were included in the study, mean age 53.5 ± 11.5 years. Twelve patients had aneurysms located in the vertebral artery group, 24 had middle cerebral artery aneurysms, 11 had pericallosal aneurysms, and 54 patients had anterior communicating artery (ACoA) complex aneurysms. Radiographic vasospasm occurred in 62.4% with the highest incidence (75.9%) at the ACoA complex group. Symptomatic vasospasm occurred in 48.5% with the highest incidence (63%) at the anterior communicating artery complex aneurysm location. The mean GOS at 6 months follow-up was 4.2. The worse GOS was found in the vertebral artery (VA) aneurysm group with a mean of 3.75. **Conclusion:** Aneurysms of the anterior communicating artery complex group have a greater risk of both radiographic and clinical vasospasm. Also, the worse 6 months follow-up GOS when an aneurysm was located in the VA group.

Keywords

Aneurysm Location, Subarachnoid Hemorrhage (SAH), Vasospasm, Glasgow Outcome Scale (GOS)

1. Introduction

Intracranial vasospasm is a common complication following subarachnoid hemorrhage (SAH). The vasospasm can be either radiographic vasospasm (angiographic vasospasm) or it can be symptomatic vasospasm (Delayed Ischemic Neurologic Deficit (DIND)) [1]. The radiographic vasospasm can reach up to 90% of aneurysmal SAH [2].

In aneurysmal SAH, two third of the cases will have a moderate vasospasm in at least one of the cerebral arteries. Half of these patients will develop symptoms due to ischemia [3]. Cerebral infarction is significantly associated with increasing patient age, history of diabetes mellitus, hypertension, chest infection, worse neurological status on admission, induced hypertension, and large aneurysms [4].

Symptoms of cerebral vasospasm most commonly appear between the 4th and the 12th day after the onset of SAH but can occur later; accordingly, it is important to remain cautious for this complication for at least 2 weeks after SAH. Symptomatic vasospasm usually has a gradual onset which can be heralded by behavioral changes or increased headache, so careful and regular bedside examination remains the most effective and simplest means of detecting early ischemia in examinable and awake patients; one should search for subtle findings such as decreased concentration, changes in verbal output, or newly developed pronator drift of the upper extremity. Only a small percentage of patients developed precipitous deterioration [5].

There are several causes of delayed deterioration after SAH that must be ruled out by radiological and laboratory investigations before diagnosing symptomatic vasospasm, these causes are; rebleeding of aneurysms or aneurysmal remnant, increased edema surrounding hematomas, or infarcts, hydrocephalus, hyponatremia, or infection [6].

We sought to study the relationship between the vasospasm (clinical and radiographic) and aneurysm location in patients enrolled in a retrospective controlled study.

2. Materials and Methods

139 consecutive patients admitted to Cairo University Hospitals from June 2013 to September 2014 with SAH who had been enrolled in a retrospective controlled study were analyzed retrospectively for the occurrence of vasospasm. The data collected from the charts of Cairo University Hospitals were the patient's demographics, clinical presentation, aneurysm location, treatment modality, and neurological outcomes (Glasgow Outcome Scale scores). We excluded 13 patients with nonaneurysmal SAH, 11 patients with Hunt and Hess Grade 4 and 5, 3 ICA aneurysms, 7 with multiple aneurysms and 4 patients died before treatment.

2.1. Clinical Course

All the patients were admitted to an intensive care unit and nimodipine was

given to all patients. Ventricular drainage was done when necessary. Hypertensive therapy was administered when vasospasm is suspicious and continued after confirmation of vasospasm radiographic. All the patients were operated upon by microsurgical clipping with 48 - 72 hours from admission. All patients were assessed for vasospasm in the form of CT angiography or 4-vessel angiography on day 10 post-ictus or if there is any neurological alteration before day 10. If there is clinical or radiological vasospasm, hypertensive therapy was administered. All the patients were treated by microsurgical clipping. All the patient were assessed clinically using Glasgow Outcome Scale [7] (Table 1) postoperatively daily till the day the day of discharge, one-week, one-month, three-month and 6 month post-discharge.

2.2. Grouping of Aneurysms by Location

Based on the aneurysm's proximity to cisterns or fissures the aneurysms were grouped into 1 of 4 locations. The first group was the vertebral artery (VA) location, which included patients with aneurysms of the intradural VA, basilar tip aneurysms, posterior communicating artery and the posterior inferior cerebellar artery (PICA). The second group included the middle cerebral artery (MCA) aneurysms. The third group included the pericallosal arteries aneurysms. The last group included the anterior communicating artery (ACoA) aneurysms, A1, and A2. All the results were compared in terms of mean value and percentage.

2.3. Statistical Analysis

Statistical analysis was performed using GraphPad Prism Software (GraphPad Inc.). For categorical variables, the Fisher exact test was used when comparing 2 groups with 2 outcome categories.

3. Results

One hundred and one patients were included in this study (72 males and 29 females, mean age 53.5 ± 11.5 years). Twelve patients had aneurysms located in the vertebral artery group, 24 had middle cerebral artery aneurysms, 11 had pericallosal aneurysms, and 54 patients had anterior communicating artery complex aneurysms (Table 2).

Table 1. Glasgow outcome scale [7].

GOS	Functional status	Interpretation
1	Death	Severe injury or death without recovery of consciousness
2	Persistent vegetative state	Severe damage with prolonged state of unresponsiveness and a lack of higher mental functions
3	Severe disability	Severe injury with permanent need for help with daily living
4	Moderate disability	No need for assistance in everyday life, employment is possible but may require special equipment
5	Low disability	Light damage with minor neurological and psychological deficits

Table 2. Distribution of the aneurysms according to the location.

Group	No. of Patients (n = 101)	Location of an aneurysm
Vertebral Artery	12	Vertebral artery and PICA
Middle cerebral artery	24	MCA
Pericallosal artery	11	Pericallosal arteries
Anterior communicating artery complex	54	Anterior communicating artery, A ₁ and A ₂

PICA = Posterior Inferior Cerebellar Artery, A₁ = first segment of anterior cerebral artery, A₂ = second segment of anterior cerebral artery, MCA = Middle Cerebral Artery.

3.1. Vasospasm Incidence

Sixty-Three (62.4%) patients developed radiographic vasospasm (**Table 3**). The highest incidence of vasospasm (75.9%) was at the anterior communicating artery complex location group while the lowest incidence (16.7%) in the vertebral artery group (**Figure 1**).

Symptomatic vasospasm occurred in 49 patients (48.5%). The highest incidence of symptomatic vasospasm (63%) was the anterior communicating artery complex aneurysm location while the lowest incidence (8.3%) was also the vertebral artery group (**Figure 2**).

3.2. Outcomes

The mean Glasgow Outcome Score (GOS) (**Table 4**) in 101 patients at 6 months follow-up was 4.2. The worse GOS was found in the VA aneurysm group with a mean of 3.75 and the best GOS was found in the MCA group with a mean score of 4.5.

We divided the outcome into two groups: Poor outcome (GOS 1 - 3) and good outcome (GOS 4 - 5). There was a poor outcome in 26 (25.7%) of 101 patients. There were good outcomes (GOS 4 - 5) in 75 (74.3%) of 101 patients. (**Figure 3**)

The highest relative risk for symptomatic vasospasm was found in the anterior communicating artery complex location group with a ratio of 1.97 and the lowest relative risk was found in the vertebral artery group with a ratio of 0.15 (**Table 5**).

4. Discussion

The greatest cause of morbidity in SAH patients is the cerebral vasospasm causing delayed ischemia [1] [8] [9]. An important prognosticator in the SAH patients is to identify the patient who at a greater risk of developing cerebral and who will likely need prompt management like vasospasm endovascular treatment and/or hypertensive therapy. Harrod and colleagues wrote a systematic review of studies from 1996 to 2005 and the review showed that the burden of blood at the time of SAH is the only predictive factor of cerebral vasospasm [1].

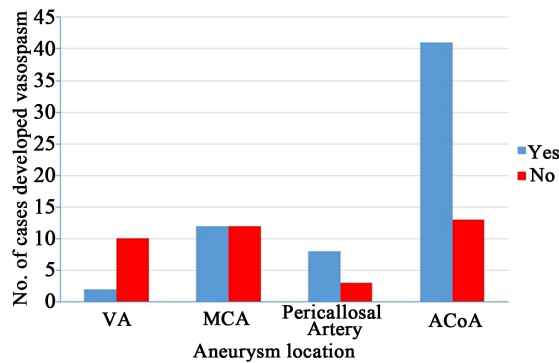


Figure 1. Bar chart showing the presence of any vasospasm in each of the 4 aneurysm location groups. VA = Vertebral Artery, ACoA₁ = Anterior Communicating Artery Aneurysm MCA = Middle Cerebral Artery.

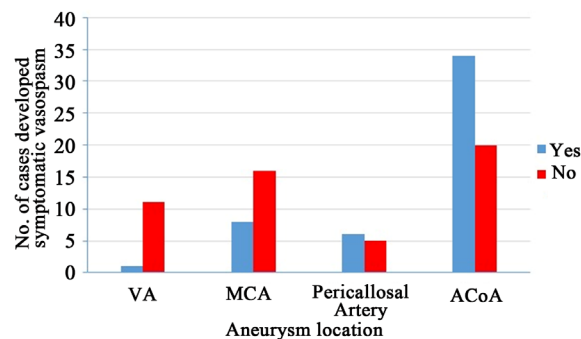


Figure 2. Bar chart showing the presence of symptomatic vasospasm in each of the 4 aneurysm location groups. VA = Vertebral Artery, ACoA₁ = Anterior Communicating Artery Aneurysm MCA = Middle Cerebral Artery.

Table 3. The rate of vasospasm according to location.

Variable	Overall	VA	MCA	Pericallosal	ACoA
No. of patients	101	12	24	11	54
Symptomatic vasospasm					
Yes	49 (48.5%)	1 (8.3%)	8 (33.3%)	6 (54.5%)	34 (63%)
No	52 (51.5%)	11 (91.7%)	16 (66.7%)	5 (45.5%)	20 (37%)
Radiographic vasospasm					
Yes	63 (62.4%)	2 (16.7%)	12 (50%)	8 (72.7%)	41 (75.9%)
No	38 (37.6%)	10 (83.3%)	12 (50%)	3 (27.3%)	13 (24.1%)

VA = Vertebral Artery, ACoA₁ = Anterior Communicating Artery Aneurysm MCA = Middle Cerebral Artery.

Table 4. GOS by aneurysm location.

GOS	VA (n = 12)	MCA (n = 24)	Pericallosal Arteries (n = 11)	ACoA (n = 54)
1	2	2	1	9
2	0	0	0	0
3	2	1	0	3
4	3	2	5	4
5	5	19	5	38

VA = Vertebral Artery, ACoA₁ = Anterior Communicating Artery Aneurysm MCA = Middle Cerebral Artery.

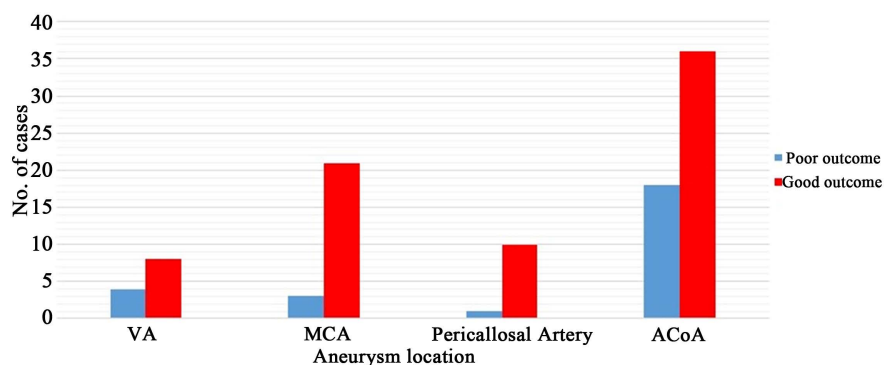


Figure 3. Graph of GOS at 6 months follow-up in each of the 4 aneurysms locations groups showing either poor outcome (GOS 1 - 3) or good outcome (GOS 4 - 5). VA = Vertebral Artery, ACoA₁ = Anterior Communicating Artery Aneurysm MCA = Middle Cerebral Artery.

Table 5. Symptomatic vasospasm risk by aneurysm location.

Aneurysm Location	Relative risk ratio	Odd Ratio
VA	0.15	0.08
MCA	0.63	0.44
Pericallosal Artery	1.14	1.31
ACoA	1.97	3.63

VA = Vertebral Artery, ACoA₁ = Anterior Communicating Artery Aneurysm MCA = Middle Cerebral Artery.

Kistler and colleagues investigated the relation of the location of blood and cerebral vasospasm in 41 patients [8]. They found that the arterial territory involved in the vasospasm was related to the site of the hemorrhage [8]. These results were similar to some previous studies, which correlated the aneurysm location with the cerebral infarction territory [10]. However, the study population was only 41 patients, 20 patients only experienced vasospasm [8].

Yin and colleagues studied 211 patients retrospectively and stratified the aneurysm location into four groups: no aneurysm, posterior circulation, anterior circulation, or unclear. In this study they didn't mention the relation between vasospasm and aneurysm location, may be due to a large number of aneurysms locations [9].

Abla and colleagues studied 216 patients with treated ruptured aneurysm in a randomized controlled trial and stratified the aneurysm location into six groups: intradural ICA, vertebral artery, basilar artery, pericallosal artery, middle cerebral artery, and anterior communicating artery complex. They investigated the relationship between vasospasm and ruptured aneurysm location. Their results showed that there is no significant difference between aneurysm location and the rate of clinical and radiological vasospasm except in the pericallosal artery group had the highest risk of vasospasm. They also analyzed the outcome of the 6 aneurysms location groups and concluded that the worst mean 1-year modified

Rankin scale (mRS) score was in the lower VA aneurysms patients [11].

In our series of 129 patients in a retrospective controlled study, we analyzed retrospectively the relationship between vasospasm and the location of the ruptured aneurysm. Our results showed that when we grouped aneurysms according to location into 4 different groups, the highest incidence of radiographic vasospasm (75.9%) was at the anterior communicating artery complex location group, followed by the pericallosal artery group with an incidence of 72.7% followed by the middle cerebral artery group with an incidence of 50% and the lowest incidence (16.7%) was in the vertebral artery group.

Not all the patients with radiological vasospasm developed symptoms of clinical vasospasm. The anterior communicating artery complex location group remained the highest incidence in the patients with symptomatic vasospasm with an incidence of 63% followed by the pericallosal artery group with an incidence of 54.5% followed by the middle cerebral artery group (33.3%) and the lowest incidence (8.3%) was the vertebral artery group.

We think that the main cause for the increased incidence of vasospasm among the anterior communicating artery complex location group aneurysms is the complexity of the location with very important structures and many perforators supply critical structures.

We also analyzed the outcome of the patients in the 4 aneurysms location groups by using the Glasgow Outcome Score (GOS) in 6-months follow-up. The best prognosis was in the middle cerebral artery group with a mean GOS 6-months follow-up of 4.5 followed by the pericallosal artery group with a mean GOS 6-months follow-up of 4.18 followed by the anterior communicating artery complex location group with a mean GOS 6-months follow up of 3.8 and the worst prognosis was the vertebral artery group with a mean GOS 6-months follow-up of 3.75.

The vertebral artery group has the worst prognosis may be due to the proximity to the lower cranial nerves which might lead to difficulty in swallowing, and ventilator dependency. The anterior communicating artery complex had the second worst prognosis may be due to the complexity of this location with perforators and critical structures.

This study has some limitations because it is a retrospective study. Furthermore, 24 non-aneurysmal SAH patients and 4 patients died before treatment was excluded from this study. All the patients were treated by microvascular clipping with no comparison between the coiling and clipping effect on the outcome of these patients.

5. Conclusion

In this study, we found that aneurysms of the anterior communicating artery complex location group have a greater risk of both radiographic and clinical vasospasm. Also, the patients in this study have the worse 6 months follow-up GOS outcome when an aneurysm was located in the VA group (including the PICA).

References

- [1] Harrod, C.G., Bendok, B.R. and Batjer, H.H. (2005) Prediction of Cerebral Vasospasm in Patients Presenting with Aneurysmal Subarachnoid Hemorrhage: A Review. *Neurosurgery*, **56**, 633-654. <https://doi.org/10.1227/01.NEU.0000156644.45384.92>
- [2] Dorsch, N.W.C. and King, M.T. (1994) A Review of Cerebral Vasospasm in Aneurysmal Subarachnoid Haemorrhage: I. Incidence and Effects. *Journal of Clinical Neuroscience*, **1**, 19-26. [https://doi.org/10.1016/0967-5868\(94\)90005-1](https://doi.org/10.1016/0967-5868(94)90005-1)
- [3] Ferguson, S. and MacDonald, R.L. (2007) Predictors of Cerebral Infarction in Patients with Aneurysmal Subarachnoid Hemorrhage. *Neurosurgery*, **60**, 658-667. <https://doi.org/10.1227/01.NEU.0000255396.23280.31>
- [4] Proust, F., Hannequin, D., Langlois, O., Freger, P. and Crissard, P. (1995) Causes of Morbidity and Mortality after Ruptured Aneurysm Surgery in a Series of 230 Patients: The Importance of Control Angiography. *Stroke*, **26**, 1553-1557. <https://doi.org/10.1161/01.STR.26.9.1553>
- [5] Fisher, C.M., Roberson, G.H. and Ojemann, R.G. (1977) Cerebral Vasospasm with Ruptured Saccular Aneurysm—The Clinical Manifestations. *Neurosurgery*, **1**, 245-258. <https://doi.org/10.1227/00006123-197711000-00004>
- [6] Kramer, A.H., Hehir, M., Nathan, B. and Gress, D. (2008) A Comparison of 3 Radiographic Scales for the Prediction of Delayed Ischemia and Prognosis Following Subarachnoid Hemorrhage. *Journal of Neurosurgery*, **109**, 199-207. <https://doi.org/10.3171/JNS/2008/109/8/0199>
- [7] Jennett, B. and Bond, M. (1975) Assessment of Outcome after Severe Brain Damage. *Lancet*, **1**, 480-484. [https://doi.org/10.1016/S0140-6736\(75\)92830-5](https://doi.org/10.1016/S0140-6736(75)92830-5)
- [8] Kistler, J.P., Crowell, R.M., Davis, K.R., Heros, R., Ojemann, R.G., Zervas, T., *et al.* (1983) The Relation of Cerebral Vasospasm to the Extent and Location of Subarachnoid Blood Visualized by CT Scan: A Prospective Study. *Neurology*, **33**, 424-436. <https://doi.org/10.1212/WNL.33.4.424>
- [9] Yin, L., Ma, C.Y., Li, Z.K., Wang, D.D. and Bai, C.M. (2011) Predictors Analysis of Symptomatic Cerebral Vasospasm after Subarachnoid Hemorrhage. *Acta Neurochirurgica Supplement*, **110**, 175-178.
- [10] Rabinstein, A.A., Friedman, J.A., Weigand, S.D., McClelland, R.L., Fulgham, J.R., Manno, E.M., *et al.* (2004) Predictors of Cerebral Infarction in Aneurysmal Subarachnoid Hemorrhage. *Stroke*, **35**, 1862-1866. <https://doi.org/10.1161/01.STR.0000133132.76983.8e>
- [11] Abla, A., Wilson, D., Williamson, R., Nakaii, P., McDougall, C.G., Zabramski, J.M., *et al.* (2014) The Relationship between Ruptured Aneurysm Location, Subarachnoid Hemorrhage Clot Thickness, and Incidence of Radiographic or Symptomatic Vasospasm in Patients Enrolled in a Prospective Randomized Controlled Trial. *Journal of Neurosurgery*, **120**, 391-397. <https://doi.org/10.3171/2013.10.JNS13419>

List of Abbreviations

- A₁: 1st part of anterior cerebral artery
- A₂: 2nd part of anterior cerebral artery
- ACoA: Anterior communicating artery
- DIND: Delayed Ischemic Neurologic Deficit
- GOS: Glasgow Outcome Score
- ICA: Internal carotid artery
- MCA: Middle cerebral artery
- mRS: Modified Rankin scale
- PICA: Posterior inferior cerebellar artery
- SAH: Subarachnoid hemorrhage