

# Conservative management of cervical pregnancy: The utility of methotrexate treatment and uterine artery embolization

Hisashi Masuyama, Seiji Inoue, Etsuko Nobumoto, Kei Hayata, Tomonori Segawa, Yuji Hiramatsu

Department of Obstetrics and Gynecology, Okayama University Graduate School of Medicine, Dentistry and Pharmaceutical Science, Okayama, Japan

Email: [masuyama@cc.okayama-u.ac.jp](mailto:masuyama@cc.okayama-u.ac.jp)

Received 3 November 2013; revised 24 November 2013; accepted 1 December 2013

Copyright © 2013 Hisashi Masuyama *et al.* This is an open access article distributed under the Creative Commons Attribution License, which permits unrestricted use, distribution, and reproduction in any medium, provided the original work is properly cited. In accordance of the Creative Commons Attribution License all Copyrights © 2013 are reserved for SCIRP and the owner of the intellectual property Hisashi Masuyama *et al.* All Copyright © 2013 are guarded by law and by SCIRP as a guardian

## ABSTRACT

The aim of this retrospective case series report is to evaluate systemic methotrexate therapy in conjunction with uterine artery embolization (UAE) in the conservative management of cervical pregnancy. We examined clinical presentations, treatments, and therapeutic outcomes in fifteen patients with a cervical pregnancy who wished for preservation of fertility, treated at Okayama University Hospital between 1998 and 2012. Twelve patients received systemic methotrexate including five treated with UAE. One was treated with UAE alone. Two patients received neither UAE nor methotrexate because of a low human chorionic gonadotropin (hCG) level and poor blood flow around the gestational sac (GS). An increased GS size and the elevated hCG level during methotrexate therapy might be risk factors for emergent UAE. Two of six patients treated with UAE had subsequent confirmed viable pregnancies. In patients with a cervical pregnancy, methotrexate therapy in combination with UAE can be considered as an option before performing a hysterectomy with suitable counseling about the risk of loss of fertility. Careful observation of the GS size and hCG level during methotrexate therapy might be important for management.

**Keywords:** Cervical Pregnancy; Methotrexate; Uterine Artery Embolization; Dilatation and Curettage; Human Chorionic Gonadotropin

## 1. INTRODUCTION

Cervical pregnancy is a rare but potentially life-threatening

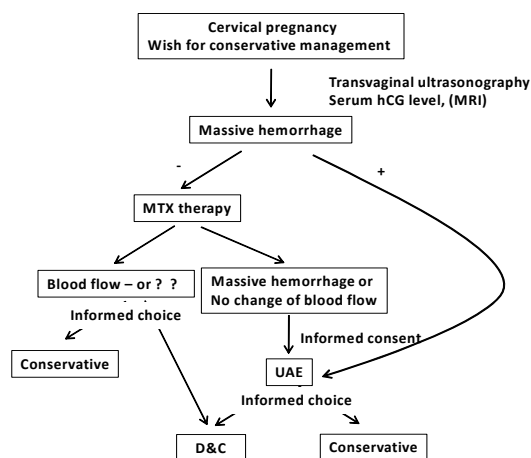
medical condition and has been reported at an incidence of 1 in 8000 - 18000 deliveries, but the incidence is increasing as a result of assisted reproductive technology [1,2]. Thus, *in vitro* fertilization and embryo transfer (IVF-ET) has been associated with an increased incidence of cervical pregnancy [3,4]. In the past, 60% of cases of cervical pregnancy were diagnosed at an advanced stage in which life-threatening hemorrhage occurred after a dilatation and curettage (D&C) or a suspected spontaneous abortion [5]. Such cases often resulted in the need for a hysterectomy and loss of the patient's fertility. The use of curettage with a Foley catheter tamponade or placement of a Shirodkar cerclage has also been reported for hemorrhage associated with a cervical pregnancy [6-9], but these procedures have not been established as safe.

Recently, the application of first-trimester transvaginal ultrasonography has led to improvements in the early diagnosis of cervical pregnancy, thereby assisting in conservative and fertility-preserving treatment [10,11]. Since Farabow *et al.* introduced systemic methotrexate (MTX) treatment for cervical pregnancy [12], MTX treatment has become an established alternative to surgical therapy [13-15]. Moreover, uterine artery embolization (UAE) has been widely used as a highly effective technique for controlling acute and chronic genital bleeding [16-18]. There have been sporadic reports of cases of cervical pregnancy with vaginal bleeding that were controlled by UAE and the administration of MTX to preserve fertility and control bleeding [19]. The risks of embolotherapy include uterine infarction or ischemia and necrosis; however, the majority of patients tolerate the procedure well [20,21]. Combined therapy with MTX has also been used and has been recommended by reports of UAE as an initial therapy to treat patients with a cervical pregnancy [22,23].

Here we report on 15 patients with a cervical pregnancy, who wished for minimally invasive intervention and/or the preservation of their fertility. We applied conservative management with MTX therapy in combination with UAE. We have examined our reports of clinical presentations, treatments and therapeutic outcomes to evaluate our conservative management for patients with a cervical pregnancy. Laboratory values and demographic information have been compared and follow-up pregnancy information has been reported, when available. The aim of this retrospective case series report is to demonstrate that systematic MTX therapy combined with UAE is a good clinical option for the conservative management of patients with a cervical pregnancy.

## 2. MATERIALS AND METHODS

Seventeen Japanese women with a suspected cervical pregnancy who were referred to the Department of Obstetrics and Gynecology, Okayama University Hospital, Japan, from 1998 to 2012 were included in this study. The study protocol was approved by the institutional review board of Okayama University Graduate School of Medicine, Dentistry and Pharmaceutical Science. Cervical pregnancies were diagnosed by transvaginal ultrasound as described previously [10]. Data were collected through paper chart reviews and through a review of electronic medical records. Clinical data and ultrasonographic findings were recorded, including maternal age, reproductive history, gestational age (GA), mean gestational sac (GS) diameter, size of the embryo, and fetal heartbeat. Our conservative management for patients who desire preservation of their fertility is outlined in **Figure 1**. Systematic MTX (50 mg/m<sup>2</sup>) was administered intramuscularly every 10 days along with a follow up of serum human chorionic gonadotropin (hCG) levels and blood flow around the GS. Ultrasound-guided injections of MTX (50 mg) into the GS



**Figure 1.** Flowchart of the conservative management for cervical pregnancy.

was also considered when there was a positive fetal heartbeat, a serum hCG level >10000 IU/L, a pregnancy of >9 gestational weeks or a fetal crown-rump length of >10 mm.

Uterine artery embolization procedures were performed by qualified interventional radiologists using gelfoam particles through the right common femoral artery access and were performed on bilateral uterine arteries in all cases. The decision to perform UAE was made on a per-case basis; however, all patients presenting with massive hemorrhage were treated in this way.

All values are expressed as the mean  $\pm$  standard deviation (SD). Demographic and laboratory data were compared using Fisher's exact test for all categorical variables and mean values were compared using the Kruskal-Wallis nonparametric analysis of variance and Mann-Whitney nonparametric U test. Statistical analysis was performed using SPSS software version 20.0 (SPSS Inc., Chicago, IL, USA) and  $P < 0.05$  was considered statistically significant.

## 3. RESULTS

Seventeen cases of cervical ectopic pregnancy were diagnosed at our institution during the study period. One patient had a heterotopic pregnancy that involved both cervical and intrauterine gestations. Another patient had no wish for conservative treatment. The remaining 15 cases were considered for the study (**Table 1**). Six of these patients were treated with UAE, and of these, five also received MTX. One patients had active vaginal bleeding 67 days after the first UAE was controlled successfully by additional UAE. The other seven patients received MTX alone. Two patients received neither UAE nor MTX because of a low hCG level and poor blood flow around the GS. Two patients with high serum hCG levels and positive fetal heartbeats also received local MTX injection into the GS together with systematic MTX administration. Forty percent of the study cases (6/15) had a history of at least one induced abortion and assisted reproduction techniques were used in eight cases including six cases of IVF-ET. Six patients were nulliparous.

All patients with a cervical pregnancy confirmed by ultrasound were admitted to our hospital for treatment. According to our management protocol for cervical pregnancy (**Figure 1**), MTX therapy was started immediately except for patients who required emergency UAE because of a massive hemorrhage. First, we divided the patients into two groups according to the median GA value (45 days) to examine whether GA affected the therapy. There was a significant difference in the serum hCG level between the two groups and all cases with massive bleeding were included in the long GA group (**Table 2(a)**). The median value of GS size (13 mm) was

**Table 1.** Characteristics of patients with a cervical pregnancy.

Case	Age	Gravida	para	artificial abortion	Infertility	GA (days)	GS (mm)	FHM	Blood flow around GS	hCG level (mIU/mL)	genital bleeding	No. of MTX	UGE	Other treatment
1	36	1	0	1	-	77	80	+	+	64030	Moderate	3	+	MTX injection, D&C
2	22	2	0	1	-	42	28	+	+	4015	Small	2	+	D&C
3	38	1	0	0	IVF-ET	48	9.9	-	±	8123	Small	2	-	-
4	40	1	0	1	IVF-ET	41	10.6	+	+	4133	Small	4	+	-
5	23	2	0	1	-	52	18	+	±	16967	-	2	-	-
6	34	0	0	0	IVF-ET	42	8.9	+	+	4665	-	2	+	Aspiration of GS
7	40	0	0	0	-	57	7.5	-	-	868	-	2	-	-
8	28	0	0	0	-	38	11.7	+	+	11271	-	2	-	MTX injection
9	32	5	1	4	-	56	10.5	-	+	9897	Heavy	0	+	-
10	40	2	1	0	AIH	51	21	+	±	16131	-	0	-	-
11	37	2	1	0	IVF-ET	52	19	-	+	41261	Heavy	3	2x	D&C
12	30	0	0	0	-	36	17.1	-	-	6056	Moderate	2	-	-
13	41	2	0	2	Clomid	41	16	-	-	1191	Small	0	-	-
14	31	0	0	0	Clomid	38	7	-	±	2095	Small	1	-	-
15	39	0	0	0	IVF-ET	45	13	+	+	13575	small	8	-	D&C

GA: gestational age, GS: gestational sac, FHM: fetal heart movement, hCG: human chorionic gonadotropin, MTX: methotrexate, UAE: uterine artery embolization, D&C: dilatation and curettage.

**Table 2.** Comparison between groups with early and late gestational age (GA) (a), small and large gestational sac (GS) (b) and low and high serum hCG levels (c).

(a)										
GA (days)	Case number	GS(mm)	FHM	Blood flow around GS	hCG level (mIU/mL)	Massive bleeding	MTX	UAE	D&C	
<45	7	14.2 ± 7.1	4	5	4775 ± 3288	0	6	3	1	
≥45	8	22.4 ± 23.8	4	7	21357 ± 20875*	2	6	3	3	
(b)										
GS (mm)	Case number	GA (days)	FHM	Blood flow around GS	hCG level (mIU/mL)	Massive bleeding	MTX	UAE	D&C	
<13	7	45.7 ± 8.1	3	6	5864 ± 3962	1	6	3	0	
≥13	8	49.5 ± 12.5	5	6	20403 ± 21575*	1	6	3	4	
(c)										
hCG level (mIU/mL)	Case number	GA (days)	GS (mm)	FHM	Blood flow around GS	Massive bleeding	MTX	UAE	D&C	
<8123	7	42.4 ± 6.8	13.6 ± 7.5	3	4	0	6	3	1	
≥8123	8	52.4 ± 11.4*	22.9 ± 23.4	5	8*	2	6	3	3	

\*P < 0.05, mean ± SD, GA: gestational age, GS: gestational sac, FHM: fetal heart movement, hCG: human chorionic gonadotropin, MTX: methotrexate, UAE: uterine artery embolization, D&C: dilatation and curettage.

also used to divide the patients into two groups. The serum hCG level was significantly higher and all patients who required D&C were included in the large GS group (>13 mm; **Table 2(b)**). Two groups were also evaluated using the median value of hCG level (8123 mIU/mL). There were significant differences in blood flow around the GS, but there was no significant difference in the incidence of D&C and the requirement for UAE in the high hCG group (**Table 2(c)**). We also examined the patients who underwent UAE. The GS size and serum hCG level at admission in the UAE group were higher than in the group without UAE, but this was not sig-

nificant statistically because some patients with a small GS and/or low hCG level required UAE because of a moderate or massive hemorrhage (**Table 3(a)**). In addition, clinical data on when UAE was done in the UAE cases are summarized in **Table 3(b)**. All patients with emergency UAE except for two with UAE at admission for massive hemorrhage had an increased and/or large GS size and/or elevation of serum hCG levels at UAE compared with those seen at admission.

Of the six patients who underwent UAE, two subsequently had confirmed viable pregnancies. Of these, one pregnancy resulted in a preterm delivery at 31

**Table 3.** Comparison between groups with and without UAE (a) and characteristics of cases with UAE (b).

(a)									
UAE	Case number	GA (days)	GS (mm)	FHM	Blood flow around GS	hCG level (mIU/mL)	MTX	D&C	
-	9	45.1 ± 7.4 [36 - 57]	13.5 ± 4.9 [7.0 - 21.0]	4	6	8475 ± 6345 [868 - 16967]	7	1	
+	6	51.7 ± 13.9 [41 - 77]	26.2 ± 27.3 [8.9 - 80.0]	4	6	21334 ± 25395 [4015 - 64030]	5	3	

(b)						
Case	GS (mm)	FHM	Blood flow around GS	hCG level (mIU/mL)	Bleeding situation	
1	80/58	+/-	+/-	64030/25	at D&C after MTX 3 courses	
2	28/64	+/-	+/+	4015/422	at D&C after MTX 2 courses	
4	11/13	+/-	+/+	4133/16055	after MTX 1 course	
6	9/50	+/-	+/+	4665/1708	after MTX 2 courses	
10	10	-	+	9897	at admission	
12	19/12	-	+	41261/122	at admission and after MTX 3 courses	

GA: gestational age, GS: gestational sac, FHM: fetal heart movement, hCG: human chorionic gonadotropin, MTX: methotrexate, UAE: uterine artery embolization, D&C: dilatation and curettage, GS size: at admission/at UAE.

weeks' gestation because of preterm labor and premature rupture of membranes and the other patient had a spontaneous vaginal term delivery with placenta accreta. None of the patients required hysterectomy.

#### 4. DISCUSSION

In this study, we analyzed the outcomes for 15 patients with a cervical pregnancy who wished for minimally invasive treatment to preserve their fertility under our protocol of conservative management for cervical pregnancy (**Figure 1**). Of this series, 12 patients received systemic MTX administration including seven with MTX alone and five were also treated with UAE. The other patient was treated with UAE alone. Two patients received neither UAE nor MTX because of a low hCG level and poor blood flow around the GS. Forty percent of the study patients had a history of at least one induced abortion, and assisted reproductive techniques were used in eight cases including six cases of IVF-ET. An increased GS size and an elevated hCG level during MTX therapy might be risk factors for emergency UAE. Of the six patients who underwent UAE, two subsequently had confirmed viable pregnancies.

MTX treatment has been used successfully for treating cervical pregnancies and has become the first line therapy for stable patients [12-15]. However, additional therapies were often required for this treatment. We found here that the group of patients with a high hCG level (>8123 mIU/mL) included all with a massive hemorrhage and a higher requirement for D&C, but there were no significant differences in the requirement for UAE. This elevated hCG level is consistent with a previous report [24]. Another report indicated that UAE

should be applied after systematic MTX therapy and—if a fetal heart beat is present—lethal intraamniotic KCL injection should be considered in cases with very high hCG level (>34,000 mIU/mL) [25]. Conversely, the hCG level at admission could not predict the requirement for UAE in our study because we observed that the patients with low hCG level after MTX therapy as well as with low initial level needed emergency UAE for a moderate hemorrhage. However, most patients requiring emergency UAE had a large GS and/or elevation of serum hCG levels at UAE compared with at admission, suggesting that careful observation might be important for conservative management.

Previous reports have suggested that UAE alone may be insufficient to treat a cervical pregnancy effectively and that concurrent medical therapy might be indicated [23,25]. In our study, only one patient had a spontaneous abortion after UAE caused by a heavy hemorrhage. In all of our patients, UAE was effective in stopping active vaginal bleeding and preserving the uterus as reported previously [17,18,26]. However, one of our patients had active vaginal bleeding 67 days after the first UAE; this was controlled successfully by additional UAE and emergency D&C of the cervical canal after the second UAE.

Viable pregnancies have been reported after UAE [25,27]. In our study, two patients subsequently had viable pregnancies although assisted reproduction techniques—one of the risk factors for cervical pregnancy—were used in eight cases including six cases of IVF-ET. Despite these observations, patients seeking fertility preservation who may undergo UAE should receive adequate prior counseling according to American college of obstetrics and gynecology (ACOG) recommendations [28]. Thus, the use of UAE for cervical

pregnancy can be considered among patients desiring future childbearing, but further studies are needed to elucidate the effect of UAE on pregnancy outcomes.

## 5. CONCLUSION

In conclusion, MTX therapy in combination with UAE can be considered as an option before hysterectomy, with counseling about the risk of loss of fertility in patients with cervical pregnancy. Careful observations of GS size and hCG levels during MTX therapy might be important for management. Because more cases are being detected earlier with first-trimester ultrasonography and with the increased incidence with assisted reproductive technology, cervical pregnancy is becoming a more commonly encountered clinical situation. The use of MTX in combination with UAE for the conservative management of a cervical pregnancy in patients desiring to preserve their fertility should be considered strongly.

## REFERENCES

- [1] Parente, J.T., Ou, C.S., Levy, J. and Legatt, E. (1983) Cervical pregnancy analysis: A review and report of five cases. *Obstetrics & Gynecology*, **62**, 79-82.
- [2] Ginsburg, E.S., Frates, M.C., Rein, M.S., Fox, J.H., Hornstein, M.D. and Friedman, A.J. (1994) Early diagnosis and treatment of cervical pregnancy in an *in vitro* fertilization program. *Fertility and Sterility*, **61**, 966-969.
- [3] Bayati, J., Garcia, J.E., Dorsey, J.H. and Padilla, S.L. (1989) Combined intrauterine and cervical pregnancy from *in vitro* fertilization and embryo transfer. *Fertility and Sterility*, **51**, 725-727.
- [4] Bennett, S., Waterstone, J., Parsons, J. and Creighton, S. (1993) Two cases of cervical pregnancy following *in vitro* fertilization and embryo transfer to the lower uterine cavity. *Journal of Assisted Reproduction and Genetics*, **10**, 100-103. <http://dx.doi.org/10.1007/BF01204450>
- [5] Cunningham, F.G., Gant, N.F., Leveno, K.J., Gilstrap, L.C., Hauth, J.C. and Wenstrom, K.D. (2001) Cervical pregnancy. Williams Obstetrics. 21st Edition, McGraw-Hill, New York, 251-253.
- [6] Ratten, G.J. (1983) Cervical pregnancy treated by ligation of the descending branch of the uterine arteries: Case report. *British Journal of Obstetrics and Gynaecology*, **90**, 367-371. <http://dx.doi.org/10.1111/j.1471-0528.1983.tb08925.x>
- [7] Nelson, R.M. (1979) Bilateral internal iliac artery ligation in cervical pregnancy: Conservative of reproductive function. *American Journal of Obstetrics and Gynecology*, **134**, 145-150.
- [8] Scott, J.W., Diggory, P.L. and Edelman, P.J. (1978) Management of cervical pregnancy with circumssuture and intracervical obturator. *British Medical Journal*, **1**, 825. <http://dx.doi.org/10.1136/bmj.1.6116.825>
- [9] Nolan, T.E., Chandler, P.E., Hess, L.W. and Morrison, J.C. (1989) Cervical pregnancy managed by placement of a shirodkar cerclage before evacuation: A case report. *Journal of Reproductive Medicine*, **34**, 69-70.
- [10] Raskin, M.M. (1978) Diagnosis of cervical pregnancy by ultrasound: A case report. *American Journal of Obstetrics and Gynecology*, **130**, 234-235.
- [11] Kung, F.T., Chang, S.Y., Tsai, Y.C., Hwang, F.R., Hsu, T.Y. and Soong, Y.K. (1997) Subsequent reproduction and obstetric outcome after methotrexate treatment of cervical pregnancy: A review of original literature and international collaborative follow-up. *Human Reproduction*, **12**, 591-595. <http://dx.doi.org/10.1093/humrep/12.3.591>
- [12] Farabow, W.S., Fulton, J.W., Fletcher, V., Velat, C.A. and White, J.T. (1983) Cervical pregnancy treated with methotrexate. *North Carolina Medical Journal*, **44**, 91-93.
- [13] Bakri, Y.N. and Badawi A. (1990) Cervical pregnancy successfully treated with chemotherapy. *Acta Obstetrical and Gynecological Scandinavia*, **69**, 655-656. <http://dx.doi.org/10.3109/00016349009028714>
- [14] Palti, Z., Rosenn, B., Goshen, R., Ben-Chitrit, A. and Yagel, S. (1989) Successful treatment of a viable cervical pregnancy with methotrexate. *American Journal of Obstetrics and Gynecology*, **161**, 1147-1148. [http://dx.doi.org/10.1016/0002-9378\(89\)90653-4](http://dx.doi.org/10.1016/0002-9378(89)90653-4)
- [15] Stovall, T.G., Ling, F.W., Smith, W.C., Felker, R., Rasco, B.J. and Buster, J.E. (1988) Successful nonsurgical treatment of cervical pregnancy with methotrexate. *Fertility and Sterility*, **50**, 672-674.
- [16] Vedantham, S., Goodwin, S.C., McLucas, B., Mohr, G. (1997) Uterine artery embolization: An underused method of controlling pelvic hemorrhage. *American Journal of Obstetrics and Gynecology*, **176**, 938-948. [http://dx.doi.org/10.1016/S0002-9378\(97\)70624-0](http://dx.doi.org/10.1016/S0002-9378(97)70624-0)
- [17] Suzumori, N., Katano, K., Sato, T., Okada, J., Nakanishi, T. and Muto, D. (2003) Conservative treatment by angiographic artery embolization of an 11-week cervical pregnancy after a period of heavy bleeding. *Fertility and Sterility*, **80**, 617-619. [http://dx.doi.org/10.1016/S0015-0282\(03\)00740-4](http://dx.doi.org/10.1016/S0015-0282(03)00740-4)
- [18] Nappi, C., D'Elia, A., Di Carlo, C., Giordano, E., De Placido, G. and Iaccarino, V. (1999) Conservative treatment by angiographic uterine artery embolization of a 12 week cervical ectopic pregnancy. *Human Reproduction*, **14**, 1118-1121. <http://dx.doi.org/10.1093/humrep/14.4.1118>
- [19] Lobel, S.M., Meyerovitz, M.F., Benson, C.C., Goff, B. and Bengtson, J.M. (1990) Preoperative angiographic uterine artery embolization in the management of cervical pregnancy. *Obstetrics & Gynecology*, **76**, 938-941. <http://dx.doi.org/10.1097/00006250-199011001-00017>
- [20] Godfrey, C.D. and Zbella, E.A. (2001) Uterine necrosis after uterine artery embolization for leiomyoma. *Obstetrics & Gynecology*, **98**, 950-952. [http://dx.doi.org/10.1016/S0029-7844\(01\)01483-1](http://dx.doi.org/10.1016/S0029-7844(01)01483-1)
- [21] Pron, G., Bennett, J., Common, A., Sniderman, K., Asch, M., Bell, S., Kozak, R., Vanderburgh, L., Garvin, G., Simons, M., Tran, C., Kachura, J. and Ontario UFE Collaborative Group. (2003) Technical results and effects of operator experience on uterine artery embolization for fi-

- broids: The Ontario Uterine Fibroid Embolization Trial. *Journal of Vascular and Interventional Radiology*, **14**, 545-554.
- [22] Cosin, J.A., Bean, M., Grow, D. and Wiczzyk, H. (1997) The use of methotrexate and arterial embolization to avoid surgery in a case of cervical pregnancy. *Fertility and Sterility*, **67**, 1169-1171. [http://dx.doi.org/10.1016/S0015-0282\(97\)81459-8](http://dx.doi.org/10.1016/S0015-0282(97)81459-8)
- [23] Trambert, J.J., Einstein, M.H., Banks, E., Frost, A. and Goldberg, G.L. (2005) Uterine artery embolization in the management of vaginal bleeding from cervical pregnancy: A case series. *Journal of Reproductive Medicine*, **50**, 844-850.
- [24] Hung, T.H., Shau, W.Y., Hsieh, T.T., Hsu, J.J., Soong, Y.K. and Jeng, C.J. (1998) Prognostic factors for an unsatisfactory primary methotrexate treatment of cervical pregnancy: A quantitative review. *Human Reproduction*, **13**, 2636-2642. <http://dx.doi.org/10.1093/humrep/13.9.2636>
- [25] Zakaria, M.A., Abdallah, M.E., Shavell, V.I., Berman, J.M., Diamond, M.P. and Kmak, D.C. (2011) Conservative management of cervical ectopic pregnancy: Utility of uterine artery embolization. *Fertility and Sterility*, **95**, 872- 876. <http://dx.doi.org/10.1016/j.fertnstert.2010.12.024>
- [26] Xu, B., Wang, Y.K., Zhang, Y.H., Wang, S., Yang, L. and Dai, S.Z. (2007) Angiographic uterine artery embolization followed by immediate curettage: An efficient treatment for controlling heavy bleeding and avoiding recurrent bleeding in cervical pregnancy. *Journal of Obstetrics and Gynecology Research*, **33**, 190-194. <http://dx.doi.org/10.1111/j.1447-0756.2007.00512.x>
- [27] Firouznia, K., Ghanaati, H., Sanaati, M., Jalali, A.H. and Shakiba, M. (2009) Pregnancy after uterine artery embolization for symptomatic fibroids: A series of 15 pregnancies. *American Journal of Roentgenology*, **192**, 1588-1592. <http://dx.doi.org/10.2214/AJR.07.3904>
- [28] ACOG Committee Opinion, (2004) Uterine artery embolization. Committee on Gynecologic Practice, American College of Obstetricians and Gynecologists. *Obstetrics & Gynecology*, **103**, 403-404.