

# Dermoid Ovarian Cyst Complicated with Torsion in a Girl of 11 Years Old at the Teaching Hospital Sanou Souro of Bobo-Dioulasso (Burkina Faso): About an Observation and Review of the Literature

Bambara Moussa<sup>1</sup>, Yameogo Relwende Barnabe<sup>2</sup>, Konsegre Valentin<sup>3</sup>,  
Baradandikanya Jean Luc<sup>1</sup>, Nikiema Zakari<sup>4</sup>, Nacro Boubacar<sup>5</sup>

<sup>1</sup>Department of Obstetric and Gynecology, University Joseph Ki Zerbo, CHUSS, Bobo-Dioulasso, Burkina Faso

<sup>2</sup>Department of Obstetric, University Joseph Ki Zerbo, CHUSS, Bobo-Dioulasso, Burkina Faso

<sup>3</sup>Pathological Anatomy, University Nazi Boni, CHUSS, Bobo-Dioulasso, Burkina Faso

<sup>4</sup>Department of Radiology and Imaging, University Nazi Boni, CHUSS, Bobo-Dioulasso, Burkina Faso

<sup>5</sup>Pediatric Department, University Joseph Ki Zerbo, CHUSS, Bobo-Dioulasso, Burkina Faso

Email: mousbambara@yahoo.fr

**How to cite this paper:** Moussa, B., Barnabe, Y.R., Valentin, K., Luc, B.J., Zakari, N. and Boubacar, N. (2019) Dermoid Ovarian Cyst Complicated with Torsion in a Girl of 11 Years Old at the Teaching Hospital Sanou Souro of Bobo-Dioulasso (Burkina Faso): About an Observation and Review of the Literature. *Open Journal of Obstetrics and Gynecology*, 9, 691-697.  
<https://doi.org/10.4236/ojog.2019.95068>

**Received:** March 13, 2019

**Accepted:** May 20, 2019

**Published:** May 23, 2019

Copyright © 2019 by author(s) and Scientific Research Publishing Inc. This work is licensed under the Creative Commons Attribution International License (CC BY 4.0).

<http://creativecommons.org/licenses/by/4.0/>



Open Access

---

## Abstract

The dermoid ovarian is an organic mild tumor. It can be revealed by an adnexal torsion which constitutes a gynecological emergency that can bring into play in a short term after the functional prognosis. We are reporting an observed case in an 11-year-old teenager who is in times peri-pubertal. The patient was presenting a painful abdomino-pelvic syndrome and a pelvic mass at the physical examination. The ultrasound was showing a right cyst mass with a right moderated hydronephrosis. A right adnexectomy was realized. The histological test after excision of the adnexal was showing a mature cystic teratoma of the right ovary with a congestive and edematous tubal fragment.

## Keywords

Dermoid Cyst, Adnexal Torsion, Ultrasound

---

## 1. Introduction

Cysts and ovarian tumors are rare in children and account for 1% to 2% of all childhood tumors [1] [2]. The dermoid cyst is considered to be the most com-

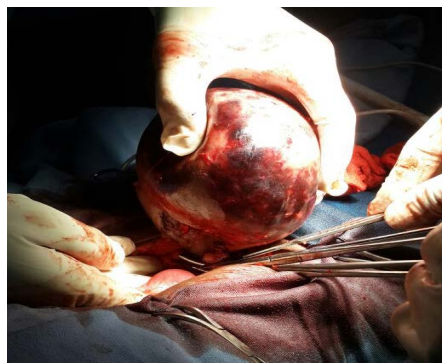mon benign organic cyst in children and adolescents [3]. It is quite often asymptomatic and discovered by chance. It is likely to be complicated by an appendix twist that is an acute abdominal emergency requiring early diagnosis in order to rescue ovarian and tubal functions. Ultrasound is a critical examination to be done urgently to assist in diagnosis. The purpose of this work is to draw the practitioner's attention to the twisting of appendix in acute abdominal emergencies of the girl and the teenager.

## 2. Our Observation

She is G. E. 11 years old admitted on 16/04/2016 to the Department of Pediatrics CHUSS Bobo-Dioulasso for painful hypogastric swelling. The onset of the disease dates back to about 10 months, marked by the appearance of a hypogastric swelling which increased in volume with a feeling of pelvic heaviness. She noticed a pain that had appeared for a week, intermittent, then continued, calmed by the anteflexion. In front of this table, she would have been driven by her parents in consultation in a peripheral structure where a treatment of unspecified nature was administered without success. Thus she was referred to the pediatric department of CHUSS on 16/04/2016 for better support. She stayed in pediatrics from 16 to 20/04/2016 with analgesic treatment with Perfalgan (390 mg every 6 hours). An abdominal and pelvic ultrasound performed revealed a cystic mass located at the upper and right lateral- upright thick-walled, echogenic content containing floating membranes (mass of  $98 \times 94 \times 88$  mm). The uterus was  $50 \times 18 \times 15$  mm and the left ovary was without abnormality. Ultrasonography revealed a right ureteric compression with moderate hydronephrosis and concluded a suspicion of torsion of the right ovarian cyst. The clinical examination of the other devices was unremarkable. Moreover, nothing was noted in his antecedents.

It is in front of this description that she was transferred on the 21/04/2016 to the CHUSS maternity ward for a better management in the face of persistent pain. The clinical examination on admission found general condition passable, vegetative and hemodynamic constants without particularity. The examination of the abdomen found a pelvic defense with a hypogastric curvature with a convex upper pole, very painful. Rectal examination was difficult by the pain and agitation of the patient. The examination of the other apparatus was without particularity.

In view of the unbearable pain and ultrasound results in favor of torsion, a laparotomy was indicated with evidence of a voluminous right ovarian cyst in torsion with the ipsilateral trunk (3 turns of turn in the direction of the needles of a watch). A right oophorectomy was performed before the necrotic appearance macroscopically (**Figure 1**). The left annex was unspecific and the wall was closed in three planes. The postoperative course was simple with a postoperative day 4 release. The macroscopic and histological study of the operative specimen found a dermoid cyst necrotic in torsion with the right trunk.



**Figure 1.** Right adnexectomy.

### 3. Discussion

#### 3.1. Epidemiology of Benign Ovarian Tumors in Children and Adolescents

Cysts and solid tumors of the ovary account for 1% to 2% of all tumors in the child [1] [2] [4] [5]. Tumors of the child's ovary are relatively rare compared to other abdominal tumors of the child. Indeed, Pellerin [6] *et al.* observed 83 ovarian tumors in 1000 abdominal tumors of the child over a period of 20 years. All types of lesions described in adult women can be found in children and adolescents [11]. Functional cysts and dermoid cysts are the most frequently encountered lesions [7] [8].

Functional cysts are cystic formations at least 3 cm in diameter developed at the expense of either an unbroken follicle or at the expense of the corpus luteum. They can reach or exceed 6 cm in diameter and are often asymptomatic and thus unknown. Risk factors for functional cysts have been reported [9]. It is about the precocity of the rules and the long and irregular cycles. These cysts usually regress spontaneously and therapeutic abstention is the rule.

Benign organic cysts: there is a great variability in benign organic cysts from either germ cells, epithelial cells, or ovarian stroma. Dermoid cyst is considered the most common organic cyst in adolescents. Its prevalence is of the order of 20% in the general population [10] and can reach 50% for ovarian tumors of the adolescent girl. The risk of malignancy increases with age and can affect 1% to 5% of cases [6]. These cysts are quite often asymptomatic and discovered by chance. They can be complicated by twisting, breaking or infection. Ultrasound allows to recognize them in the majority of the cases because of their often characteristic semeiology. The combination of ultrasound with a tumor marker (CA-19-9 and to a lesser extent CA-125) improves diagnostic performance [10]. The treatment is surgical laparotomy and at best by laparoscopic surgery with the realization of a cystectomy "with closed cyst" and extraction of the operative specimen in a protective bag. In case of cyst fluid flow into the peritoneal cavity, granulomatous peritonitis was observed in 8% of cases [11].

Epithelial cysts: they develop from the surface epithelium of the ovary. This is the classic serous cyst (serouscystadenoma) and less frequently cystadenoma

mucinous. These lesions are found more frequently in the last years of adolescence. The serous cyst is a simple unilocular cyst, difficult to differentiate from a functional cyst on ultrasound. Cystadenoma mucinous is more often multinodular and its wall is thicker. Ultrasound should look for any suspicious images such as small vegetation. The treatment of these cysts is surgical. It should be noted that malignant lesions of the ovary are rare and their prevalence varies according to published series. It is estimated that they account for only 1% of childhood and adolescent cancers [12].

### 3.2. Diagnosis

The circumstances of discovery of the dermoid cyst are multiple. Dermoid cysts are in 50% to 60% cases asymptomatic and accidentally discovered on clinical examination or during a systematic ultrasound [13]. Diagnosis can be made with chronic pelvic pain, menstrual irregularity, or complication [4] [14] [15] [16].

The development of medical imaging techniques currently allows a better approach to the nature of ovarian tumors. The X-ray of the abdomen without preparation (ASP) sometimes shows calcifications, even ossifications making it possible to evoke a dermoid cyst. Khemakhem [4] reported calcifications in 16.6% of cases in Tunisian children. The abdominopelvic ultrasound is the reference examination, performed abdominally or vaginally. It allows to specify the size of the cyst, its seat, its volume, its echostructure, the existence or not of partition, sediments, vegetations and intracystic calcifications [4] [17].

The complications of the dermoid cyst are dominated by torsion as was the case for our patient. The result is ischemia with congestion of the ovarian parenchyma and the trunk, which can lead to hemorrhagic infarction [18]. The right ovary is preferentially affected because of the freedom of the right appendix in the pelvis while the torsion mechanism on the left side is limited by the presence of the sigmoid colon [19]. Torsion can occur at any point in life, from the antenatal period to menopause. The spontaneous or iatrogenic rupture of the cyst exposes the occurrence of granular or chemical peritonitis [20]. The prevention of secondary granulomatous peritonitis requires a thorough, often long and laborious washing until a perfectly clear peritoneal fluid without debris is obtained. Regular ultrasound surveillance should be provided over the years to detect recurrence. A case of dermoid cyst fistulization in the bladder has been reported in Madagascar [16]. Infection and more rarely bleeding can complicate the development of the dermoid cyst. Malignant degeneration is observed in 0.5% to 2% of cases and is almost exclusively observed in the postmenopausal period [8].

Tumor marker determination preoperatively is essential before an ovarian mass in order to guide the etiological diagnosis and eliminate any malignant component [21]. The unavailability of this examination and the lack of means of the parents did not allow its realization.

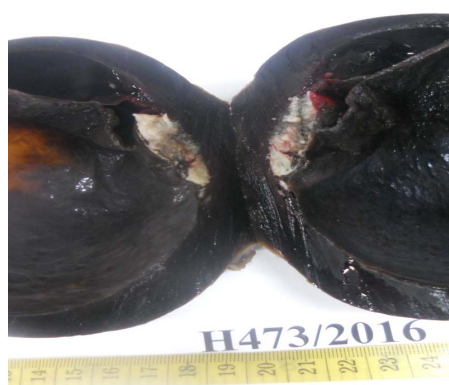Macroscopically the piece weighed 320 g and measured 12 × 11 × 10 cm with

an adjoining tubular fragment measuring 8 cm (**Figure 2**).

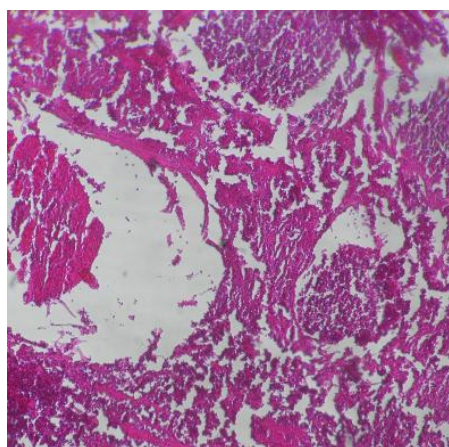
At the dissection: cystic aspect with necrotico-haemorrhagic wall, multiple partitions, with chocolate or gelatinous content. Peripheral crescent presence of a solid zone with a whitish focus of 4 cm long axis, consists of deposits of sebaceous material and hairs (**Figure 3**).

Histologically: cyst wall with haemorrhagic necrosis and lined with keratinized squamous epithelium (epidermis). In the solid zone, multiple mature tissue elements of sweat ball type, pilosebaceous follicle, adipose tissue. The tubal fragment is congestive and oedematous.

Conclusion: Cystic mature teratoma (dermoid cyst) of the right ovary with necrotic-haemorrhagic reshuffling, compatible with a torsion.



**Figure 2.** Macroscopic aspect to dissection.



**Figure 3.** Histological aspect.

### 3.3. Treatment and Prognosis

The treatment consists to do a right adnexectomy. In our patient a laparotomy by Pfannenstiel incision made it possible to perform an adnexectomy reducing the gonadal inheritance. Laparotomy is indicated in case of large volume of the cyst, with a systematic abdominopelvic exploration (uterus, contralateral ovary, dead-end of Douglas). Khemakhem [4] in his series reported an adnexectomy for

torsion in 32.35% of cases, Bougazine [22] in 48.8% of cases and Semlali [13] in 22.2% of cases. Other resources, such as operative laparoscopy or laparoscopy, are proposed as diagnostic and therapeutic means [4] [13]. These methods have a lower risk of sequelae that may affect the subsequent fertility of adolescent girls and conservative surgery of the ovary is increasingly indicated outside cases of suspicious tumors or irreversible necrosis. In the case of our patient, the prognosis was good, because it has not been observed malignant tumor proliferation on parts.

#### 4. Conclusion

The dermoid cyst of the ovary is a rare tumor in children and adolescents. It is a benign tumor which mechanical accidents can be the discovered mode and the ultrasound helps the diagnosis. The adnexectomy following the torsion is at the origin of the loss of a part of the gonadic heritage.

#### Conflicts of Interest

The authors declare no conflicts of interest regarding the publication of this paper.

#### References

- [1] Battin, J., Glue, M., Audebert, A. and Nehme, K. (1987) Benign Tumors of the Ovary and Follicular Cysts in Childhood and Adolescence. *Annales de pédiatrie*, **34**, 55-62.
- [2] Demont, F., Fourquet, F., Rogers, M. and Lansac, J. (2001) Epidemiology of Apparently Benign Ovarian Cysts. *Journal de Gynécologie Obstétrique et Biologie de la Reproduction*, **30**, S8-S11.
- [3] Audebert, A. (2013) Ovarian Cyst of Adolescent. *mt Medecine de la Reproduction, Gynecologie Endocrinologie*, **15**, 378-386.
- [4] Khemakhem, R., Ben Ahmed, Y., Ben Ftina, W., Nouira, F., Charieg, A., et al. (2012) Ovarian Cysts and Tumors of in Tunisian Children. Diagnosis and Therapeutic Management. *Journal de Pédiatrie et de Puériculture*, **25**, 8-13. <https://doi.org/10.1016/j.jpp.2011.11.002>
- [5] Pienkowski, C. and Kalfa, N. (2013) Presumed Benign Ovarian Tumors of Childhood and Adolescent. *Journal de Gynécologie Obstétrique et Biologie de la Reproduction*, **42**, 833-841. <https://doi.org/10.1016/j.jgyn.2013.09.037>
- [6] Pellerin, D., Niboul-Fikete, C., Mozziconacci, P. and Saudubray, J.M. (1982) Tumors of the Ovary. In: *Pédiatrie*, Flammarion Medicine Sciences, Paris, 96-97.
- [7] Parazini, F., Moroni, S., Negri, E., La Vecchia, C., Mezzopane, R. and Crosignani, P.G. (1997) Risk Factors for Functional Ovarian Cyst. *Journal of Epidemiology and Community Health*, **51**, 449-452. <https://doi.org/10.1136/jech.51.4.449>
- [8] Peterson, W.F., Prevost, E.C., Edmunds, F.T., Mason Hundley, J. and Morris, F.K. (1957) Benign Cyst Teratoma of the Ovary. Aclinico-Statistical Study of 1007 Cases with Review of the Literature. *American Journal of Obstetrics & Gynecology*, **72**, 1094-1102.
- [9] Kido, A., Togashi, K., Kinochi, I., et al. (1999) Dermoid Cysts of the Ovary with Malignant Transformation: MR Appearance. *American Journal of Roentgenology*,

- 172, 445-449. <https://doi.org/10.2214/ajr.172.2.9930800>
- [10] Var, T., Tonguc, E.A., Ugur, M., Altinbas, A. and Tokmak, A. (2012) Tumor Markers Panel and Tumor Size of Ovarian Dermoid Tumors in Reproductive Age. *Bratislava Medical Journal*, **113**, 95-98. [https://doi.org/10.4149/BLL\\_2012\\_022](https://doi.org/10.4149/BLL_2012_022)
- [11] Kondo, W., Bourdel, N., Cotte, B., et al. (2010) Does Prevention of Intraoperative Spillage When Removing a Dermoid Cyst Prevent Granulomatous Peritonitis? *BJOG: An International Journal of Obstetrics & Gynaecology*, **117**, 1027-1030. <https://doi.org/10.1111/j.1471-0528.2010.02580.x>
- [12] Pfeifer, S.M. and Gosman, G.G. (1999) Evaluation of Adnexal Masses in Adolescents. *Pediatric Clinics of North America*, **46**, 573-592. [https://doi.org/10.1016/S0031-3955\(05\)70138-3](https://doi.org/10.1016/S0031-3955(05)70138-3)
- [13] Semlali, S., Atmane, M., Chellaoui, M., Cat, L., Achaban, F., Alami, D., Najid, A., Etteybi, F. and Dafari, R. (2004) Emergency Ultrasound Diagnosis of Ovarian Torsion in Children: About Nine Observations. *Archives de Pédiatrie*, **11**, 304-307. <https://doi.org/10.1016/j.arcped.2004.01.001>
- [14] M'pamba Loufoua-Lemay, A.B., Peko, J.F., Mbongo, M.B., Mokoko, J.C. and Nzinguola, S. (2003) Ovarian Torsion Revealing an Ovarian Cavernous Hemangioma in a Child. *Archives de Pédiatrie*, **10**, 986-988. <https://doi.org/10.1016/j.arcped.2003.08.007>
- [15] Punga-Maole, M.L.A., Mwepu, I., Akele-Punga, C., Mbongo, B. and Ntoto, C. (2005) Twisted Ovarian Dermoid Cyst, Cause of Acute Urinary Retention in the Girl Child. *Black African Medicine*, **52**, 35-38.
- [16] Rantomalala, H.Y.H., Raveloson, J.R., Rakotoarisoa, B., Rabesata, O.J., Tovone, X.G. (2003) Bladderfistulization of a Dermoid Cyst of the Ovary. *Urology Annals*, **37**, 102-104.
- [17] Stark, J.E. and Siegel, J. (1994) Ovarian Torsion in Prepubertal and Pubertal Girls: Sonographic Finding. *American Journal of Roentgenology*, **163**, 1479-1482. <https://doi.org/10.2214/ajr.163.6.7992751>
- [18] Rha, S.E., Byun, J.Y., Jung, S.E., Jung, J.I., Choi, B.G., King, B.S., et al. (2002) CT and MR Imaging Features of Adnexal Torsion. *RadioGraphics*, **22**, 283-294. <https://doi.org/10.1148/radiographics.22.2.g02mr02283>
- [19] Rizk, D., Lakshminarasimba, B. and Joshi, S. (2002) Torsion of the Fallopian Tube in a Female Adolescent: A Case Report. *Journal of Pediatric & Adolescent Gynecology*, **15**, 159-161. [https://doi.org/10.1016/S1083-3188\(02\)00149-3](https://doi.org/10.1016/S1083-3188(02)00149-3)
- [20] Rubod, C., Triboulet, J.P. and Vinatier, D. (2007) Ovarian Dermoid Cyst Complicated by Chemical Peritonitis. Case Report. *Gynécologie Obstétrique & Fertilité*, **35**, 651-653. <https://doi.org/10.1016/j.gyobfe.2006.12.028>
- [21] Martelli, H. and Paw, C. (2003) Gonadal Tumors in Children. *Archives de Pédiatrie*, **10**, 246-250. [https://doi.org/10.1016/S0929-693X\(03\)00038-1](https://doi.org/10.1016/S0929-693X(03)00038-1)
- [22] Bougazine, S., Bibi, H., Farhat, S., Dhifallah, S., Darraji, F., Hidar, S., Lassoued, L., Chaieb, A. and Khairi, H. (2003) Adnexal Torsion: About 135 Cases. Clinical and Therapeutic Aspects. *Journal de Gynécologie Obstétrique et Biologie de la Reproduction*, **32**, 535-540.