

A Case Report of Intestinal Myiasis in a Japanese Man

Naoki Watanabe¹, Tomohiro Kato², Yoshie Ichiyanagi³, Yuko Kubota³, Shigeyuki Sugie⁴, Teruki Kadosaka⁵, Takafumi Naiki², Takuji Tanaka^{1*}

¹Department of Diagnostic Pathology (DDP) & Research Center of Diagnostic Pathology (RC-DiP), Gifu Municipal Hospital, Gifu, Japan

²Department of Gastroenterology, Gifu Municipal Hospital, Gifu, Japan

³Department of Central Laboratory, Gifu Municipal Hospital, Gifu, Japan

⁴Department of Pathology, Murakami Memorial Hospital, School of Dentistry, Asahi University, Gifu, Japan

⁵Department of Microbiology and Immunology, School of Medicine, Aichi Medical University, Nagakute, Japan

Email: *takutt@gmhosp.gifu.gifu.jp

How to cite this paper: Watanabe, N., Kato, T., Ichiyanagi, Y., Kubota, Y., Sugie, S., Kadosaka, T., Naiki, T. and Tanaka, T. (2016) A Case Report of Intestinal Myiasis in a Japanese Man. *Open Journal of Pathology*, 6, 171-176.

<http://dx.doi.org/10.4236/ojpathology.2016.64020>

Received: August 20, 2016

Accepted: October 15, 2016

Published: October 18, 2016

Copyright © 2016 by authors and Scientific Research Publishing Inc.

This work is licensed under the Creative Commons Attribution International License (CC BY 4.0).

<http://creativecommons.org/licenses/by/4.0/>

<http://creativecommons.org/licenses/by/4.0/>



Open Access

Abstract

We recently experienced a case of intestinal myiasis caused by maggots of fly, *Sarcophagidae*. A 61-year-old Japanese man presented in August 2015 with a 2-day history of diarrhea and white maggots in his stool. Two days before his presentation, he took Chinese noodles and lettuce. At his presentation, we observed a number of discharged insect bodies in his stool. The insect bodies were identified as the larvae of the 3rd instar flesh fly *Sarcophagidae* based on macroscopic and microscopic examinations. We finally diagnosed as intestinal myiasis due to the fact that the patient had the insect bodies mixed in his diet, lettuce. A few days after the treatment with antibiotics, his symptoms disappeared. Accurate diagnosis of intestinal myiasis in developed countries is necessary to avoid ineffective treatment.

Keywords

Intestinal Myiasis, Maggots, Fresh Fly, *Sarcophagidae*, Stool

1. Introduction

In 1840, the Reverend Frederick William Hope first coined the term “myiasis” to refer to diseases resulting from dipterous larvae [1] [2]. Hope [3] described several cases of myiasis from Jamaica caused by unknown larvae, one of which resulted in death. Myiasis is an infection by a fly maggot in the living or necrotic tissues of vertebrae [4]. This is different from those caused by other insect larvae.

Myiasis occurs in several tissues, such as skin, nasopharynx, digestive tract, ear canal,

vagina, urinary tract, and wound (traumatic or operative) [4]-[7]. Depending on the behavior, there are facultative and obligatory myiases. Frequently reported cases are from tropical countries and the most common infestation is by *Cordylobia anthropophaga* from Africa or *Dermatobia hominis* from South America [5] [8]. Based on an elegant review by Sueyoshi [9] in 2015, a total of 209 cases of facultative myiases have been reported in Japan. As to intestinal myiasis in Japan, more than 60 cases have been reported since 1900, and the number of cases has been reduced because of the improvement of nutritional and sanitary conditions. This rare disease, intestinal myiasis, is considered to be mainly caused by oral ingestion of the insect bodies. The symptoms disappear with excretion of worms by conservative medical treatment. The disease is therefore passed without aware of the insect bodies in food or stool. We report here this rare case with a review of the literature. This case report deals with the laboratory diagnosis of intestinal myiasis by macroscopic and microscopic observation of the larvae of the 3rd instar flesh fly *Sarcophagidae* in the stool.

2. Case Report

2.1. Case Presentation

A 61-year-old Japanese man who had a past medical history of type 2 diabetes mellitus and high blood pressure visited our hospital in August 2015, because of diarrhea and white worms (10 mm length) in his stool. Two days before his presentation, he took Chinese noodles and raw vegetables, including lettuce. At his presentation, we observed a number of discharged insect bodies in his stool. His physical, hematological, biochemical, urinary, and abdominal X-ray examinations were within normal limits. Insect bodies were not found in stools of his family, Microscopic examination of the discharged insect bodies in his stool revealed that the insect bodies were larvae of the 3rd instar flesh (*Sarcophagi*) fly. We finally diagnosed as intestinal myiasis due to the fact that the patient had lettuce in his diet containing the insect bodies. A few days after the treatment with an antibiotic (levofloxacin), his symptoms disappeared and worms were not observed in his stool during a year of follow-up.

2.2. Identification of the Insect Bodies in the Stool

The maggots were picked up from the stool specimen, washed in physiological saline and fixed in 10% buffered formalin. Macroscopic examination before fixation revealed small, white, segmented worm-like outward appearance about 10 mm length (**Figure 1**). The worms were then mounted on a glass slide and examined carefully under a NIKON stereomicroscope (NIKON SMZ1000, Nikon Co., Tokyo, Japan) and photographed by a microscope (OLYMPUS BX51, Olympus Co., Tokyo, Japan) with digital camera (DP40, Olympus Co.). Microscopic observation revealed that bodies of the maggots consisted of 12 apparent segments (**Figure 1**). Each segment possessed short spines at its posterior margin (**Figure 1**). It had a broader posterior end and a tapering anterior end with two oral hooks and mouth brushes (**Figure 2(a)** and **Figure 2(b)**). The posterior spiracles pit was deep, surrounded by a thick-ended ridge bearing six

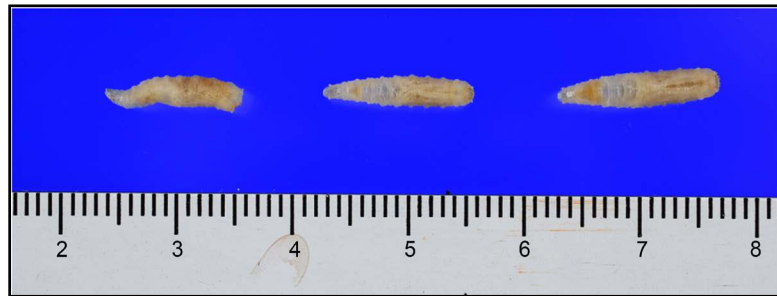


Figure 1. Macroscopic view of three intact worms (third instar) obtained from stool of *Sarcophaga* species.

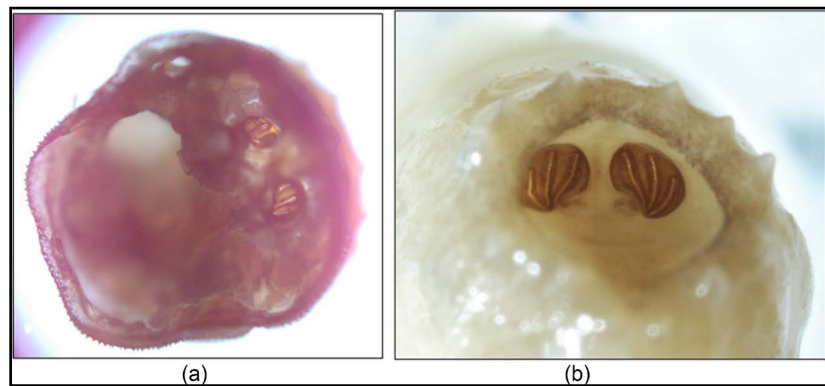


Figure 2. Stereoscopic microscopic view of posterior spiracles of the larva of *Sarcophaga* species: (a) unfixed and (b) fixed.

pairs of tubercles (three above and three below). The posterior spiracles were located inside a fossa (hidden spiracles), which is the characteristic feature of *Sarcophaga* species [10]. On the basis of the morphological examination (Figure 3), the larvae were identified as the genus *Sarcophaga*, and three parallel slits indicating the third instar larvae [11]. Cephalopharyngeal skeleton had the mouth hooks arising each from the thick base with a prominent dorsal angle and a blunt ventral process (Figure 4). The para-stomal sclerites were observed in lateral view. There had a two slender rods projecting forward from the pharyngeal sclerite over the hypostomal sclerite. Anterior spiracles (Figure 5) had short stalks and 11 - 14 branches.

3. Discussion

We report a Japanese case of intestinal myiasis. Cases of intestinal myiasis, which are described briefly in the major text books of Parasitology, have sporadically reported in Japan. More than 100 cases of intestinal myiasis in Japan have been reported during the period from 1900 to 2010 [9]. Although intestinal myiasis frequently occurs after taking rare meat, only a few cases of intestinal myiasis have recently been reported in Japan. In the present case, the fly larva was identified as the larva of *Sarcophaga peregrina* (Japanese name: senchi nikubae) on the basis of the morphological appearance of the spiracle pattern of posterior of the third instar. In Japan, this fly is commonly found as the

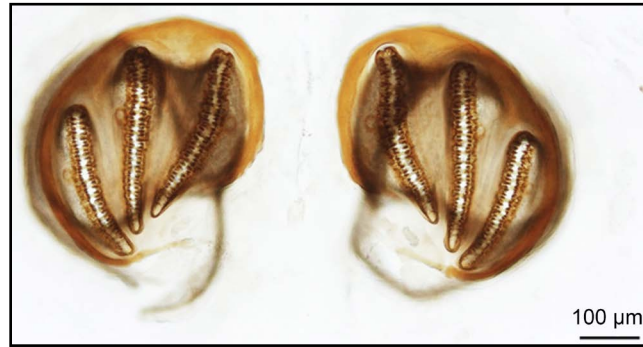


Figure 3. The posterior spiracles are surrounded by incomplete ventrally, lightly sclerotized peritreme; it is nearly straight on the mesial side, but is strongly curved or bent laterally, in addition to, the peritreme without button, also its extended between slits in upper region, the slits are not straight.

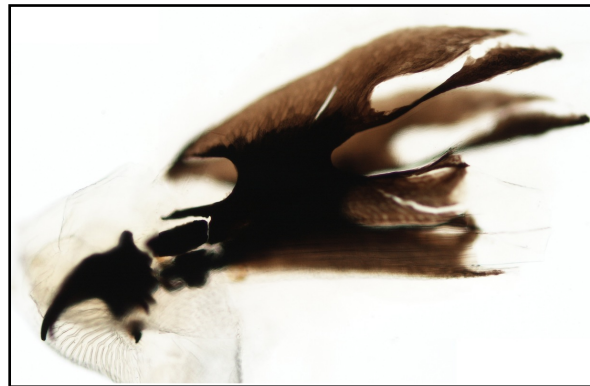

Figure 4. Cephalopharyngeal skeleton (lateral view). The mouth hooks arise each from a thick base with a prominent dorsal angle and a blunt ventral process. The rudiment of the dental sclerite is seen just behind the ventral process. The hypostomal sclerite is H-shaped as viewed dorsally. The parastomal sclerites are seen in lateral view, there have a two slender rods projecting forward from the pharyngeal sclerite over the hypostomal sclerite.

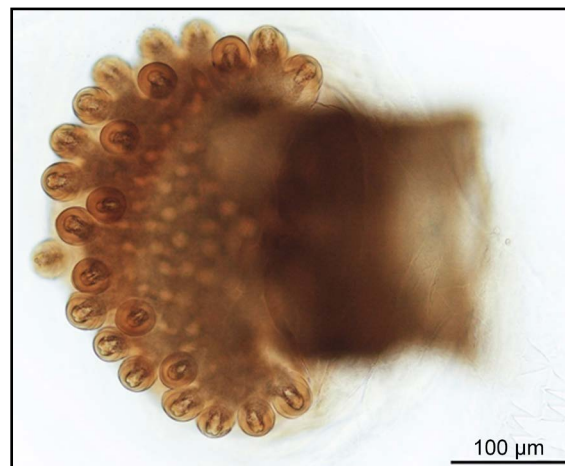


Figure 5. High power of view of sectioned anterior spiracles with short stalk and consist from 11 - 14 branches.

family background and a garbage dump [9]. Although myiasis in Japan decreases by improvement of the environmental health, various cases of myiasis, including pediatric or hospital-acquired cases, such as patients in the Intensive Care Unit (ICU), have recently been reported [12]-[15].

Myiasis of different tissues has been reported in various regions of the world. Intestinal myiasis can be improved completely with cessation of maggots in the stool. The large grayish fly belonging to the family *Sarcophagidae* has a nearly world-wide distribution [16]. Our case was caused by the *Sarcophagidae*. This is because *Sarcophaga* species are generally present in rural and urban environments and commonly found in houses and indoor dwellings.

Ingestion of uncooked food or water containing eggs and/or larvae of flies may cause accidental myiasis [4]. When ingested, most larvae are digested in the digestive tract. Clinical symptoms of intestinal myiasis vary geographically. They include asymptomatic, abdominal pain, nausea, and vomiting [15]. In the present study, the patient presented with abdominal symptoms and generalized symptoms of loss of appetite and weight. Washing vegetables before using them carefully can solve some of these problems.

Identification of the species of maggots prior to treatment is important since not all types of myiasis are benign [17]. *Sarcophaga* species are myiasis producers and their habitats make them public health suspects. They were reported to transmit some viruses, such as poliovirus, bacteria, such as *Salmonella* and *Shigella*, and protozoan cysts and helminth eggs, such as *Entamoeba histolytica*, *Giardia lamblia*, *Hymenolepis nana*, *Trichuris trichiura*, and *Ascaris lumbricoides* [1]. Present case focused on an ordinary microscope for identification of the larvae. Investigation by a scanning electron microscope is also useful for illustrating certain important features that may constitute useful criteria in the larval identification and species differentiation [18].

Oral treatment of human myiasis comes from anecdotal evidence, most from veterinary medicine. Although a semisynthetic antibiotic of the macrolide family, ivermectin, is proved to be effective against most intestinal parasites [4], including intestinal myiasis, a broad-spectrum antibiotic of the fluoroquinolone drug class, levofloxacin, is effective for our case.

References

- [1] Greenberg, B. (1971) Flies and Disease: Ecology, Classification and Biotic Associations. Princeton University Press, Princeton.
- [2] Mandell, G.L., Bennett, J.E. and Dolin, R. (2015) Principles and Practice of Infectious Diseases. Elsevier Churchill Livingstone, Philadelphia.
- [3] Hope, F.W. (1840) On Insects and Their Larvae Occasionally Found in the Human Body. *Transactions of the Entomological Society of London*, **2**, 256-271.
- [4] Francesconi, F. and Lupi, O. (2012) Myiasis. *Clinical Microbiology Reviews*, **25**, 79-105. <http://dx.doi.org/10.1128/CMR.00010-11>
- [5] Derraik, J.G., Heath, A.C. and Rademaker, M. (2010) Human Myiasis in New Zealand: Imported and Indigenously-Acquired Cases: The Species of Concern and Clinical Aspects. *The New Zealand Medical Journal*, **123**, 21-38.

- [6] Haruki, K., Hayashi, T., Kobayashi, M., Katagiri, T., Sakurai, Y. and Kitajima, T. (2005) Myiasis with *Dermatobia hominis* in a Traveler Returning from Costa Rica: Review of 33 Cases Imported from South America to Japan. *Journal of Travel Medicine*, **12**, 285-288. <http://dx.doi.org/10.2310/7060.2005.12509>
- [7] Safdar, N., Young, D.K. and Andes, D. (2003) Autochthonous Furuncular Myiasis in the United States: Case Report and Literature Review. *Clinical Infectious Diseases*, **36**, e73-e80. <http://dx.doi.org/10.1086/368183>
- [8] Sukontason, K.L., Sanit, S., Klong-Klaew, T., Tomberlin, J.K. and Sukontason, K. (2014) Sarcophaga (Liosarcophaga) dux (Diptera: Sarcophagidae): A Flesh Fly Species of Medical Importance. *Biological Research*, **47**, 14.
- [9] Sueyoshi, M. (2015) Review of the Human Myiasis in Japan. *Medical Entomology and Zoology*, **66**, 91-120. (In Japanese) <http://dx.doi.org/10.7601/mez.66.91>
- [10] Alfred, J.T. (2011) Morphological and Molecular Techniques for the Differentiation of Myiasis-Causing Sarcophagidae. Entomology Iowa State University, Ames, p. 95.
- [11] Szpila, K., Richet, R. and Pape, T. (2015) Third Instar Larvae of Flesh Flies (Diptera: Sarcophagidae) of Forensic Importance—Critical Review of Characters and Key for European Species. *Parasitology Research*, **114**, 2279-2289. <http://dx.doi.org/10.1007/s00436-015-4421-3>
- [12] Chigusa, Y., Kawakami, K., Shimada, M., Kurahashi, H. and Matsuda, H. (2006) Hospital-Acquired Oral Myiasis Due to *Boettcherisca septentrionalis* (Diptera: Sarcophagidae) in Shimane Prefecture, Japan. *Medical Entomology and Zoology*, **57**, 139-143. <http://dx.doi.org/10.7601/mez.57.139>
- [13] Chigusa, Y., Shinonaga, S., Honda, M., Kanma, W., Kakinuma, H., Kirinoki, M. and Matsuda, H. (2005) Vaginal Myiasis Due to *Sarcophaga peregrina* (Diptera: Sarcophagidae) on a Patient with Atrial Fibrillation, Cerebral Infarction and Leg Amputation. *Medical Entomology and Zoology*, **56**, 247-249. <http://dx.doi.org/10.7601/mez.56.247>
- [14] Chigusa, Y., Shinonaga, S., Kuniyoshi, T., Kirinoki, M. and Matsuda, H. (2005) Suspected Asymptomatic Alimentary Tract Myiasis Due to *Lucilia sericata* (Diptera: Calliphoridae) Occurred in a General Hospital by Commercially Delivered Lunch. *Medical Entomology and Zoology*, **56**, 243-246. <http://dx.doi.org/10.7601/mez.56.243>
- [15] Yoneda, Y., Shinonaga, S., Kumashiro, H. and Fukuma, T. (1998) Eleven Cases of Accidental Human Myiasis Since 1990. *Medical Entomology and Zoology*, **49**, 51-56. http://dx.doi.org/10.7601/mez.49.51_1
- [16] Das, A., Pandey, A., Madan, M., Asthana, A.K. and Gautam, A. (2010) Accidental Intestinal Myiasis Caused by Genus Sarcophaga. *Indian Journal of Medical Microbiology*, **28**, 176-178. <http://dx.doi.org/10.4103/0255-0857.62503>
- [17] Singh, T.S. and Rana, D. (1989) Urogenital Myiasis Caused by *Megaselia scalaris* (Diptera: Phoridae): A Case Report. *Journal of Medical Entomology*, **26**, 228-229. <http://dx.doi.org/10.1093/jmedent/26.3.228>
- [18] Ahmad, A.K., Abdel-Hafeez, E.H., Makhloof, M. and Abdel-Raheem, E.M. (2011) Gastrointestinal Myiasis by Larvae of Sarcophaga sp. and Oestrus sp. in Egypt: Report of Cases, and Endoscopic and Morphological Studies. *The Korean Journal of Parasitology*, **49**, 51-57. <http://dx.doi.org/10.3347/kjp.2011.49.1.51>



Submit or recommend next manuscript to SCIRP and we will provide best service for you:

Accepting pre-submission inquiries through Email, Facebook, LinkedIn, Twitter, etc.

A wide selection of journals (inclusive of 9 subjects, more than 200 journals)

Providing 24-hour high-quality service

User-friendly online submission system

Fair and swift peer-review system

Efficient typesetting and proofreading procedure

Display of the result of downloads and visits, as well as the number of cited articles

Maximum dissemination of your research work

Submit your manuscript at: <http://papersubmission.scirp.org/>

Or contact ojpathology@scirp.org