

Sandifer's Syndrome in a 3-Month-Old Male Infant: A Case Report

Ahmed Basal¹, Ali Aldirawi², Samer Abuzerr^{3,4*}

¹Pediatrics Department, Shaheed Mohammed Al-Durra Hospital, Ministry of Health, Gaza, Palestine

²Neonatal Intensive Care Unit, Al-Shifa Hospital, Ministry of Health, Gaza, Palestine

³Department of Environmental Health Engineering, School of Public Health, International Campus, Tehran University of Medical Sciences, Tehran, Iran

⁴Quality Improvement and Infection Control Unit, Ministry of Health, Gaza, Palestine

Email: Falcon1351971@hotmail.com, mr_ali_90@hotmail.com, *samer_516@hotmail.com

How to cite this paper: Basal, A., Aldirawi, A. and Abuzerr, S. (2019) Sandifer's Syndrome in a 3-Month-Old Male Infant: A Case Report. *Open Journal of Pediatrics*, 9, 232-238.

<https://doi.org/10.4236/ojped.2019.93022>

Received: June 4, 2019

Accepted: September 15, 2019

Published: September 18, 2019

Copyright © 2019 by author(s) and Scientific Research Publishing Inc.

This work is licensed under the Creative Commons Attribution International License (CC BY 4.0).

<http://creativecommons.org/licenses/by/4.0/>



Open Access

Abstract

Background: Sandifer syndrome (SS) is the association of gastroesophageal reflux disease (GERD) with neurological manifestations (spastic torticollis and paroxysmal dystonic postures with arching of the back and rigid opisthotonic posturing. **Case presentation:** A 3-month-old male infant presented to our emergency department with torticollis and dystonic episodes for two months associated with vomiting. These movements were observed during or just after feeding. Since the patient developed regurgitations with torticollis and dystonic episodes with arching of the back and rigid opisthotonic posturing. The electroencephalogram was normal. Barium swallow/meal examination revealed GERD without evidence of hiatus hernia. Apgar scores were 7 at 1 min and 9 at 5 min. **Conclusion:** Early recognition and treatment of GERD in patients with Sandifer syndrome enhance the success of medical management and contributes to improved quality of life for patients with brain damage. The paroxysmal dystonic behaviors were dramatically disappeared completely after medical management in this patient.

Keywords

Sandifer Syndrome, Gastroesophageal Reflux, Torticollis, Dystonic Postures

1. Background

Sandifer's syndrome (SS) is a combination of neurological manifestations (sudden abnormal spastic torticollis and dystonic body movements and dystonic movements of the head, neck, eyes and upper part of the trunk) with severe GERD [1] [2]. SS, named after the neurologist Paul Sandifer, was first reported

by M. Kinsbourne in 1962, who noticed a disorder of the neurological manifestations in association with upper gastrointestinal tract occurring mainly in children and adolescents [3]. The incidence is thought to be less than 1% of children with GERD [4]. The exact pathophysiology of the movements in SS is still unclear [5] [6]. SS may be due to GER even without hiatal hernia, macroscopic esophagitis, or reflux symptoms, neural axis abnormalities [7] and food allergy to dietary proteins of lactating mother may play a role [2] [8]. SS was seen either in patients with Brachman-de Lange syndrome [9]. SS is under recognized, and delays in diagnosis are due to atypical presentations [10]. The neurological manifestations are thought to be a response to the pain associated with GERD, to protect the airway or reduce acid reflux-associated pain [11]. SS is supported by the resolution of the manifestations on successful treatment of GERD [12].

We report a 3-months-old male patient presented to our ED with torticollis, dystonic episodes with severe arching of the back and rigid opisthotonic posturing since birth associated with vomiting. SS was suspected and the above symptoms resolved completely after medical treatment.

2. Case Presentation

A 3-month-old male infant has attended our emergency department with a history of bizarre head and neck movements (extension of the head with neck, chest with abdomen contraction and extension to the back, both upper and lower limbs arched with increased the tone, associated with irritability). The attack lasts for about 3 minutes, started since birth, not associated with loss of consciousness, eyes not fixed during the attacks, no aura or postictal state (Figure 1).

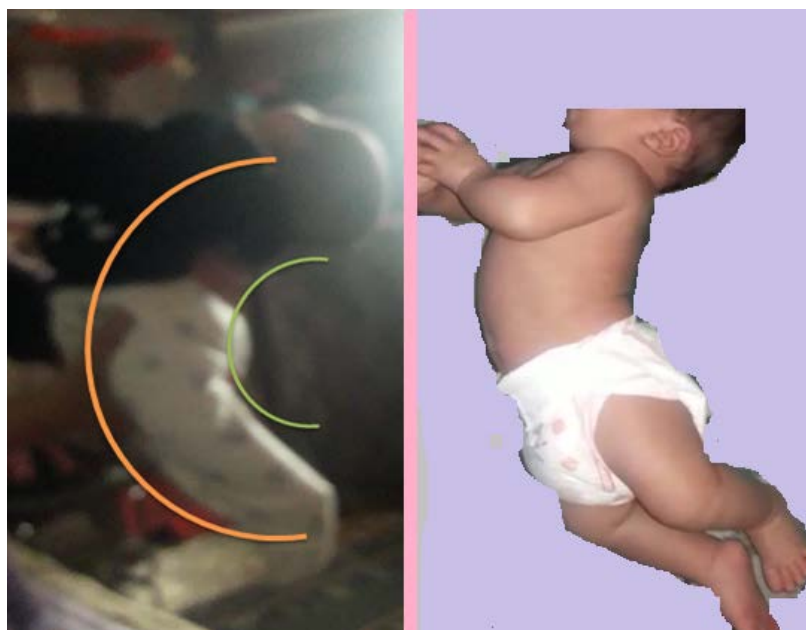

Figure 1. The attack of spasmodic torsional dystonia with arching of the back and rigid opisthotonic posturing, mainly involving the neck, back, and upper extremities.

These movements were observed during or just after feeding and associated with vomiting. The milestones of motor and mental development were normal. Physical and neurological examinations were normal. The patient is a product of normal spontaneous vaginal delivery, Apgar scores were 7 at 1 min and 9 at 5 min, birth weight was 2700 gm, actual body weight 4700 gm. Breastfeed baby and no history of physiological jaundice.

Vaccination was given by age. No history of similar conditions and no chronic illness in his family. Routine laboratory tests were normal. The patient was seen by a pediatric epilepsy clinic to exclude infantile spasm and the electroencephalogram (EEG) study was normal.

Barium swallow/meal examination revealed GER without evidence of hiatus hernia (**Figure 2**). Twenty-four hours of pH monitoring was not done, due to the lack of availability in our hospital.

Therefore, the diagnosis, in this case, was based on typical clinical features and on response to medical measures trail.

We started conservative management with feeding and posture modifications (lateral and head elevation 30 - 45 degree), small, frequent, thick special anti-regurgitation formula. After four days of these measures, the infant still owns the above attacks and vomiting. We added proton pump inhibitor (PPI) as omeprazole 1 mg/kg/day in two divided doses, after four days the mother mentioned that her baby get well and the frequency of the attacks decreased from 10 - 15 attack per day to one or two attacks per day. The above symptoms resolved completely after three weeks of treatment, we followed this patient for a total eight weeks and he was free of SS symptoms and signs completely.

3. Discussion

Sandifer syndrome is a syndrome characterized by paroxysmal dystonic posturing with opisthotonus and unusual twisting of the head and neck (resembling torticollis)

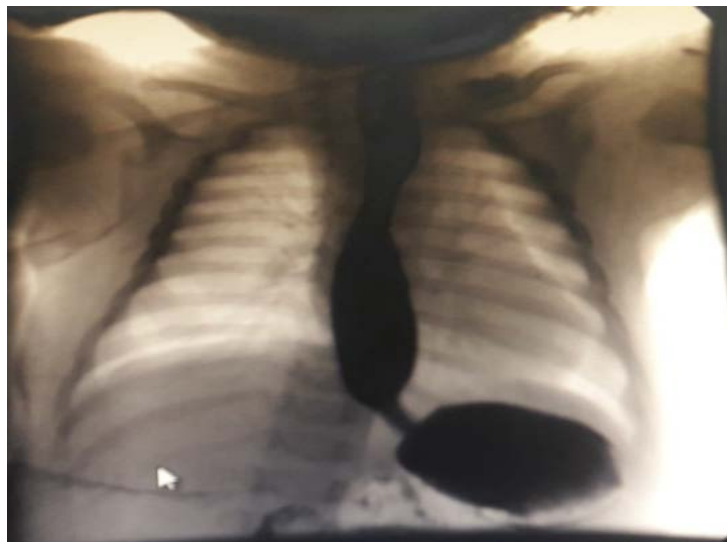


Figure 2. Barium swallow/meal examination showing GERD without evidence of hiatus hernia.

are temporally associated with GERD episodes [3] [13]. Since the description of SS in 1962, between 40 to 65 cases of SS cases have been reported in the literature, most are young, neurologically normal children, no sex predilection, and in neurologically abnormal children [2] [4] [14]-[20]. The onset usually occurs in infancy and early childhood [21], with a peak prevalence at 18 - 36 months [4]. GERD in infants may cause paroxysmal attacks of generalized stiffening and opisthotonic posturing that may be accompanied by apnea, staring, and minimal jerking of the extremities [22]. SS is a rare cause of torticollis related to hiatal hernia and approximately one case of SS occurs for every 100 children with symptomatic hiatal hernia [23]. The dystonic body movements are described as atypical seizures or abnormal body movements and take place in the paroxysmal form as attacks with irritability, head and eye version, extensor spasm, rectus abdominis muscle contractions, and dystonic posture [24]. The classical symptoms of the syndrome are spasmodic torticollis and dystonia [23]. Nodding and rotation of the head, neck extension, gurgling sounds, writhing movements of the limbs, and severe hypotonia have been reported [19] [25]. The head positioning may be a mechanism to protect the airway or reduce acid reflux [26]. The duration of the attack is about 1-3minutes [24] [26] [27]. Children with SS may have recurrent vomiting and Failure to thrive. Gastrointestinal evaluation is warranted and appropriate treatment of the reflux eliminates the episodes [28]. The differential diagnosis of SS may be confused with tonic seizures, infantile spasm, infantile torticollis, syncopal attacks [24] [29].

Early recognition and treatment of GERD in patients with SS enhances the success of medical management, is curative for patients with no other disorders, and contributes to improved quality of life for patients with brain damage [19] [30]. The majority of children with SS respond well to anti-GERD therapy, include acid suppressants (H_2 receptor antagonists, PPIs), buffers (antacids) and prokinetic [31] [32] [33] [34] associated with lifestyle changes [4]. In case of food allergy to dietary proteins ingestion, they should be removed from the diet [2] [8]. Severe GERD cases, GERD unresponsive to medical therapy and conservative management, and which is interfering with growth and development, some evidence suggests that fundoplication may alleviate symptoms [3] [6] [35].

4. Conclusion

Healthcare providers should be aware of SS when evaluating a child with torticollis, dystonic episodes or atypical seizures. Early recognition and treatment of GERD in patients with SS enhance the success of medical management, are curative for patients without other disorders, and contribute to improved quality of life for patients with brain damage. The paroxysmal dystonic behaviors were dramatically disappeared completely after medical management in this patient.

Acknowledgements

The authors express their sincere thanks to Dr. Kamal Abu Shamala for his vital

participation in the study. In addition, they are grateful to the family of the case child for providing us the better opportunity for conducting the research.

Funding

This research did not receive any specific grant from funding agencies in the public, commercial or not-for-profit sectors.

Ethics Approval and Consent to Participate

Written informed consent was obtained from the patient's parent for publication of this case report and any accompanying images. A copy of the written consent is available for review by the Editor-in-Chief of this journal.

Conflicts of Interest

The authors declare no conflicts of interest regarding the publication of this paper.

References

- [1] Nalbantoglu, B., Metin, M. and Nalbantoglu, A. (2013) Sandifer's Syndrome: A Misdiagnosed and Mysterious Disorder. *Iranian Journal of Pediatrics*, **23**, 715-716.
- [2] Corrado, G., Cavaliere, M., D'Eufemia, P., *et al.* (2001) Sandifer's Syndrome in a Breast-Fed Infant. *American Journal of Perinatology*, **17**, 147-150.
<https://doi.org/10.1055/s-2000-9285>
- [3] Lehwald, N., Krausch, M., Franke, C., *et al.* (2007) Sandifer Syndrome—A Multidisciplinary Diagnostic and Therapeutic Challenge. *European Journal of Pediatric Surgery*, **17**, 203-206. <https://doi.org/10.1055/s-2007-965145>
- [4] Moore, M. and Rizzolo, D. (2018) Sandifer Syndrome. *Journal of the American Academy of Physician Assistants*, **31**, 18-22.
<http://dx.doi.org/10.1097/01.JAA.0000531044.72598.26>
- [5] Rybak, A., Pesce, M., Thapar, N. and Borrelli, O. (2017) Gastro-Esophageal Reflux in Children. *International Journal of Molecular Sciences*, **18**, 1671.
<https://www.mdpi.com/1422-0067/18/8/1671>
- [6] Frankel, E., Shalaby, T. and Orenstein, S. (2006) Sandifer Syndrome Posturing: Relation to Abdominal Wall Contractions, Gastroesophageal Reflux, and Fundoplication. *Digestive Diseases and Sciences*, **51**, 635-640.
<https://doi.org/10.1007/s10620-006-3184-1>
- [7] Herman, M. (2006) Torticollis in Infants and Children: Common and Unusual Causes. *Instructional Course Lectures*, **55**, 647-653.
- [8] Hill, D., Murch, S., Rafferty, K., *et al.* (2007) The Efficacy of Amino Acid-Based Formulas in Relieving the Symptoms of Cow's Milk Allergy: A Systematic Review. *Clinical & Experimental Allergy*, **37**, 808-822.
<https://doi.org/10.1111/j.1365-2222.2007.02724.x>
- [9] Sommer, A. (1993) Occurrence of the Sandifer Complex in the Brachmann-de Lange Syndrome. *American Journal of Medical Genetics*, **47**, 1026-1028.
<https://doi.org/10.1002/ajmg.1320470719>
- [10] Kabakuş, N. and Kurt, A. (2006) Sandifer Syndrome: A Continuing Problem of

- Misdiagnosis. *Pediatrics International*, **48**, 622-625.
<https://doi.org/10.1111/j.1442-200X.2006.02280.x>
- [11] Cohn, A. and Reece, A. (2014) Sandifer Syndrome in Gastroesophageal Reflux in Clinical Cases in Paediatric: A Trainee Handbook. 120.
- [12] Akbayram, S., Doğan, M., Turhan, S. and Çaksen, H. (2007) Sandifer Syndrome. *European Journal of General Medicine*, **4**, 56-57.
<https://doi.org/10.29333/ejgm/82433>
- [13] Sauer, G. and Kugathasan, S. (2010) Pediatric Inflammatory Bowel Disease: Highlighting Pediatric Differences in IBD. *Medical Clinics of North America*, **94**, 35-52.
<https://doi.org/10.1016/j.mcna.2009.10.002>
- [14] Bray, P.F., Herbst, J.J., Johnson, D.G., Book, L.S., Ziter, F.A. and Condon, V.R. (1977) Childhood Gastroesophageal Reflux. Neurologic and Psychiatric Syndromes Mimicked. *JAMA*, **237**, 1342-1345. <https://doi.org/10.1001/jama.237.13.1342>
- [15] Shahnawaz, M., van der Westhuizen, L.R. and Gledhill, R.F. (2001) Episodic Cervical Dystonia Associated with Gastro-Oesophageal Reflux. A Case of Adult-Onset Sandifer Syndrome. *Clinical Neurology and Neurosurgery*, **103**, 212-215.
[https://doi.org/10.1016/S0303-8467\(01\)00145-7](https://doi.org/10.1016/S0303-8467(01)00145-7)
- [16] Somjit, S., Lee, Y., Berkovic, S.F. and Harvey, A.S. (2004) Sandifer Syndrome Misdiagnosed as Refractory Partial Seizures in an Adult. *Epileptic Disorders*, **6**, 49-50.
- [17] Olguner, M., Akgür, F.M., Hakgüder, G. and Aktuğ, T. (1999) Gastroesophageal Reflux Associated with Dystonic Movements: Sandifer's Syndrome. *Pediatrics International*, **41**, 321-322. <https://doi.org/10.1046/j.1442-200X.1999.t01-1-01051.x>
- [18] Mandel, H., Tirosh, E. and Berant, M. (1989) Sandifer Syndrome Reconsidered. *Acta Paediatrica Scandinavica*, **78**, 797-799.
<https://doi.org/10.1111/j.1651-2227.1989.tb11150.x>
- [19] Rana, A.Q., Yousuf, M.S. and Joian, S. (2013) A Chronic Case of Adult-Onset Sandifer Syndrome. *Neurological Sciences*, **34**, 405-406.
<https://doi.org/10.1007/s10072-012-1005-1>
- [20] Alam, S. and Lux, A. (2012) Epilepsies in Infancy. *Archives of Disease in Childhood*, **97**, 985-992. <https://doi.org/10.1136/archdischild-2011-301119>
- [21] Mikati, M. and Obeid, M. (2016) Sandifer Syndrome in Conditions than Mimic Seizures in Nelson Pediatric Textbook. 2857-2863.
- [22] Theodoropoulos, D.S., Lockey, R.F. and Boyce, H.W. (1999) Sandifer's Syndrome and Gastro-Oesophageal Reflux Disease. *Journal of Neurology, Neurosurgery & Psychiatry*, **66**, 805-806. <https://doi.org/10.1136/jnnp.66.6.805>
- [23] Kinsbourne, M. (1964) Hiatus Hernia with Contortions of the Neck. *The Lancet*, **1**, 1058-1061. [https://doi.org/10.1016/S0140-6736\(64\)91264-4](https://doi.org/10.1016/S0140-6736(64)91264-4)
- [24] Kaiser, G. (2005) Sandifer Syndrome in Symptoms and Signs in Pediatric Surgery. 101-114.
- [25] Nunes, V.D., Sawyer, L., Neilson, J., Sarri, G. and Cross, J.H. (2012) Diagnosis and Management of the Epilepsies in Adults and Children: Summary of Updated NICE Guidance. *BMJ*, **344**, e281. <https://doi.org/10.1136/bmj.e281>
- [26] Patel, H., Chakrabarty, B., Gulati, S., et al (2014) A Case of Congenital Myopathy Masquerading as Paroxysmal Dyskinesia. *Annals of Indian Academy of Neurology*, **17**, 441-443. <https://doi.org/10.4103/0972-2327.144034>
- [27] Cooperman, D. (2013) Sandifer Syndrome in Torticollis: Differential Diagnosis, Assessment and Treatment, Surgical Management and Bracing.

- [28] Turner, R. (2009) Sandifer's Syndrome in Paroxysmal/Non-Epileptic Disorders of Childhood in Current Management in Child Neurology. 172-179.
- [29] Marr, J. and Okada, P. (2008) Sandifer Syndrome in Pediatric Emergency Medicine.
- [30] Taddio, A., Bersanini, C., Basile, L., *et al.* (2011) Gastroesophageal Reflux Disease at Any Cost: A Dangerous Paediatric Attitude. *Acta Paediatrica*, **100**, E178-E180. <https://doi.org/10.1111/j.1651-2227.2011.02315.x>
- [31] Sondheimer, J. and Morris, B.A. (1979) Gastroesophageal Reflux among Severely Retarded Children. *The Journal of Pediatrics*, **94**, 710-714. [https://doi.org/10.1016/S0022-3476\(79\)80135-3](https://doi.org/10.1016/S0022-3476(79)80135-3)
- [32] Ward, R. and Kearns, G. (2013) Proton Pump Inhibitors in Pediatrics: Mechanism of Action, Pharmacokinetics, Pharmacogenetics, and Pharmacodynamics. *Pediatric Drugs*, **15**, 119-131. <https://doi.org/10.1007/s40272-013-0012-x>
- [33] Tighe, M., Afzal, N.A., Bevan, A., Munro, A. and Beattie, R.M. (2014) Pharmacologic Treatment of Children with Gastroesophageal Reflux. *Cochrane Database of Systematic Reviews*, No. 11, 1-83. <https://doi.org/10.1002/14651858.CD008550.pub2>
- [34] Bamji, N., Berezin, S., Bostwick, H. and Medow, M. (2015) Treatment of Sandifer Syndrome with an Amino-Acid-Based Formula. *AJP Reports*, **5**, e51-e52.
- [35] Van der Pol, R.J., Smits, M.J., Van Wijk, M.P., *et al.* (2011) Efficacy of Proton-Pump Inhibitors in Children with Gastroesophageal Reflux Disease: A Systemic Review. *Pediatrics*, **127**, 925. <https://doi.org/10.1542/peds.2010-2719>