

Arch Reconstruction in Hypoplastic Left Heart Syndrome: Handling the Diminutive Aorta

Francisco J. Boyle*, Frank A. Pigula

Department of Cardiac Surgery, Children's Hospital Boston, Harvard University Medical School, Boston, USA
Email: *fboyecvs@icloud.com

Received August 12, 2013; revised September 12, 2013; accepted September 20, 2013

Copyright © 2013 Francisco J. Boyle, Frank A. Pigula. This is an open access article distributed under the Creative Commons Attribution License, which permits unrestricted use, distribution, and reproduction in any medium, provided the original work is properly cited.

ABSTRACT

The diminutive aorta presents technical challenges in the palliation of hypoplastic left heart syndrome. Furthermore, aortic arch caliber changes and variable great vessel relationships can add complexity to an already difficult arch repair. We describe a technical approach that simplifies the aortic reconstruction and makes the procedure more generalizable and reproducible.

Keywords: Arch; Hypoplastic; Reconstruction; Norwood; Technique

1. Introduction

Hypoplastic Left Heart Syndrome (HLHS) is a spectrum of cardiac malformations that has a high morbidity and mortality. HLHS is comprised of underdeveloped left sided heart structures, characterized by aortic atresia or severe stenosis, which results in a small left ventricle and a hypoplastic, sometimes diminutive ascending aorta [1]. Without surgical intervention, one-month mortality approaches 95% [2].

The Norwood procedure is one of the most technically challenging surgical interventions and remains a high risk operation [3]. The arch reconstruction technique in such patients can be quite demanding, and achieving an adequate three dimensional conformation of all components (ascending aorta, aortic arch, proximal descending aorta and pulmonary root), coupled to the homograft patch can be difficult. Furthermore, the aortic reconstruction impacts not only coronary perfusion, but the adequacy of the distal arch and the neo-aortic valve as well. Because of this, we describe a simple, reproducible technique that simplifies the surgical approach to the diminutive aorta in patients with hypoplastic left heart syndrome.

2. Technique

Following a median sternotomy, cardiopulmonary bypass is instituted with a single arterial cannula placed into the

brachiocephalic artery, through a 3.5 mm Gore-Tex tube graft (Gore-Tex; W. L. Gore and Associates, Flagstaff, AZ), and a single venous cannula into the right atrium through the appendage. Pulmonary blood flow is controlled by temporary occlusion of the pulmonary artery branches. While cooling down to 18°C, the aorta and main pulmonary artery (MPA) are fully mobilized.

Under standard low-flow regional perfusion, the neck vessels are temporarily occluded; an antegrade dose of cardioplegia is administered through the arterial cannula itself and the ductus arteriosus is divided. Then, the atrial septum is resected, through the right atrial appendage cannulation site, leaving an unrestrictive atrial septal defect.

The MPA is transected at the bifurcation, followed by division of the aorta just above the level of the MPA root. The aortic ductal stump is then amputated and the aorta is opened along the inner curvature. When present, the coarctation shelf is resected and an anastomosis along the greater curvature of the descending aorta (with or without interdigitation) is performed. A suitable homograft triangular patch is then fashioned and used to reconstruct the aortic arch (**Figures 1(b)** and **(c)**). Once complete, the arch reconstruction creates a tubular, symmetrical and funnel-shaped structure (**Figure 1(d)**).

Following the arch reconstruction, the proximal aortocoronary to pulmonary anastomosis is performed, using vertical counter-incisions in both great vessels (**Figure 1(d)**). Of note, the aortocoronary stump should be taller

*Corresponding author.

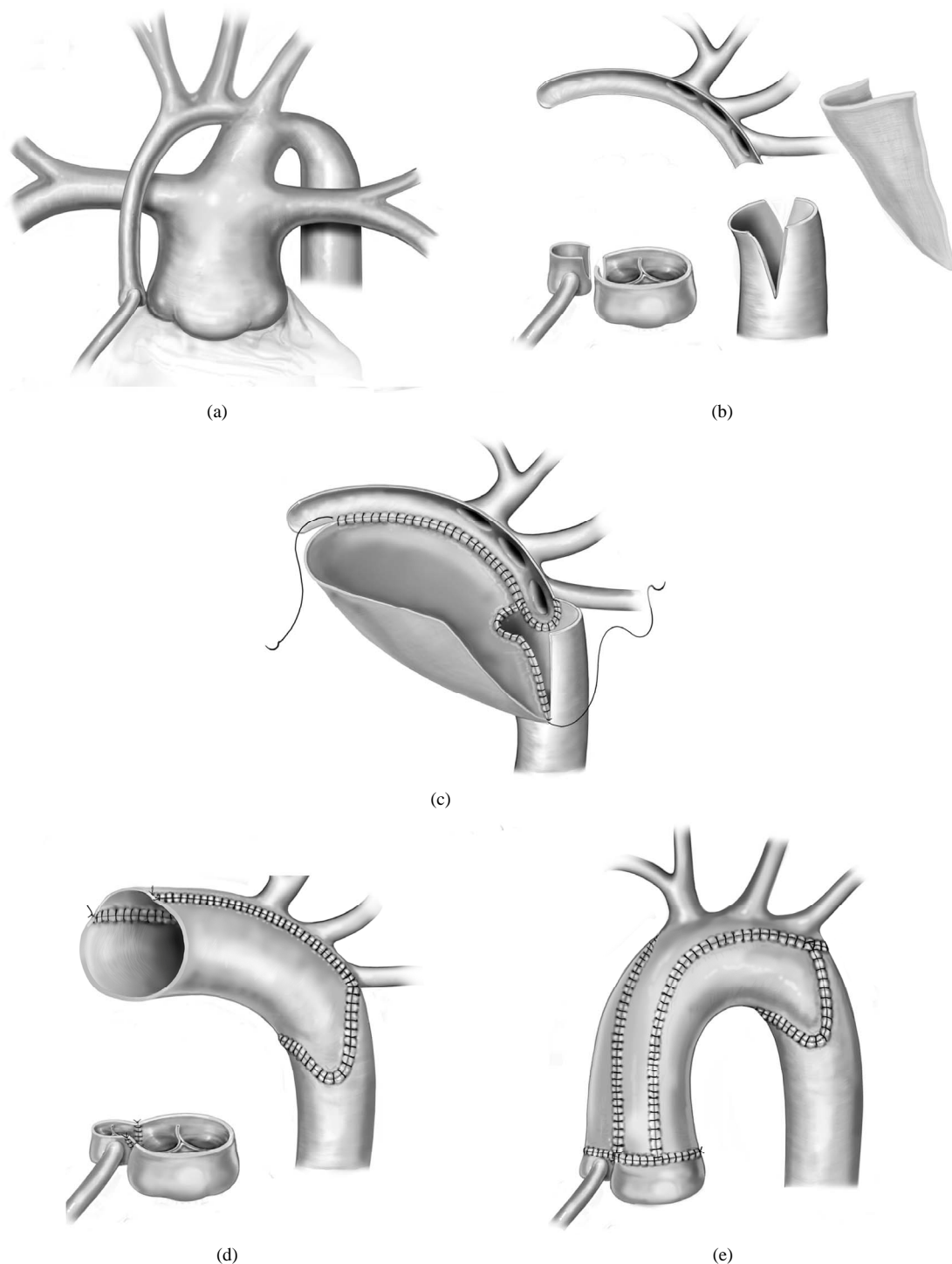


Figure 1. Surgical technique to handle the diminutive aorta in Hypoplastic Left Heart Syndrome. (a) Great vessels anatomy in hypoplastic left heart syndrome: There is a diminutive ascending aorta and aortic arch, a large ductus is taking off from the pulmonary artery, usually the pulmonary artery branches are adequate in size. The coronary arteries are comparable in size to the ascending aorta; (b) Both great vessels are transected above the sinotubular junction and vertical counter-incisions are made in both roots. The ductal tissue and coarctation shelf are resected, the ascending aorta and aortic arch are opened along the inner curvature. The descending aorta is incised anteriorly and posteriorly. A triangular homograft patch is tailored; (c) The aortic arch is interdigitated with the descending aorta in the posterior incision and then the arch is reconstructed with the homograft patch; (d) A smooth and funnel-shaped reconstructed arch is obtained and an aortocoronary to pulmonary anastomosis is then fashioned; (e) Finally, an end-to-end anastomosis is carried out between the aortopulmonary root and the reconstructed aortic arch.

than the pulmonary root, this will diminish the wall tension when the arch is filled with pressured blood, keeping the aortocoronary ostium patent.

The new systemic outlet reconstruction is completed by fashioning an end-to-end aortic anastomosis between the aorto-pulmonary root to the distal augmented arch (**Figure 1(e)**). An important consideration is that the proximal and distal ascending aorta tissue does not necessarily have to match each other, avoiding torsion on the aorto-pulmonary anastomosis, and the potential for coronary insufficiency.

Pulmonary blood flow is reconstituted according to the surgeon's preference (modified Blalock-Taussig shunt or a right ventricle to pulmonary artery conduit).

3. Discussion

The Norwood procedure remains to be a technical challenge. There are several modifications of the original procedure, including the transection of the ascending aorta introduced by van Son, Mosca and Thistlewaite to reconstruct the systemic outlet in ventriculoarterial discordance and hypoplastic aorta [4-6]. These techniques, as the one we describe in normally related great vessels for a diminutive ascending aorta, concomitant aortic arch hypoplasia with or without coarctation, avoid a spiraling incision of the aorta from the inner curvature of the aortic arch to the medial aspect of the ascending aorta, reducing the risk of torsion of the aortic root with its inherent risks of obstruction of the coronary ostia and aortic or pulmonary valve regurgitation.

Coarctation excision reduces the incidence of late arch obstruction, and we routinely excise the coarctation shelf [7]. Because recoarctation and acute arch angles increase the wall shear stress and energy loss, a uniform and unobstructed anatomic result may reduce the workload on the single ventricle [8].

We have found that this modification of the arch reconstruction within the Norwood procedure, by creating two tubes, which result in an end to end aortic anastomosis, simplifies the procedure, makes it reproducible and creates a smooth neo-aortic arch.

REFERENCES

- [1] J. Noonan and A. Nadas, "The Hypoplastic Left Heart Syndrome: An Analysis of 101 Cases," *Pediatric Clinics of North America*, Vol. 5, No. 4, 1958, pp. 1026-1056.
- [2] S. Sinha, S. Rusnak, H. Sommers, R. Cole, A. Muster and M. Paul, "Hypoplastic Left Ventricle Syndrome: Analysis of Thirty Autopsy Cases in Infants with Surgical Consideration," *American Journal of Cardiology*, Vol. 21, No. 2, 1968, pp. 166-173.
[http://dx.doi.org/10.1016/0002-9149\(68\)90316-0](http://dx.doi.org/10.1016/0002-9149(68)90316-0)
- [3] E. Bacha, *et al.*, "Measurement of Technical Performance in Surgery for Congenital Heart Disease: The Stage I Norwood Procedure," *Journal of Thoracic and Cardiovascular Surgery*, Vol. 136, No. 4, 2008, pp. 993-997.
<http://dx.doi.org/10.1016/j.jtcvs.2007.12.091>
- [4] J. van Son, V. Reddy, G. Haas and F. Hanley, "Modified Surgical Techniques for Relief of Aortic Obstruction in {S,L,L} Hearts With Rudimentary Right Ventricle and Restrictive Bulboventricular Foramen," *Journal of Thoracic and Cardiovascular Surgery*, Vol. 110, No. 4, 1995, pp. 909-915.
[http://dx.doi.org/10.1016/S0022-5223\(05\)80157-6](http://dx.doi.org/10.1016/S0022-5223(05)80157-6)
- [5] R. Mosca, *et al.*, "Modified Norwood Operation for Single Left Ventricle and Ventriculoarterial Discordance: An Improved Surgical Technique," *Annals of Thoracic Surgery*, Vol. 64, No. 4, 1997, pp. 1126-1132.
[http://dx.doi.org/10.1016/S0003-4975\(97\)00848-5](http://dx.doi.org/10.1016/S0003-4975(97)00848-5)
- [6] P. Thistlewaite, J. Myers, R. Siewers and J. Ettegedui, "Technique for Repair of Single-Ventricle Hearts with Transposition on the Great Arteries and Aortic Arch Hypoplasia," *Annals of Thoracic Surgery*, Vol. 67, No. 1, 1999, pp. 260-262.
[http://dx.doi.org/10.1016/S0003-4975\(98\)01209-0](http://dx.doi.org/10.1016/S0003-4975(98)01209-0)
- [7] V. Bautista-Hernandez, G. Marx, K. Gauvreau, F. Pigula, E. Bacha, J. Mayer and P. del Nido, "Coarctectomy Reduces Neo-aortic Arch Obstruction in Hypoplastic Left Heart Syndrome," *Journal of Thoracic and Cardiovascular Surgery*, Vol. 133, No. 6, 2007, pp. 1540-1546.
<http://dx.doi.org/10.1016/j.jtcvs.2006.12.067>
- [8] K. Itatani, K. Miyaji, Y. Qian, J. Liu, T. Miyakoshi, A. Murakami, M. Ono and M. Umezu, "Influence of Surgical Arch Reconstruction Methods on Single Ventricle Workload in the Norwood Procedure," *Journal of Thoracic and Cardiovascular Surgery*, Vol. 144, No. 1, 2012, pp. 130-138. <http://dx.doi.org/10.1016/j.jtcvs.2011.08.013>