

Anaesthetic Management and Challenges for Carotid Body Tumour Excision in a Young Nigerian: A Case Report and Review of Literature

Florence A. O. Oguntade¹, Moses Ayodele Akinola^{2*}, Oluwapelumi O. Olusoga-Peters³, Bukola Adesola Olayinka⁴, Rachael Adetola Adeoti⁵

¹Anaesthesia Unit, Department of Surgery, Ben Carson College of Health and Medical Sciences, Babcock University, Ilishan Remo, Ogun State, Nigeria

²Otorhinolaryngology Unit, Department of Surgery, Ben Carson College of Health and Medical Sciences, Babcock University, Ilishan Remo, Ogun State, Nigeria

³Otorhinolaryngology Unit, Department of Surgery, Olabisi Onabanjo University Teaching Hospital, Sagamu, Ogun State, Nigeria

⁴Department of Anaesthesia, Olabisi Onabanjo University Teaching Hospital, Sagamu, Ogun State, Nigeria

⁵Department of Otorhinolaryngology, Warwick Hospital, Warwick, UK

Email: *akinolam@babcock.edu.ng, *ayoakinol12@gmail.com

How to cite this paper: Oguntade, F.A.O., Akinola, M.A., Olusoga-Peters, O.O., Olayinka, B.A. and Adeoti, R.A. (2023) Anaesthetic Management and Challenges for Carotid Body Tumour Excision in a Young Nigerian: A Case Report and Review of Literature. *Case Reports in Clinical Medicine*, 12, 139-147. <https://doi.org/10.4236/crcm.2023.125020>

Received: March 15, 2023

Accepted: May 27, 2023

Published: May 30, 2023

Copyright © 2023 by author(s) and Scientific Research Publishing Inc. This work is licensed under the Creative Commons Attribution International License (CC BY 4.0).

<http://creativecommons.org/licenses/by/4.0/>



Open Access

Abstract

Background: Carotid body tumours (CBTs) are rare tumours that arise from chemoreceptor cells at the bifurcation of carotid artery. Excision of CBT poses several anesthetic challenges and may be complicated with marked intra-operative hemodynamic instability and turbulent postoperative recovery. Attention to details and a meticulous anesthetic plan are essential for successful anesthetic management. **Aim:** To present anaesthetic management and challenges for carotid body tumour excision in a young Nigerian. **Case Presentation:** A 26-year-old man presented with left sided slow growing neck tumour. The tumour was completely excised with no anaesthetic or surgical complication. Histology and immunohistochemistry of the excised tumour confirmed paraganglioma. He was discharged fifteenth post-operative day. **Conclusion:** General anesthesia is the preferred technique. The basic elements of anesthetic management are protection of hemodynamic stability and maintenance of cerebral perfusion pressure (CPP).

Keywords

Anaesthesia, Carotid Body Tumour, Excision, Complications

1. Introduction

Carotid body tumours (CBTs), also known as chemodectoma or paraganglioma, are rare neuroendocrine tumours [1], which arise from chemoreceptor cells found at the carotid bifurcation. They constitute most head and neck paragangliomas [2] [3]. The tumours are usually benign, slow growing but they could become malignant and invade or exert pressure on the neighboring neurovascular tissues [4].

Although CBT can occur at any age, they are usually found in the fourth and fifth decades of life [5]. The reported rate of incidence of CBT is between 0.06 and 3.3 per 100,000 [6] and has a female preponderance that varies with altitude. At sea level, the male/female ratio is 1.1 to 1.4 but at high altitude, 2000 m above sea level, it is 1 to 8.3 [7].

Three types of CBTs have been identified namely familial, hyperplastic and sporadic.

Familial CBTs are usually found in young patients while hyperplastic CBTs occur in conditions of chronic hypoxia such as chronic obstructive pulmonary disease (COPD), cyanotic heart disease and in high altitude dwellers [8].

Blood supply to carotid body tumour is mainly from the external carotid artery (ECA), however, contributions from the internal carotid artery (ICA), vertebral artery ascending pharyngeal artery and superior thyroid artery have been reported.

Shamblin's classification of CBT is based on its association with the internal carotid artery [9].

In order to prevent possibility of local spread and eventual metastasis, early excision of the tumour is advocated, as is the case with all tumours. Excision of CBT poses anaesthetic challenges which may be complicated with significant morbidity and mortality [10].

2. Case Report

A 26-year-old Nigerian male presented with a left-sided slow growing neck tumour of four years duration. The tumour was painless, soft, non-pulsatile and it was associated with some difficulty in breathing but there was no dysphasia. There is positive family history of CBT.

On examination, hypopigmented scar was observed running along the entire length of the tumour (from previous attempt at excising the tumour). The tumour measured 12 by 10 centimeter in size and it was not warm to touch and it was not attached to overlying skin. A similar but smaller tumour mass was also palpated in the right anterior triangle of the neck. There were no palpable lymph nodes. CT scan showed an avidly enhancing highly vascular masses in the carotid spaces splaying the carotid vessels and indenting the internal jugular veins with associated narrowing of the nasopharyngeal air column (**Figure 1** and **Figure 2**). The left carotid mass was excised whole down to its root at the carotid

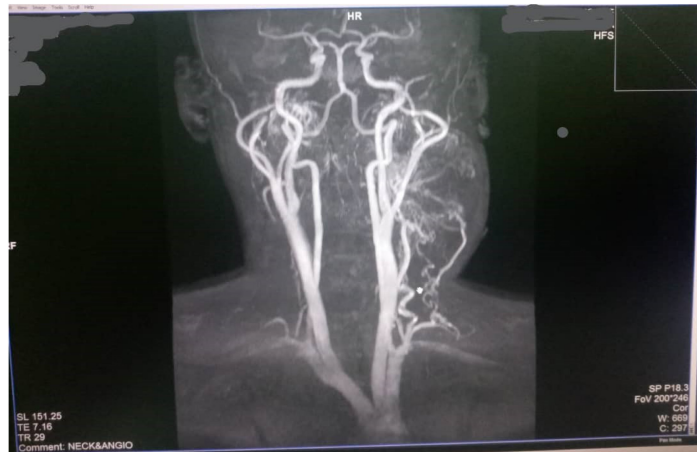

Figure 1. Carotid angiography shows the tumor encasing the carotid on the left CT neck showing the carotid body tumor extending to the skull base.

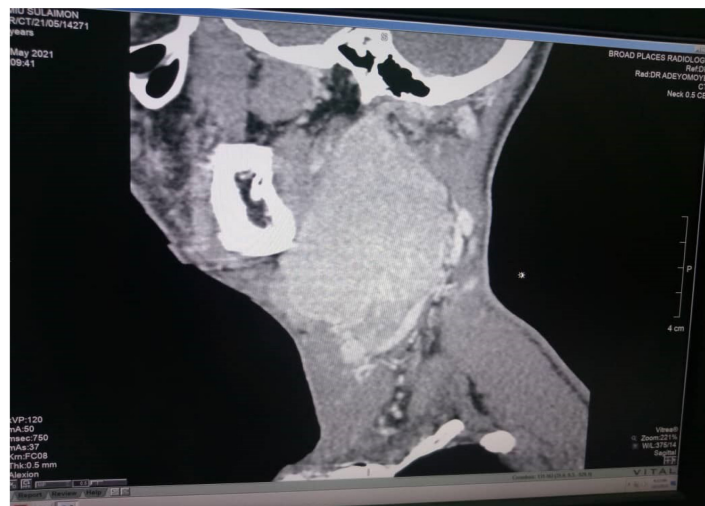


Figure 2. Carotid angiography shows the tumor encasing the carotid on the left CT neck showing the carotid body tumor extending to the skull base.

bifurcation (**Figure 3** and **Figure 4**). The histology (**Figure 5**) and immunohistochemistry of the excised tumour confirmed paraganglioma.

3. Anaesthesia

Routine blood investigations were within normal limits. Recent CT scans and MRI angiography were in keeping with bilateral carotid body tumours. The CT scan revealed an avidly enhanced tumour, highly vascular and with splaying of the internal and external carotid arteries.

Surgical excision of the left CBT under general anesthesia was planned and the patient was admitted to the ward for preoperative review and preparation for surgery.

On the eve of surgery, premedication was commenced with oral diazepam, 5

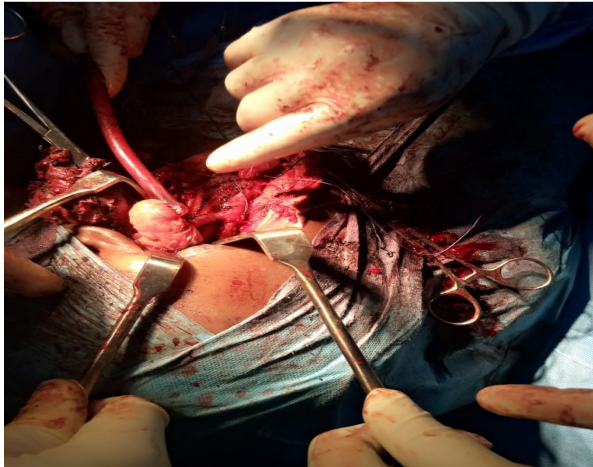


Figure 3. Carotid body tumor completely excised.

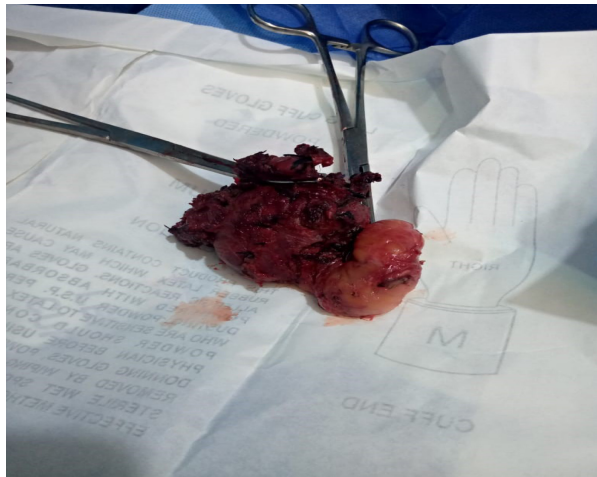


Figure 4. Carotid body tumor completely excised.

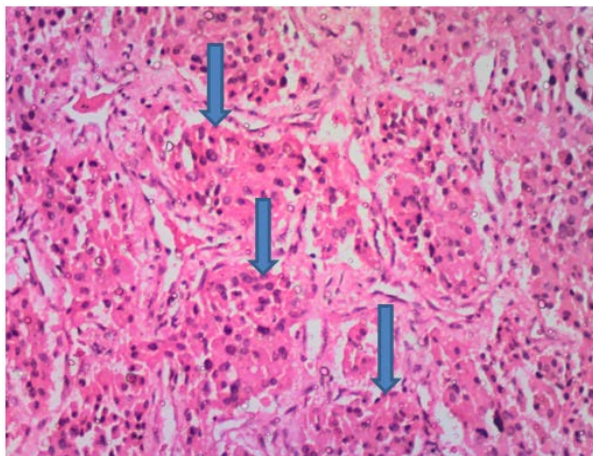


Figure 5. Histological section showing nested packets of mild to moderately pleomorphic tumour cells (arrows) having hyperchromatic central nuclei and moderate eosinophilic, faintly granular cytoplasm consistent with the features of paraganglioma (H & E $\times 40$).

mg, oral ranitidine, 150 mg and oral metoclopramide, 10mg and these were repeated two hours before surgery. The patient was fasted according to the American Society of Anesthesiologists (ASA) fasting guidelines.

Wide bore cannulae (14 G and 18 G), were sited on each upper limb. In the operating theatre, probes of a multinodular monitor including 3-channel electrocardiograph leads were attached to the patient. The baseline vital signs were recorded. Non-invasive blood pressure (NIBP) was 110/80 mmHg, heart rate (HR) was 84 beats per minute and arterial oxygen saturation (SPO₂) was 96 percent, breathing room air. Invasive blood pressure (IBP), central venous pressure (CVP) and somatosensory evoked potential (SSEP) were desired but the equipment and/or the soft-wares for measuring these parameters were not available and were therefore not measured.

Prior to induction of anesthesia, intravenous midazolam, 0.05 mg/kg and intravenous fentanyl, 2 mcg/kg were administered. The patient was pre-oxygenated for 5 minutes. Anesthesia was induced with intravenous propofol 2 mg/kg and oro-tracheal intubation, using reinforced endotracheal tube, 75 mm inner diameter was facilitated with intravenous suxamethonium, 2 mg/kg.

Thereafter, anaesthesia was maintained with isoflurane in oxygen and medical air mixture, intravenous pancuronium 0.08 mg/kg and subsequently in doses of 0.015 mg/kg as required for muscle relaxation and intravenous morphine 0.1 mg/kg for analgesia. Intraoperative blood loss was estimated to be 1.2 litres. Haemodynamic stability was achieved with blood transfusion and intravenous infusion of colloids and crystalloids. Episodes of bradycardia occurred intraoperatively. The bradycardia which occurred during tumour manipulation resolved when the manipulation or handling was discontinued but that which occurred as a result of haemodynamic insufficiency responded well to intravenous atropine and intravenous fluids.

The patient remained relatively stable throughout the course of anesthesia. At the end of surgery, isoflurane was gradually tailed off while the patient breathed 100 percent oxygen. On return of spontaneous breathing, the residual effect of the non-depolarising muscle relaxant, pancuronium, was reversed with intravenous neostigmine 2.5 mg and intravenous glycopyrrolate 0.4 mg.

When the extubation criteria were met, the patient was extubated and he was then transferred to ICU for observation and continued monitoring.

Post-operatively the patient received injections of pentazocine 30 mg twelve hourly and paracetamol infusion whenever there was breakthrough pain. He was discharged to the ward on the third post-operative day in stable clinical condition and finally home on the fifteenth-post-operative day. At discharge, there was complete wound healing.

4. Discussion

The cornerstone of diagnosis and the management of CBT are detailed history, physical examination and radiological studies such as CT scan, MRI and mag-

netic resonance angiography (MRA) [5]. These radiological studies also yield useful information about the composition of the tumour and its relationship with the surrounding tissue and vasculature [10].

Unfortunately in sub-Saharan Africa, CT scan, MRI and MRA are either not accessible or affordable. Ultrasound scan while being readily available is also more affordable and gives some useful information [11].

Differential diagnosis of CBT include medullary thyroid carcinoma, neuroendocrine carcinoma, middle ear adenoma meningioma and schwannoma [12] and these must be ruled out. In some cases, CBTs are active and they secrete catecholamines and serotonin. They may also be associated with pheochromocytoma, a tumor of chromaffin cells which secrete nor-adrenaline, adrenaline, and dopamine. Although rare, acute presentation of pheochromocytoma may include pulmonary oedema, myocardial infarction and cerebrovascular episodes which may occur at any time in the peri-operative period. Mortality can be as high as 90 percent. CBT in this index patient was asymptomatic of inappropriate catecholamine secretions, therefore tests for urinary catecholamines were not done.

Surgical excision of CBT poses several anaesthetic challenges which may increase the risk of perioperative morbidity and mortality. The aims of the anaesthetists include provision of safe anaesthesia, accessible surgical field for the surgeon and good outcome of surgery. All these were achieved by meticulous preoperative review, a good anesthetic plan with attention to details, adept airway management, prevention and proactive management of haemorrhage, including massive hemorrhage and adequate perfusion of brain tissues for optimal delivery of oxygen and nutrients. Maintenance of appropriate cerebral perfusion pressure (CPP) that is, the difference between mean arterial pressure (MAP) and intracranial pressure (ICP) provides the net pressure gradient that drives oxygen to the cerebral tissue. Throughout surgery, MAP was carefully maintained above 65 mmHg as a strategy to prevent ischemia of the brain tissue and stroke.

Hemorrhage is a common complication of CBT excision. Shamblin classification helps to predict the severity of blood loss. Shamblin type I tumor is usually small, localized and can be separated easily from the adjacent carotid arterial wall, while Shamblin type 2 CBT is large and often adherent to the carotid artery which partially encapsulates the tumor and thus increase significantly the risk of hemorrhage and Shamblin type 3, CBTs are closely adherent to the carotid artery and are therefore associated with massive hemorrhage. The complexity of structures in the neck and limited exposure, part of the left sternocleidomastoid muscle, internal jugular vein and cranial nerves X and XI were resected. Such complications are reported in the literature.

Surgical time was prolonged, ten hours compared to the average of 3 hours found in literature. Factors that probably contribute to the prolonged surgical time are rarity of CBT and the consequent limited experience of the surgeon, anesthetist and supporting staff as it relates to tumors of this nature.

Mild hypothermia was beneficial during this surgery because it reduced cerebral metabolic consumption of oxygen, (CMRO₂). A decrease of 1°C body temperature reduces the cerebral metabolic rate by 7 percent and therefore tight control of temperature was required. An attempt towards this goal was achieved by infusing crystalloids at room temperature and monitoring closely the body temperature of the patient.

Hyperventilation causes vasoconstriction of cerebral blood vessels which in turn reduces oxygen delivery to the brain, frequency of ventilation and end-tidal carbon dioxide were also closely monitored.

Administration of anaesthetic agents interferes with intrinsic physiological regulatory mechanism of the body systems. Homeostasis was maintained by infusion of intravenous fluids and drugs and close monitoring of vital signs. Blood loss was carefully estimated and replaced as necessary, while urinary output, a measure of vital organs perfusion was measured hourly. Volatile anesthetics in high concentration cause reduction in the tension of vascular smooth muscle, thus resulting in vasodilation and an increase in cerebral blood flow.

Continuous delivery of oxygen and nutrients is essential to prevent irreversible injury to the brain and oxygen and glucose must be available for use by the brain.

Review of literature revealed that carotid bodies were first described by Von Hiller in 1743 as reddish-brown well circumscribed and highly specialized round organs which are in the adventitia of carotid arteries. The organs play an important role in the control of ventilation during hypoxia, hypercapnia and acidosis by their ability to sense partial pressure of oxygen and carbon dioxide in the blood [13].

CBTs arise from these chemoreceptor cells at the bifurcation of the carotid arteries and they represent about 65 percent of head and neck paraganglioma [14]. These rare tumours occur commonly on the right side of the neck in 57 percent of patients, on the left side of the neck in 25 percent and bilaterally in 17 percent of patients and in about 10 percent of this population, the CBTs were malignant [15]. CBTs are generally slow growing and are usually benign. Occasionally they accompany head and neck paraganglioma, malignant tumours of lungs, breast and larynx [16]. Also about 10 percent of cases present with cranial nerve palsy, paralysis of hypoglossal nerve, glosso-pharyngeal nerve, recurrent laryngeal nerve, spinal accessory nerve and sometimes the parasympathetic chain is involved. [17].

Surgical excision of CBT under general anesthesia is the preferred choice of management, however continuous cervical block (regional anaesthesia) has been reported [18]. Radiation therapy is reserved for inoperable cases.

Perioperative morbidity may be as high as 20 to 40 percent [19]. Hemorrhage is the most common and most challenging complication; therefore, an adequate level of preparedness must be put in place to manage this complication. Preoperative embolization, a method of reducing blood flow to large tumors, have

been used to reduce the risk of massive hemorrhage and consequently hemodynamic instability.

5. Conclusion

CBT excision requires a high degree of vigilance by the anesthesiologist. Cerebral protection, hemorrhage, hypotension and management of arrhythmias are challenging. Successful anesthetic management depends on detailed history, comprehensive investigation and optimization of the patient, monitoring and prompt management of complications that may occur in the perioperative period.

Conflicts of Interest

The authors declare no conflicts of interest regarding the publication of this paper.

References

- [1] Sevilla Garcia, M.A., Llorrente Pendas, J.L., Rodugo Tapia, J.P., Garcia Rostan, G., Suarez Fente, V. and Coca Pelaz, A. (2007) Head and Neck Paragangliomas: Revision of 89 Cases in 73 Patients. *Acta Otorrinolaringologica*, **58**, 94-100. [https://doi.org/10.1016/S2173-5735\(07\)70311-3](https://doi.org/10.1016/S2173-5735(07)70311-3)
- [2] Milewski, C. (1993) Morphology and Clinical Aspects of Paraganglioma in the Area of Head and Neck. *HNO*, **41**, 526-531.
- [3] Davidovic, L.B., Djukic, V.B., Vasic, D.M., Sindjelic, R.P. and Duvnjak, S.N. (2005) Diagnosis and Treatment of Carotid Body Paraganglioma: 21 Years of Experience at a Clinical Centre in Serbia. *World Journal of Surgical Oncology*, **3**, Article No. 10. <https://doi.org/10.1186/1477-7819-3-10>
- [4] Van den Berg, R. (2005) Imaging and Management of Head and Neck paragangliomas. *European Radiology*, **15**, 1310-1318. <https://doi.org/10.1007/s00330-005-2743-8>
- [5] Karigar, S.L., Kunakeri, S. and Shetti, A.N. (2014) Anaesthetic Management of Carotid Body Tumour Excision. A Case Report and Brief Review. *Anesthesia: Essays and Researches*, **8**, 259-262. <https://doi.org/10.4103/0259-1162.134528>
- [6] Georgiadis, G.S., Lazarides, M.K., Tsalkidis, A., Argyropoulou, P. and Giatromanolaki, A. (2008) Carotid Body Tumour Is a 13 Year-Old Child: Case Report and Review of the Literature. *Journal of Vascular Surgery*, **47**, 874-880. <https://doi.org/10.1016/j.jvs.2007.10.040>
- [7] Sajid, M.S., Hamilton, G. and Baker, D.M. (2007) A Multicenter Review of Carotid Body Tumour Management. *European Journal of Vascular and Endovascular Surgery*, **34**, 127-130. <https://doi.org/10.1016/j.ejvs.2007.01.015>
- [8] Obholzer, R.J., Homigold, R., Connor, S. and Gleeson, M.J. (2011) Classification and Management of Cervical Paraganglioma. *The Annals of the Royal College of Surgeons of England*, **93**, 596-602. <https://doi.org/10.1308/147870811X13137608455172>
- [9] Shamblin, W.R., Remine, W.H., Sheps, S.G. and Harrison Jr, E.G. (1971) Carotid Body Tumour (Chemodectoma). Clinicopathologic Analysis of 90 Cases. *The American Journal of Surgery*, **122**, 732-739.

[https://doi.org/10.1016/0002-9610\(71\)90436-3](https://doi.org/10.1016/0002-9610(71)90436-3)

- [10] Luo, T., Zhang, C., Ning, Y.C., Gu, Y.Q., Li, J.X. and Wang, Z.G. (2013) Surgical Treatment of Carotid Body Tumor: Case Report and Literature Review. *Journal of Geriatric Cardiology*, **10**, 116-118.
- [11] White, G., Forbes, M., Busch, K., Hawis, J.P. and Makeham, V. (2007) Carotid Body Tumour or Not. Ultrasound Diagnostic Features. In: *Vascular 2007 Conference Handbook and Book of Abstracts*. Melbourne, Australia, 72.
- [12] Wieneke, J.A. and Smith, A. (2009) Paraganglioma: Carotid Body Tumour. *Head and Neck Pathology*, **3**, 303-306. <https://doi.org/10.1007/s12105-009-0130-5>
- [13] Gonzalez, C., Rocher, A. and Zapata, P. (2003) Arterial Chemoreceptors: Cellular and Molecular Mechanisms in the Adaptive and Homeostatic Function of the Carotid Body. *Revue Neurologique*, **36**, 239-254.
- [14] Bakoyiannis, K.C., Georgopoulos, S.E., Ilonaris, C.N., Tsekouras, N.S., Felekouras, E.S. and Pikoutis, E.A. (2006) Surgical Treatment of Carotid Body Tumours without Embolization. *International Angiology*, **25**, 40-45.
- [15] Alsoul, N.M., Almadu, M.M., Alardah, M.I. and Altaher, R.N. (2009) Carotid Body Paraganglioma Management and Outcome. *European Journal of Scientific Research*, **37**, 567-574.
- [16] Davis, F.M., Obi, A. and Osborne, N. (2018) Carotid Body Tumors. In: Hans, S., Ed., *Extracranial Carotid and Vertebral Artery Disease*, Springer, Cham, 253-260. https://doi.org/10.1007/978-3-319-91533-3_21
- [17] Kavakli, A.S. and Ozturk, N.K. (2016) Anesthetic Approaches in Carotid Body Tumour Surgery. *Northern Clinics of Istanbul*, **3**, 97-103.
- [18] Jones, H.G. and Stoneham, M.D. (2006) Continuous Cervical Plexus Block for Carotid Tumour Excision in a Patient with Eisenmenger's Syndrome. *Anesthesia*, **61**, 1214-1218. <https://doi.org/10.1111/j.1365-2044.2006.04860.x>
- [19] Kohler, H.F., Carvalho, A.L., Mattos-Granja, N.V., Nishinam, K. and Kowalski, L.P. (2004) Surgical Treatment of Paragangliomas of the Carotid Bifurcation: Results of 36 Patients. *Head and Neck*, **26**, 1058-1063. <https://doi.org/10.1002/hed.20105>

Abbreviations

CBT: Carotid body tumour

NIBP: Non invasive blood pressure

IBP: Invasive blood pressure

SSEP: Somatosensory evoked potential

CMR02: Cerebral metabolic rate of oxygen