

Liposomal Bupivacaine in Erector Spinae Plane Block and Interscalene Block for Scapular and Proximal Humerus Resections

Mohamad Ayoub, Sree Kolli, Husien Taleb

Department of General Anesthesiology, Cleveland Clinic Foundation, Cleveland, OH, USA
Email: husien.taleb1990@gmail.com

How to cite this paper: Ayoub, M., Kolli, S. and Taleb, H. (2023) Liposomal Bupivacaine in Erector Spinae Plane Block and Interscalene Block for Scapular and Proximal Humerus Resections. *Open Journal of Anesthesiology*, 13, 135-139.
<https://doi.org/10.4236/ojanes.2023.137013>

Received: April 2, 2023

Accepted: July 11, 2023

Published: July 14, 2023

Copyright © 2023 by author(s) and Scientific Research Publishing Inc.

This work is licensed under the Creative Commons Attribution International License (CC BY 4.0).

<http://creativecommons.org/licenses/by/4.0/>



Open Access

Abstract

Erector spinae plane block (ESPB) is a novel fascial plane block that was first described in 2016. It is considered an alternative for brachial plexus blocks in shoulder surgeries as the erector spinae muscle extends to the cervical level. Herein, we present a successful multilevel ESPB plus an interscalene block using liposomal bupivacaine in a 45-year-old female patient with metastatic sarcoma who presented for scapula and proximal humerus resection. The post-operative course was smooth, and the patient was discharged home on post-operative day 2 with minimal narcotic requirements.

Keywords

Acute Pain, Erector Spinae Plane Block, Phrenic Nerve, Liposomal Bupivacaine—Regional Anesthesia, Spindle Cell Sarcoma

1. Introduction

Erector spinae plane block (ESPB), first described in 2016, is a novel fascial plane block [1]. This block gained popularity in multiple procedures, including spinal, thoracic, and abdominal surgeries. ESPB is performed either as a single shot block or catheter placement with continuous infusion if a prolonged block is desired. Local anesthetic volume and concentration are essential factors while performing ESPB, commonly with volumes between 10 to 40 ml [2]. Moreover, ESPB is considered an alternative for brachial plexus blocks in shoulder surgeries as the erector spinae muscle extends to the cervical level [3]. The ESP block functions by the spreading of local anesthetic into the paravertebral spaces, causing a blockage of the dorsal and ventral ramus of spinal nerves, along with potential spread through the transforaminal and epidural routes [4]. The injected anes-

thetic mixture can cover as many as 4 - 8 vertebral levels [5]. We present a case of a successful multilevel ESPB plus interscalene block using liposomal bupivacaine in a patient with metastatic sarcoma who presented for resection of the scapula and proximal humerus.

2. Case Report

A 45-year-old female patient with a history of undifferentiated spindle cell sarcoma of the anterior mediastinum status post-resection presented with a painful metastatic lesion to the right scapula. She underwent chemotherapy and cryoablation, which was unsuccessful in curing this lesion. Her case was discussed during the tumor board with a decision for scapulectomy and modified Tikhoff-Linberg reconstruction to control the local spread.

Acute pain management was consulted for pre-operative peripheral nerve block placement. The acute pain and surgical teams agreed that a single shot block with liposomal bupivacaine was the best pre-operative method for the patient, because the ESP catheter would be in the surgical field with difficulty placing it post-operatively without removing the dressing pre-operatively. The patient agreed to receive multilevel ESPB with interscalene brachial plexus block using liposomal bupivacaine. The patient was placed in a sitting position and her back was prepped with chlorhexidine. Using a low-frequency, curvilinear ultrasound transducer in a longitudinal orientation, the T4 spinous process was identified. The ultrasound probe was moved laterally to identify the trapezius, rhomboid major, and erector spinae superficial to the transverse process. A 20G-10 cm echogenic needle was inserted in-plane under ultrasound guidance in a caudad-to-cephalad direction until it touched the transverse process. After negative aspiration, 13 ml of 1.3% Liposomal Bupivacaine and 0.5% Bupivacaine mixture was injected under ultrasound visualization in the erector spinae plane (**Figure 1**). The same technique was used again at the level of T5 and T6 spinous processes using 13 ml of the anesthetic mixture at each level. Multilevel (T4, T5, T6) ESPB was done because the patient was obese and we wanted to make sure that all the local anesthetic was injected under the erector spinae muscle and spread evenly along the 3 spaces (T4, T5, T6) in the ESPB to not waste some of the medication intramuscularly.

For the interscalene block, the patient was positioned in a supine position with her head rotated towards the contralateral side. Using a high-frequency linear ultrasound transducer, we identified the anterior and middle scalene muscles with the brachial plexus between them. Using a 20G-10 cm echogenic needle, 10 ml of 1.3% Liposomal Bupivacaine and 0.5% Bupivacaine mixture were injected around the plexus (**Figure 2**).

The patient underwent a right extra-articular scapulectomy with modified Tikhoff-Linberg reconstruction under general anesthesia (**Figure 3**). She received 175 mcg of fentanyl intraoperatively. The patient was extubated and discharged to the recovery room. Her pain was well controlled post-operatively. During her hospital stay, she started physical therapy and remained comfortable with very

well-tolerated pain controlled on only low-dose opiates (oxycodone) and acetaminophen until her discharge day. During her hospital stay, the patient didn't complain of any side effects from the block or shortness of breath. We didn't notice any change in her sensory or motor function during her stay.

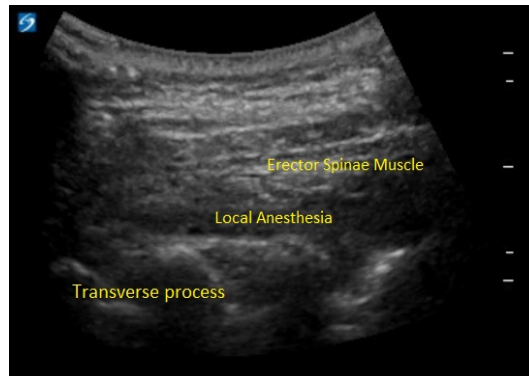


Figure 1. Ultrasound showing local anesthetic spread in the erector spinae fascial plane.

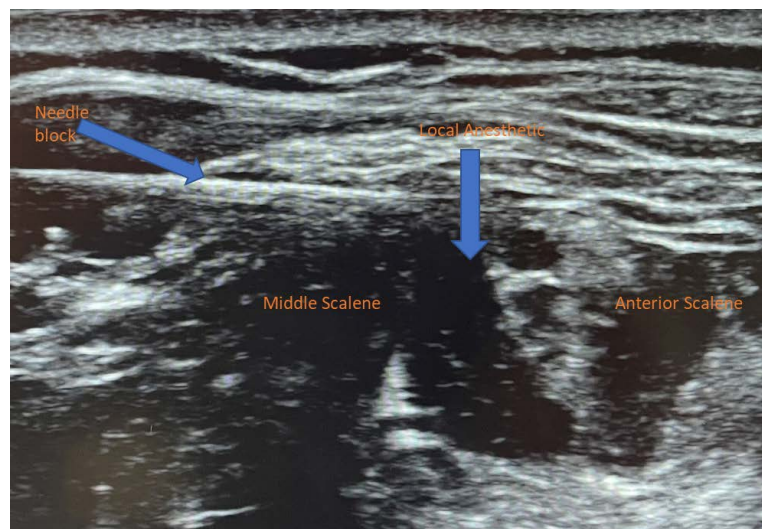


Figure 2. Ultrasound showing the needle and the local anesthetic spread in the interscalene groove (between middle and anterior scalene muscles) along the brachial plexus.

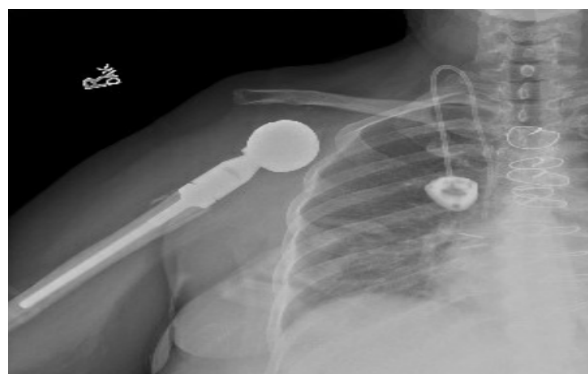


Figure 3. Right extra-articular scapulectomy with modified Tikhoff-Linberg reconstruction.

3. Discussion

The use of ESPB for thoracic, shoulder and back surgeries has been recently expanding. This block shows a safer profile compared to neuraxial blocks, especially regarding hemodynamic stability, spinal cord injury, epidural hematoma, and lung injury [6]. Moreover, it is considered an easier block compared to the thoracic epidural and paravertebral block and can reduce the amount of opioid consumption perioperatively. In this case, we decided to add liposomal bupivacaine to the anesthetic mixture to prolong the duration of action. Its use showed reductions in narcotic consumption, better pain control, and a decrease in the length of stay when used in transversus abdominis plane block [7]. As ESPB is another fascial plane block, we believe that the use of liposomal bupivacaine might be a good option to provide prolonged pain relief, especially in surgeries that involve multiple body compartments. In our patient, the surgical incision involved the back, shoulder, and upper arm. For that, we did multilevel ESPB (at T4, T5, and T6) to cover the scapular dermatomal levels. In addition, we believed that the spread of the mixture under the erector spinae muscle would target the cervical dermatomes supplying the upper arm and shoulder. We also did a single-shot interscalene block in order to ensure brachial plexus blockade. Performing the ESP block offers several key benefits. One advantage is that it can be easily executed, whether in the sitting or lateral position. Additionally, the block can be safely performed in patients who are receiving anticoagulation therapy, especially at the thoracic level. The patient was comfortable with her pain level and was discharged on post-operative day 2. Her use of narcotics was minimal, and she didn't require any additional procedural or medical intervention to control her pain.

Complications from ESPB are very rare, especially at the thoracic level, because it is more superficial as compared to the ESPB at the lumbar level. The injection site is a bit away from major structures like pleura, spinal cord and major blood vessels [1].

4. Conclusion

ESPB with liposomal bupivacaine is a promising analgesic technique that can be easily used in multiple surgical procedures. Our experience showed that it can be used for scapular and upper arm surgeries. Identifying the proper anesthetic dosing and the spread level will help expand the use of this block.

Conflicts of Interest

The authors declare no conflicts of interest regarding the publication of this paper.

References

- [1] Krishnan, S. and Cascella, M. (2022) Erector Spinae Plane Block. In: StatPearls, Ed., *Treasure Island*, StatPearls Publishing, Tampa, FL.

-
- [2] Abdella, A.M.M.R., Arida, E.E.A.E.M., Megahed, N.A., El-Amrawy, W.Z. and Mohamed, W.M.A. (2022) Analgesia and Spread of Erector Spinae Plane Block in Breast Cancer Surgeries: A Randomized Controlled Trial. *BMC Anesthesiology*, **22**, Article No. 321. <https://doi.org/10.1186/s12871-022-01860-w>
- [3] Ma, D.X., Wang, R., Wen, H., Li, H.L. and Jiang, J. (2021) Cervical Erector Spinae Plane Block as a Perioperative Analgesia Method for Shoulder Arthroscopy: A Case Series. *Journal of Anesthesia*, **35**, 446-450. <https://doi.org/10.1007/s00540-021-02907-x>
- [4] Schwartzmann, A., Peng, P., Maciel, M.A. and Forero, M. (2018) Mechanism of the Erector Spinae Plane Block: Insights from a Magnetic Resonance Imaging Study. *Canadian Journal of Anesthesia / Journal Canadien d'Anesthésie*, **65**, 1165-1166. <https://doi.org/10.1007/s12630-018-1187-y>
- [5] Adhikary, S.D., Pruett, A., Forero, M. and Thiruvankatarajan, V. (2018) Erector Spinae Plane Block as an Alternative to Epidural Analgesia for Post-Operative Analgesia following Video-Assisted Thoracoscopic Surgery: A Case Study and a Literature Review on the Spread of Local Anaesthetic in the Erector Spinae Plane. *Indian Journal of Anaesthesia*, **62**, 75-78. https://doi.org/10.4103/ija.IJA_693_17
- [6] Oezel, L., Hughes, A.P., Onyekwere, I., Wang, Z., Arzani, A., Okano, I., Zhu, J., Sama, A.A., Cammisa, F.P., Girardi, F. and Soffin, E.M. (2022) Procedure-Specific Complications Associated with Ultrasound-Guided Erector Spinae Plane Block for Lumbar Spine Surgery: A Retrospective Analysis of 342 Consecutive Cases. *Journal of Pain Research*, **15**, 655-661. <https://doi.org/10.2147/JPR.S354111>
- [7] Fayeziadeh, M., Majumder, A., Neupane, R., Elliott, H.L. and Novitsky, Y.W. (2016) Efficacy of Transversus Abdominis Plane Block with Liposomal Bupivacaine during Open Abdominal Wall Reconstruction. *The American Journal of Surgery*, **212**, 399-405. <https://doi.org/10.1016/j.amjsurg.2015.12.026>