

Histiocytic Necrotizing Lymphadenitis: A Clinical Study of 6 Children and Literature Review

Yeling Yuan¹, Feng Zhang^{2*}, Tuanmei Wang^{3*}

¹Hunan University of Chinese Medicine, Changsha, China

²Department of Pediatric, The Affiliated Changsha Central Hospital, Hengyang Medical School, University of South China, Changsha, China

³Changsha Hospital for Maternal & Child Health Care, Changsha, China

Email: *handsomeboy313@163.com, *1396308863@qq.com

How to cite this paper: Yuan, Y.L., Zhang, F. and Wang, T.M. (2022) Histiocytic Necrotizing Lymphadenitis: A Clinical Study of 6 Children and Literature Review. *Open Journal of Clinical Diagnostics*, 12, 19-26. <https://doi.org/10.4236/ojcd.2022.122003>

Received: March 16, 2022

Accepted: April 25, 2022

Published: April 28, 2022

Copyright © 2022 by author(s) and Scientific Research Publishing Inc.

This work is licensed under the Creative Commons Attribution International License (CC BY 4.0).

<http://creativecommons.org/licenses/by/4.0/>



Open Access

Abstract

Objective: As a rare cause of fever and lymphadenopathy (especially in the neck) in children, the purpose of this study is to explore the clinical characteristics of histiocytic necrotizing lymphadenitis (HNL) in children and improve the diagnosis and treatment of this disease. **Methods:** We retrospectively collected the data of 6 pediatric patients with HNL diagnosed by lymph node biopsy from 2012 to 2021 in department of pediatric, the affiliated Changsha Central Hospital, Hengyang Medical School, University of South China, including the clinical characteristics, laboratory examinations, imaging findings and histopathological examinations, treatment and follow-up of the patients and reviewed relevant literature. **Results:** All the patients were Han girls, with no kinship with each other, and four cases were from rural areas. The age of onset was from 7 to 14 years old, with durations ranged from 1 week to 3 months. All children had cervical lymphadenopathy with tenderness, five cases of fever, two cases of cough, one case of weight loss, four cases of leukopenia, one case of liver impairment, one case of combined bacterial infection of leukocytosis. All children underwent lymph node biopsy and were diagnosed with HNL, four children were treated with anti-infection before diagnosis, two children were treated with steroid therapy after diagnosis, and 1 case of weakened immune function was used immunoglobulin for modulating immunity. All children improved and discharged, and no recurrence was observed until October 2021. **Conclusion:** In our study, the children with swollen lymph nodes in the neck were accompanied by tenderness and fever as the main clinical manifestations, without specificity. Histopathology and immunohistochemical examination by removing the affected lymph nodes could confirm HNL. Most children had a good prognosis and

long-term follow-up were required.

Keywords

Kikuchi-Fujimoto Disease, Histiocytic Necrotizing Lymphadenitis, Children, Literature Review

1. Introduction

Histiocytic necrotizing lymphadenitis (HNL), also known as Kikuchi-Fujimoto disease (KFD), is a rare benign and self-limiting disease. This disease was first discovered in Japan in 1972 by Kikuchi and Fujimoto. The etiology and pathogenesis are unknown [1]. According to researches in this field, the possible cause of KFD is considered to be caused by viral infection or autoimmunity [2]. The course of the disease ranges from a few weeks to several months. The main manifestations of HNL are fever, lymphadenopathy (mainly in the neck), leukopenia, and reports of atypical symptoms such as rash, headache, night sweats, weight loss, and nervous system symptoms [3]. HNL is rare in the clinic, and there is no specific clinical manifestations, imaging and laboratory results, so it is easy to be misdiagnosed as upper respiratory tract infection, lymphadenitis, scrofula, malignant lymphoma, infectious mononucleosis and autoimmunity diseases such as systemic lupus erythematosus (SLE). Therefore, we collected the data of children with HNL diagnosed in our hospital and studied in combination with relevant literature to improve our understanding of the disease.

2. Material and Methods

We retrospectively collected the data of 6 pediatric patients with HNL diagnosed by lymph node biopsy from 2012 to 2021 in department of pediatric, the affiliated Changsha Central Hospital, Hengyang Medical School, University of South China, including the clinical characteristics, laboratory examinations, imaging findings and histopathological examinations, treatment and follow-up of the patients and reviewed relevant literatures.

Statistical analyses: continuous variables were presented as mean and 95% CI or median and interquartile range, while categorical variables were described using sample counts and percentages.

3. Results

Among the 6 children, they were not related to each other. The age of onset was from 7 to 14 years old, the median age of onset was 13 years old, the course of illness varied from 1 week to 3 months, and the median time of onset was 10.5 days. Two of the 6 children had a history of cervical lymph node tuberculosis confirmed by lymph node biopsy, and they completed regular and adequate anti-tuberculosis treatment. Four cases had leukopenia, one case had liver damage (increased alanine aminotransferase and aspartate aminotransferase), one case

had leukocytosis combined *Burkholderia cepacia*, three cases had elevated erythrocyte sedimentation rate (ESR) without anemia or thrombocytopenia. All children underwent tuberculosis-related examinations (such as TST, AFB, GeneXpert MTB/RIF, T-SPOT.TB) and those were negative. All children had Epstein-Barr virus serological examination, one was positive and combined with adenovirus infection. Four cases of autoimmune disease tests (such as antinuclear antibodies, rheumatic factors) showed negative, and HIV examinations were all negative. Three cases of bone marrow puncture ruled out blood system diseases. Ultrasound of cervical lymph nodes in all children showed that cervical lymph nodes were enlarged, some of which were combined with enlarged axillary, inguinal or abdominal lymph nodes. All children underwent lymph node biopsy and were diagnosed with HNL, and 5 cases underwent immunohistochemistry (the remaining 1 case was because our hospital had not yet implemented immunohistochemistry technology at the time). (Figure 1: Histologic findings include cortical or paracortical areas presenting varying degrees of coagulative necrosis with abundant karyorrhectic debris, and a large number of different types of histiocytes and immunoblasts surrounding the margin of necrotic areas. Immunophenotypically, a predominance of T cells.) Four children were treated with anti-infective treatment before diagnosis, two children were treated with steroid therapy after diagnosis, including 1 case of oral prednisone and 1 case of intravenous methylprednisolone, and 1 case of weakened immune function was used immunoglobulin for modulating immunity. All the children were improved and discharged, and no recurrence occurred during follow-up. Detailed clinical characteristics were shown in Table 1, and laboratory informations were shown in Table 2.

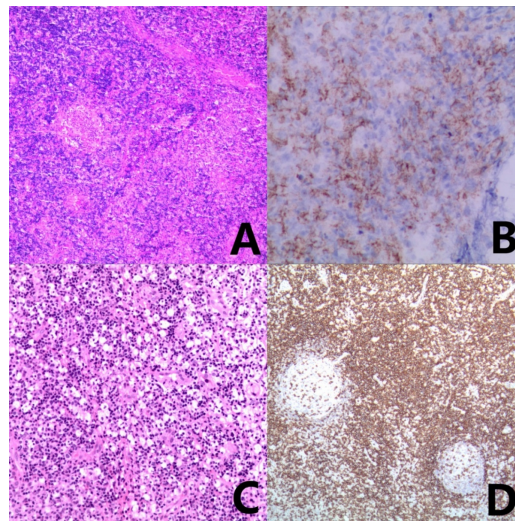


Figure 1. The pathology of the cervical lymph nodes. (A) (40×), Circumscribed sheets of histiocytes were accompanied by detrital necrosis, and coagulation necrosis can be seen locally. (B) (400×), Histiocytes stain positive with myeloperoxidase immunohistochemical stain. (C) (100×), in the xanthomatous phase of disease numerous foamy histiocytes were seen without prominent necrosis. (D) (100×), CD3 and CD5 immunohistochemistry of tissue cells in the diseased area were positive.

Table 1. Characteristics of KFD in six children.

Characteristic	Case 1	Case 2	Case 3	Case 4	Case 5	Case 6
Age (years)	13	13	14	12	7	14
Gender	Female	Female	Female	Female	Female	Female
Residence zone	Country	Country	City	City	Country	Country
Fever	Yes (a week)	No	Yes (2 days)	Yes (8 days)	Yes (12 days)	Yes (a week)
Weight loss	No	No	Yes (3 kg in a week)	No	No	No
Cough	Yes	No	No	Yes	No	No
Duration of cervical lymph node swelling	A week	3 months	9 days	8 days	12 days	A month
Past medical history	Tuberculous lymphadenitis	Health	Health	Health	Tuberculous lymphadenitis, weakened immune function	Health
Physical examination	Enlarged bilateral cervical lymph nodes, tenderness, fixed, firm	Enlarged right cervical lymph nodes, tenderness, fixed, firm	Enlarged left cervical lymph nodes, tenderness	Enlarged left cervical lymph nodes, tenderness	Enlarged right cervical lymph nodes, tenderness, fixed, firm, skin temperature rise	Enlarged bilateral cervical lymph nodes, tenderness
Use antibiotics before diagnosis?	Yes	No	Yes	Yes	Yes	No
Infection or not	No	No	No	Epstein-Barr virus, adenovirus	<i>Burkholderia diminuta</i>	No

Table 2. Laboratory results of KFD in six children.

Laboratory Parameter	WBC ($\times 10^9/L$)	HB (g/L)	PLT ($\times 10^9/L$)	ESR (mm/h)
Range	1.56 - 15.78	83.00 - 135.00	72.00 - 432.00	14.00 - 85.00
Mean	5.22	111.80	207.83	37.40
Median	3.30	110.90	180.50	33.00

4. Discussion

Since Kikuchi-Fujimoto disease was first discovered in Japan, more and more researchers have joined the research on this disease. Based on literature study, among adults, HNL is predominantly female, with a ratio of 4:1 [4]. However, studies on children find that the ratio of males is larger, with a ratio of 1.13:1, and the average age of children range from 11 to 13.2 years [3]. The average age in this study was similar with that reported in literatures but the subjects were all girls, which might be due to the lack of comprehensiveness of the data.

There are currently two most common viewpoints of its etiology: viral infection and autoimmunity. HNL clinical manifestations and antibiotics are similar

to viral infections. Posterior cervical lymphadenopathy (mainly unilateral and V zone) and fever are the main clinical manifestations of KFD [5], and rare symptoms include weight loss, nausea, vomiting, rash, and upper respiratory symptoms [6] [7]. However, there was only one patient with viral infection in this study, and there was no research on the direct relationship between viral infections and KFD [8] [9]. In addition, there are reports that KFD is related to many autoimmune diseases, such as SLE, dry syndrome, Wegener granuloma, etc. [10] [11]. The researchers find that HNL patients are mainly concentrated in Asia, with certain genetic susceptibility. KFD enables T cells to induce immune responses to multiple antigens in gene susceptible individuals, and the study of KFD patients find that they often carry human white blood cells DPA1 and DPB1 of the antigens (HLA) II alleles [12].

For most children with cervical lymphadenopathy, ultrasound is the best diagnostic tool because it has no radiation and is non-invasive. When the affected lymph nodes are examined by ultrasound, hypoechoic foci are visible, and thick and irregular hyperechoic rings are visible on the outside [10]. However, ultrasonography is of limited value in the internal necrosis of lymph nodes, but CT scans can show extensive gross necrosis of diseased lymph nodes. The most common CT features of KFD in children are multiple, small, medium oval lymph nodes and round lymph node clusters related to internal necrosis [13]. ¹⁸F-FDG PET/CT may be useful in assessing KFD severity [14]. In terms of laboratory examination, children with KFD mostly showed decreased white blood cells and neutrophil counts. In addition, some children had abnormal liver enzymes and elevated ESR [3], which was consistent with the laboratory performance of children in this study. However, these manifestations are not specific.

As a self-limiting disease, most of KFD is currently diagnosed by histopathology and immunohistochemical examination of the affected lymph nodes. Involved lymph nodes are usually isolated, solid, mobile, painful but not purulent. Histologically, the lesions of the lymph nodes are mainly concentrated in the paracortical area, the structure of the lymph nodes is missing, the necrotic foci show a great deal of nuclear debris, and there are so-called crescent tissue cells. Among the tissue cells, small lymphocytes, activated T cells and plasma cells can be seen, and a large number of tissue cells accumulate at the edge of necrosis. The isolated apoptotic cells are scattered in large tissue cells, mixed with cell debris and nuclear dust. In addition, plasmacytoid dendritic cells (pDCs) and immunoblasts can also be seen, thromboangiitis are distributed around the necrosis. Among them, the obvious lack of neutrophils, eosinophils and plasma cells are characteristic lesions and have great diagnostic value. The tissue cells in KFD are positive for lysozyme, myeloperoxidase, CD68, CD163 and CD4. The lymphocytes in the lesion are mainly T cells, mainly CD8. Compared with CD4, there are very few CD20-positive B cells [2] [10] [15]. A large number of CD8-positive cytotoxic T cells in lymphoid follicles are related to FDC network changes. The rich and distorted FDC network structure spans all morphological patterns, which can be regarded as important supporting diagnostic evidence for KFD

[16]. According to histological characteristics, the researchers find that KFD can be divided into three histological patterns: hyperplasia, necrosis and xanthoma [17].

Patients can fully recover on their own within a few weeks to several months, while cervical lymphadenitis can last for 6 months to 1 year. Approximately 3% - 4% of adults can relapse, but studies have found that children with KFD have a higher recurrence rate of 42.4% [18]. Symptomatic and supportive treatment is an effective means to relieve symptoms of persistent fever and pain, including glucocorticoids, intravenous immunoglobulin, or hydroxychloroquine. Studies have found that removing the affected lymph nodes is effective for treatment [3]. Most KFD patients quickly relieve their symptoms after taking glucocorticoids. A small number of patients with severe illness or poor response to glucocorticoids can receive intravenous immunoglobulin [19] [20]. Hydroxychloroquine has also been used in the treatment of KFD, which has a certain effect on some patients with refractory KFD, but there is no clear guidance on the dosage and course of treatment [11]. The current research shows that the prognosis of children is usually better than that of adults. Although most patients with KFD have a good prognosis, there are also a few that can develop into other diseases, such as autoimmune hepatitis, SLE, Sjogren's syndrome, hemophagocytic syndrome, mixed connective tissue disease, etc. have been reported. Therefore, long-term follow-up is required [21]. In a few cases, children with KFD may have neurological complications, such as meningoencephalitis, cerebellar ataxia, and encephalitis with central nervous system disease [22]. For patients with nervous system involvement, it is necessary to control intracranial pressure and convulsions. The sample size of this study is small, and the reference to children's HNL is limited, and the sample size needs to be expanded for further study.

5. Conclusion

As a rare disease, KFD has brought huge diagnostic challenges to clinicians. Due to the lack of specific clinical manifestations, laboratory examinations and imaging findings, most children will receive treatment for diseases such as anti-infection and anti-tuberculosis before diagnosis. What's more, KFD is diagnosed by histopathology and immunohistochemical examination of the affected lymph nodes, and the removal of the affected lymph nodes has a therapeutic effect. Due to the self-limiting nature of the disease, most children have a good prognosis, but required long-term follow-up.

Data Declaration

The authors confirm that no prior presentation of the study data as an abstract or poster has taken place.

Conflicts of Interest

The authors declare no conflicts of interest regarding the publication of this paper.

References

- [1] Khan, A.M., Ahmad, M., Muhammad, O., Taj, S. and Shiza, S.T. (2021) Kikuchi-Fujimoto Disease in a Young Female: A Case Report and Literature Review. *Cureus*, **13**, e19321. <https://doi.org/10.7759/cureus.19321>
- [2] Perry, A.M. and Choi, S.M. (2018) Kikuchi-Fujimoto Disease: A Review. *Archives of Pathology & Laboratory Medicine*, **142**, 1341-1346. <https://doi.org/10.5858/arpa.2018-0219-RA>
- [3] Selvanathan, S.N., Suhumaran, S., Sahu, V.K., Chong, C.Y., Tan, N.W.H. and Thoon, K.C. (2020) Kikuchi-Fujimoto Disease in Children. *Journal of Paediatrics and Child Health*, **56**, 389-393. <https://doi.org/10.1111/jpc.14628>
- [4] Tariq, H., Gaduputi, V., Rafiq, A. and Shenoy, R. (2014) The Enigmatic Kikuchi-Fujimoto Disease: A Case Report and Review. *Case Reports in Hematology*, **2014**, Article ID: 648136. <https://doi.org/10.1155/2014/648136>
- [5] Kang, H.M., Kim, J.Y., Choi, E.H., Lee, H.J., Yun, K.W. and Lee, H. (2016) Clinical Characteristics of Severe Histiocytic Necrotizing Lymphadenitis (Kikuchi-Fujimoto Disease) in Children. *The Journal of Pediatrics*, **171**, 208-12.E1. <https://doi.org/10.1016/j.jpeds.2015.12.064>
- [6] Ahmed, Z., Quadir, H., Hakobyan, K., Gaddam, M., Kannan, A., Ojinnaka, U. and Mostafa, J.A. (2021) Kikuchi-Fujimoto Disease: A Rare Cause of Cervical Lymphadenopathy. *Cureus*, **13**, e17021. <https://doi.org/10.7759/cureus.17021>
- [7] Lelii, M., Senatore, L., Amodeo, I., Pinzani, R., Torretta, S., Fiori, S., Marchisio, P. and Bosis, S. (2018) Kikuchi-Fujimoto Disease in Children: Two Case Reports and a Review of the Literature. *Italian Journal of Pediatrics*, **44**, Article No. 83. <https://doi.org/10.1186/s13052-018-0522-9>
- [8] Rosado, F.G.N., Tang, Y.W., Hasserjian, R.P., McClain, C.M., Wang, B. and Mosse, C.A. (2013) Kikuchi-Fujimoto Lymphadenitis: Role of Parvovirus B-19, Epstein-Barr Virus, Human Herpesvirus 6, and Human Herpesvirus 8. *Human Pathology*, **44**, 255-259. <https://doi.org/10.1016/j.humpath.2012.05.016>
- [9] Chong, Y. and Kang, C.S. (2014) Causative Agents of Kikuchi-Fujimoto Disease (Histiocytic Necrotizing Lymphadenitis): A Meta-Analysis. *International Journal of Pediatric Otorhinolaryngology*, **78**, 1890-1897. <https://doi.org/10.1016/j.ijporl.2014.08.019>
- [10] Pepe, F., Disma, S., Teodoro, C., Pepe, P. and Magro, G. (2016) Kikuchi-Fujimoto Disease: A Clinicopathologic Update. *Pathologica*, **108**, 120-129.
- [11] Sopena, B., Rivera, A., Chamorro, A., Freire, M., Alende, V., Seco, E., González-Gay, M.A. and González-Quintela, A. (2017) Clinical Association between Kikuchi's Disease and Systemic Lupus Erythematosus: A Systematic Literature Review. *Seminars in Arthritis and Rheumatism*, **47**, 46-52. <https://doi.org/10.1016/j.semarthrit.2017.01.011>
- [12] Tanaka, T., Ohmori, M., Yasunaga, S., Ohshima, K., Kikuchi, M. and Sasazuki, T. (1999) DNA Typing of HLA Class II Genes (HLA-DR, -DQ and -DP) in Japanese Patients with Histiocytic Necrotizing Lymphadenitis (Kikuchi's Disease). *Tissue Antigens*, **54**, 246-253. <https://doi.org/10.1034/j.1399-0039.1999.540305.x>
- [13] Han, H.J., Lim, G.Y., Yeo, D.M. and Chung, N.G. (2009) Kikuchi's Disease in Children: Clinical Manifestations and Imaging Features. *Journal of Korean Medical Science*, **24**, 1105-1109. <https://doi.org/10.3346/jkms.2009.24.6.1105>
- [14] Seong, H., Jeong, Y.H., Lee, W.J., Kim, J.H., Kim, J.H., Ahn, J.Y., Jeong, S.J., Choi, J.Y., Park, Y.S., Yeom, J.S., Song, Y.G., Cho, A. and Ku, N.S. (2021) Splenic Uptake on FDG PET/CT Correlates with Kikuchi-Fujimoto Disease Severity. *Scientific Re-*

- ports, **11**, Article No. 10836. <https://doi.org/10.1038/s41598-021-90350-z>
- [15] Fidai, S.S., Cipriani, N.A. and Ginat, D.T. (2019) Histiocytic Necrotizing Lymphadenitis Involving the Neck: Radiology-Pathology Correlation. *Head and Neck Pathology*, **13**, 648-651. <https://doi.org/10.1007/s12105-018-0936-0>
- [16] Sukswai, N., Jung, H.R., Amr, S.S., Ng, S.B., Sheikh, S.S., Lyapichev, K., El Hussein, S., Loghavi, S., Agbay, R.L.M.C., Miranda, R.N., Medeiros, L.J. and Khoury, J.D. (2020) Immunopathology of Kikuchi-Fujimoto Disease: A Reappraisal Using Novel Immunohistochemistry Markers. *Histopathology*, **77**, 262-274. <https://doi.org/10.1111/his.14050>
- [17] Hutchinson, C.B. and Wang, E. (2010) Kikuchi-Fujimoto Disease. *Archives of Pathology & Laboratory Medicine*, **134**, 289-293. <https://doi.org/10.5858/134.2.289>
- [18] Yoo, I.H., Na, H., Bae, E.Y., Han, S.B., Lee, S.Y., Jeong, D.C. and Kang, J.H. (2014) Recurrent Lymphadenopathy in Children with Kikuchi-Fujimoto Disease. *European Journal of Pediatrics*, **173**, 1193-1199. <https://doi.org/10.1007/s00431-014-2306-6>
- [19] Yalcin, S., Toprak, S.K., Erismis, B., Altundag, O., Ozdemir, H. and Topcuoglu, N. (2011) Management of Kikuchi-Fujimoto Disease Using Glucocorticoid: A Case Report. *Case Reports in Medicine*, **2011**, Article ID: 230840. <https://doi.org/10.1155/2011/230840>
- [20] Lin, D.Y., Villegas, M.S., Tan, P.L., Wang, S. and Shek, L.P. (2010) Severe Kikuchi's Disease Responsive to Immune Modulation. *Singapore Medical Journal*, **51**, E18-E21.
- [21] Vithoosan, S., Karunarathna, T., Shanjeeban, P., Piranavan, P., Matthias, T., Gamlaksha, D., Liyadipita, A. and Kulatunga, A. (2019) Kikuchi-Fujimoto Disease Associated with Systemic Lupus Erythematosus Complicated with Hemophagocytic Lymphohistiocytosis: A Case Report. *Journal of Medical Case Reports*, **13**, Article No. 173. <https://doi.org/10.1186/s13256-019-2100-1>
- [22] Byun, J.H., Park, S.E., Nam, S.O., Kim, Y.A., Kim, Y.M., Yeon, G.M. and Lee, Y.J. (2018) Three Children of Meningoencephalitis with Kikuchi Necrotizing Lymphadenitis. *Brain & Development*, **40**, 251-255. <https://doi.org/10.1016/j.braindev.2017.09.009>