

# Central Retinal Vein Occlusion in Healthy Young Adults Following COVID-19 Vaccination: Case Series

Shah-Noor Hassan<sup>1</sup>, Shahnaz Begum<sup>2</sup>, Nawreen Binte Anwar<sup>1</sup>, Nirupam Chowdhury<sup>1</sup>, Basil Anwar<sup>3</sup>

<sup>1</sup>Department of Ophthalmology, Bangabandhu Sheikh Mujib Medical University, Dhaka, Bangladesh

<sup>2</sup>Department of Ophthalmology, BIRDEM General Hospital & Ibrahim Medical College, Dhaka, Bangladesh

<sup>3</sup>Department of Ophthalmology, Dr. Sirajul Islam Medical College & Hospital Ltd., Dhaka, Bangladesh

Email: snawreen18@gmail.com

**How to cite this paper:** Hassan, S.-N., Begum, S., Anwar, N.B., Chowdhury, N. and Anwar, B. (2023) Central Retinal Vein Occlusion in Healthy Young Adults Following COVID-19 Vaccination: Case Series. *Open Journal of Ophthalmology*, 13, 360-370.

<https://doi.org/10.4236/ojoph.2023.134035>

**Received:** September 13, 2023

**Accepted:** November 13, 2023

**Published:** November 16, 2023

Copyright © 2023 by author(s) and Scientific Research Publishing Inc.

This work is licensed under the Creative Commons Attribution International License (CC BY 4.0).

<http://creativecommons.org/licenses/by/4.0/>



Open Access

## Abstract

Our aim is to report 4 cases of central retinal vein occlusion following COVID-19 vaccine administration. In this case series, 4 patients between 23 - 32 years of age presented to us with unilateral central retinal vein occlusion after 2 - 15 days of getting vaccinated against COVID-19. One patient was a known case of hypertension and 1 was hypothyroid. All the patients had disc swelling, flame shaped haemorrhages, dilated and tortuous blood vessels in the retina. One patient had cystoid macular edema and was treated with intravitreal ranibizumab. As there were no positive systemic risk factors or incidents, COVID-19 vaccines might have an association with the central retinal vein occlusion in these cases.

## Keywords

COVID-19 Vaccine, Central Retinal Vein Occlusion, SARS-CoV-2

## 1. Introduction

The World Health Organization (WHO) declared COVID-19 a Public Health Emergency of International Concern on 30 January 2020 and a pandemic on 11 March 2020. Since then COVID-19 virus (SARS-CoV-2) has caused 6.16 million deaths worldwide up until 4 April 2022. To reduce the spread, mortality and morbidity rate, vaccines are being administered worldwide. Globally, as of 4 April 2022, a total of 11,250,782,214 vaccine doses have been administered. Bangladesh began the administration of COVID-19 vaccines on 27th January 2021, while mass vaccination started on 7th February 2021. Since then, mRNA vac-

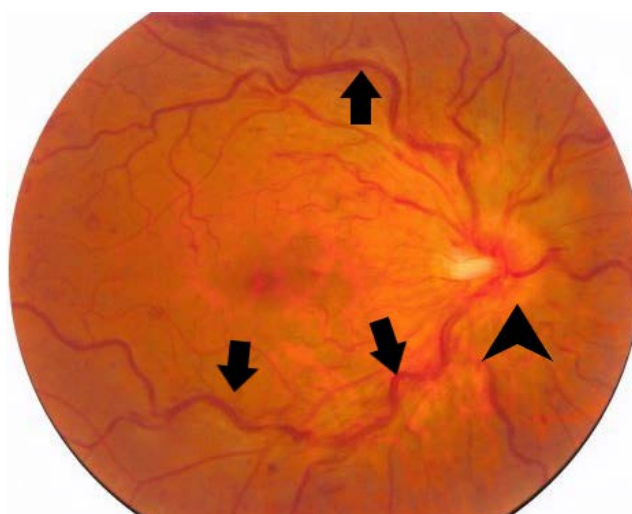
cines (BNT162b2, Pfizer-BioNTech; mRNA-1273, Moderna), vector vaccine (ChAdOx1 nCoV-19/ AZD1222, Oxford-AstraZeneca), and whole virus vaccines (BBIBP-CorV, Sinopharm) are being administered in Bangladesh. In Bangladesh 69.7% (more than 115 million) have been fully vaccinated and 77.9% have received at least 1 dose up until 6 April, 2022 [1] [2].

Many studies have reported cranial nerve palsies, acute macular neuro-retinopathy, central serous retinopathy, thrombosis, uveitis, multiple evanescent white dot syndrome, Vogt-Koyanagi-Harada disease reactivation, and new-onset Graves' Disease following COVID-19 vaccination [3]. In the case series we are reporting 4 cases of central retinal vein occlusion following the administration of COVID-19 vaccine in apparently healthy young adults. Our aim is to notify the ophthalmologists about the probable association of retinal vein occlusion following vaccination.

## 2. Case Series

### 2.1. Case 1

A 31-year-old female physician presented to the Ophthalmology out-patient department with the history of dimness of vision in right eye for about 6 weeks. She was hypertensive (on Losartan Potassium 50 mg once daily), non-diabetic and gave no other history of chronic disease. She received her first dose of COVISHIELD vaccine (ChAdOx1-S-AZD1222) against SARS-CoV-2 virus about 15 days before this incident. On physical examination, her blood pressure was 145/90 mm of Hg. Her visual acuity for distance was 6/12 OD and 6/9 OS unaided and with  $-0.75$  D Sph 6/6 partial OD and 6/6 OS. On examination, her anterior segment and IOP was normal in both eyes. Fundus examination (**Figure 1**) showed, dilated and tortuous blood vessels, disc swelling and normal foveal reflex in right eye. Both eyes had myopic fundus with no offensive peripheral lesion.



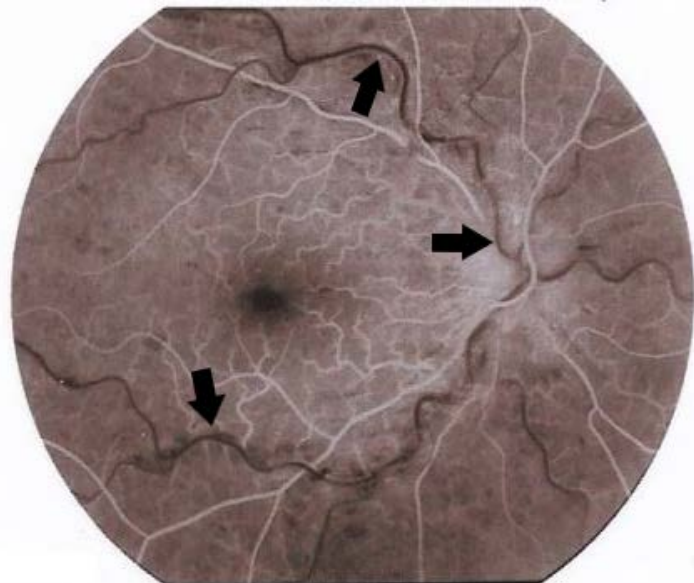
**Figure 1.** Color Fundus photograph showing dilated and tortuous retinal vessels (arrows), disc swelling (arrowhead) in right eye.

Fundus fluorescein angiography of right eye (**Figure 2**) showed, dilated capillaries, arterial and arterio-venous filling delay, few capillary non-perfused areas in all quadrants with normal Foveal Avascular Zone (FAZ). OCT macula of right eye showed no cystoid macular edema. She was diagnosed as a case of impending or resolving central retinal vein occlusion in right eye. Her hematological work-up including CBC, ESR, Prothrombin time, APTT, fasting lipid profile, CRP, Protein C, Protein S, Fasting and post-prandial blood sugar all were within normal limits. RT-PCR for COVID-19 was negative. So, she was referred to an internist for control of her blood pressure and was advised for life style modification. She observed weekly for neo-vessels in iris, angle and fundus evaluation. After 5 months there was resolution of the retinal haemorrhages without any change in the macula. No late complications of central retinal vein occlusion have appeared yet.

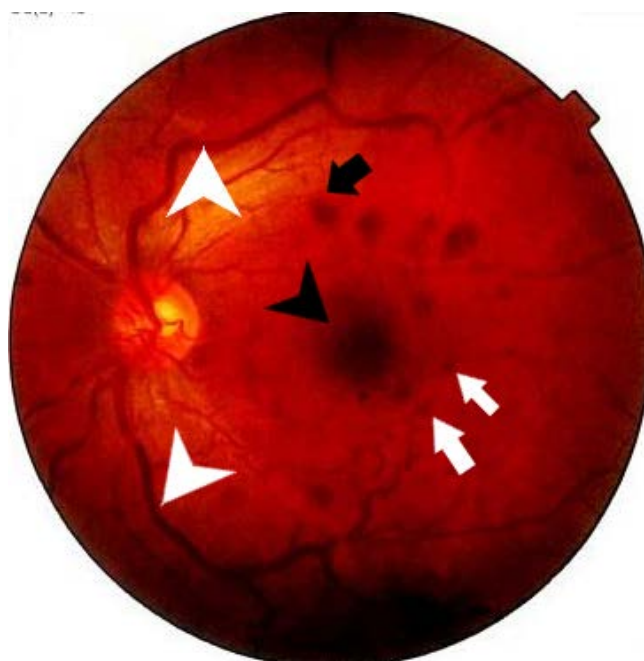## 2.2. Case 2

A 28-year-old normotensive, non-diabetic male presented with the history of seeing of black spots in his left eye for 1 day. He had no history of bleeding disorders, significant drug history or any other systemic chronic illness. He received his second dose of COVISHEILD vaccine (ChAdOx1-S-AZD1222) 5 days before presenting to us. On examination, his unaided visual acuity for distance was 6/6 OD and 6/6 partial OS and with  $-0.50$  D Cyl at  $40^\circ$  6/6 OS.

On examination, his anterior segment and IOP was normal. On fundoscopy of left eye (**Figure 3**), there was dilated and tortuous blood vessels with dot, blot and flame shaped haemorrhages in all four quadrants. Foveal reflex was normal. Right fundus was normal. His blood pressure was within normal limits. Other systemic physical examinations revealed no abnormality.



**Figure 2.** FFA of right eye showing arterio-venous filling delay (arrows) at 30 seconds.



**Figure 3.** Color fundus photograph of left eye showing dilated and tortuous blood vessels (white arrowheads) with dot (white arrows), blot (black arrow) and flame shaped haemorrhage (black arrowhead) in all four quadrants.

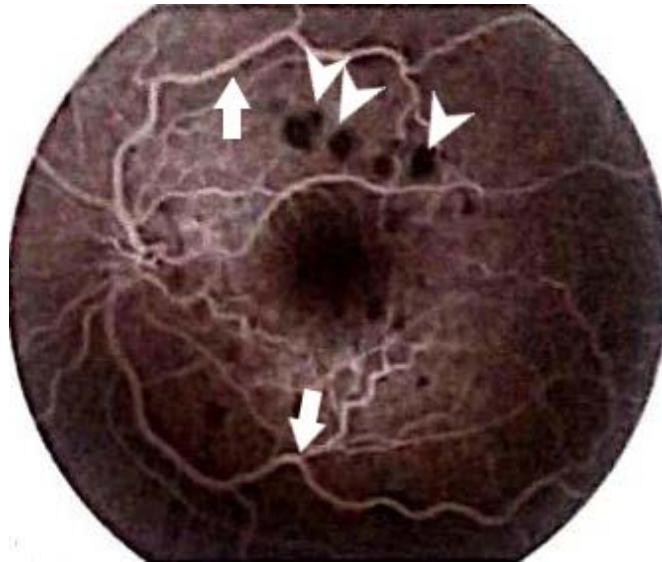
Fundus fluorescein angiogram of left eye (**Figure 4**) showed arterio-venous filling delay, blocked fluorescence due to haemorrhages and FAZ appeared normal. OCT of left macula showed no sign of cystoid macular edema. His hematological work-up showed slightly low platelet count (120,000/cu mm). His Hb%, WBC, ESR, Prothrombin time, APTT, D-dimer, fasting lipid profile, CRP, Protein C, Protein S, Fasting and post-prandial blood sugar all were within normal limits. RT-PCR for COVID-19 was negative. After excluding retinal vasculitis and blood dyscrasia, he was diagnosed as a case of non-ischaemic central retinal vein occlusion in left eye.

Patient was examined every 2 weeks for any neovascularization in the anterior or posterior segment. He was prescribed with Tablet bromazepam (3 mg) for 15 days as anxiolytic. After 6 months his visual acuity remained the same and there was resolution of the retinal haemorrhage without any change in the macula.

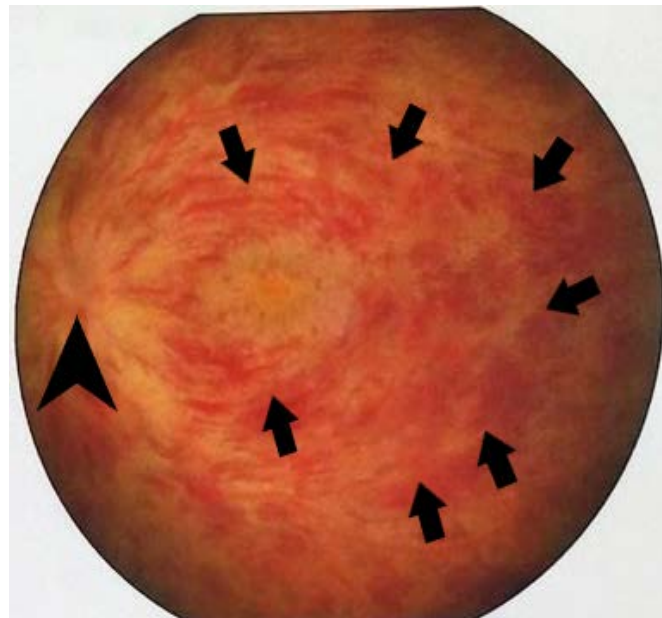
### 2.3. Case 3

A 23-year-old normotensive, non-diabetic male presented with gross reduction of vision in left eye for 3 days. He gave history of receiving first dose of Pfizer vaccine (mRNA-BNT162b2-Comirnaty) 12 days before the incident. He had no history of blood dyscrasia, smoking, any systemic medications or systemic chronic illness. His physical examination showed no abnormality. His visual acuity for distance was 6/6 OD and hand movement in OS. His IOP and anterior segment was normal. His fundus examination of left eye (**Figure 5**) revealed, disc swelling with flamed shaped haemorrhages all over the retina. Right fundus

was normal. Foveal reflex was dull. Fundus fluorescein angiogram of left eye showed, arterio-venous filling delay with few capillary non-perfused areas and hyper-fluorescence in macula suggestive of cystoid macular edema. OCT macula of left eye (**Figure 6**) showed huge cystoid macular edema (foveolar thickness = 317 microns). His CBC, ESR, Prothrombin time, APTT, Fasting lipid profile, CRP, Protein C, Protein S, Fasting and post-prandial blood sugar all were within normal limits. RT-PCR for COVID-19 was negative.

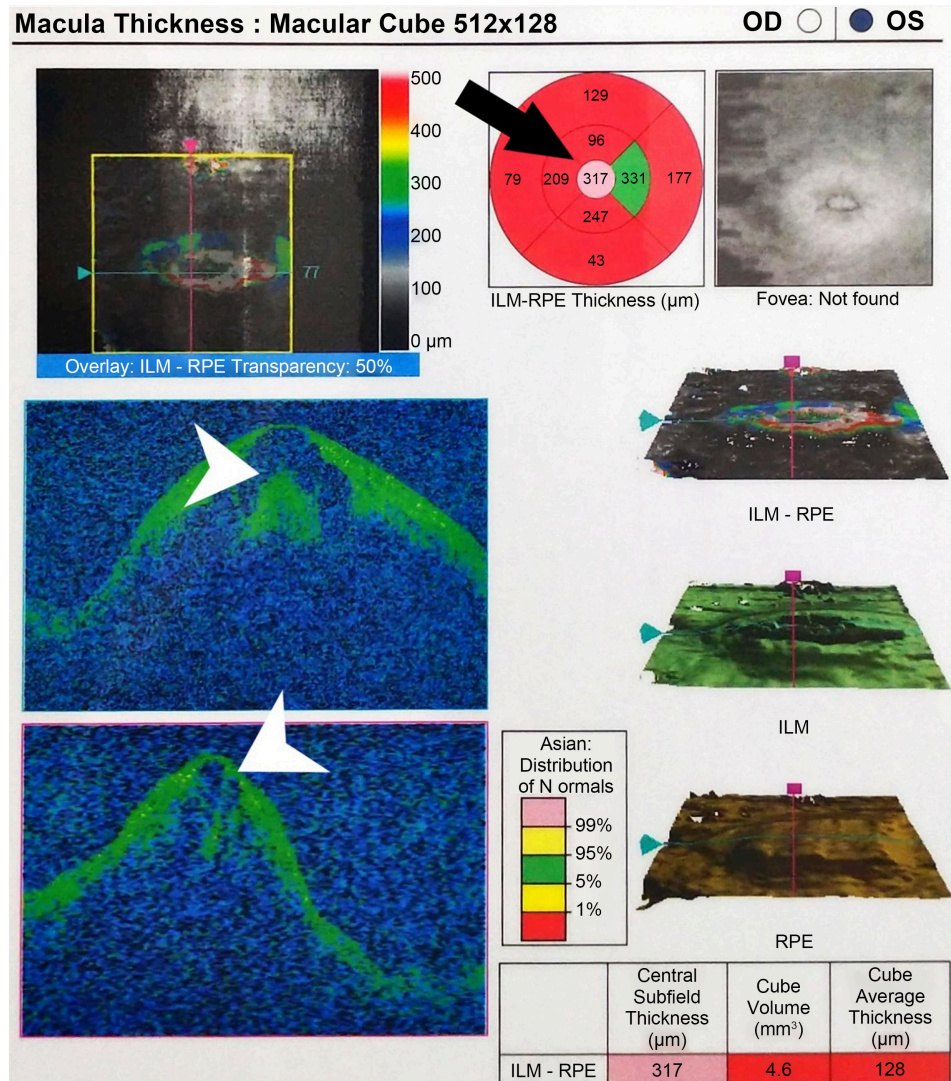


**Figure 4.** FFA of left eye showing arterio-venous filling (35 seconds) and blocked fluorescence (white arrowheads) due to haemorrhages.



**Figure 5.** Color fundus photograph of left eye showing disc swelling (arrowhead) with flamed shaped haemorrhages (arrows) all over the retina.



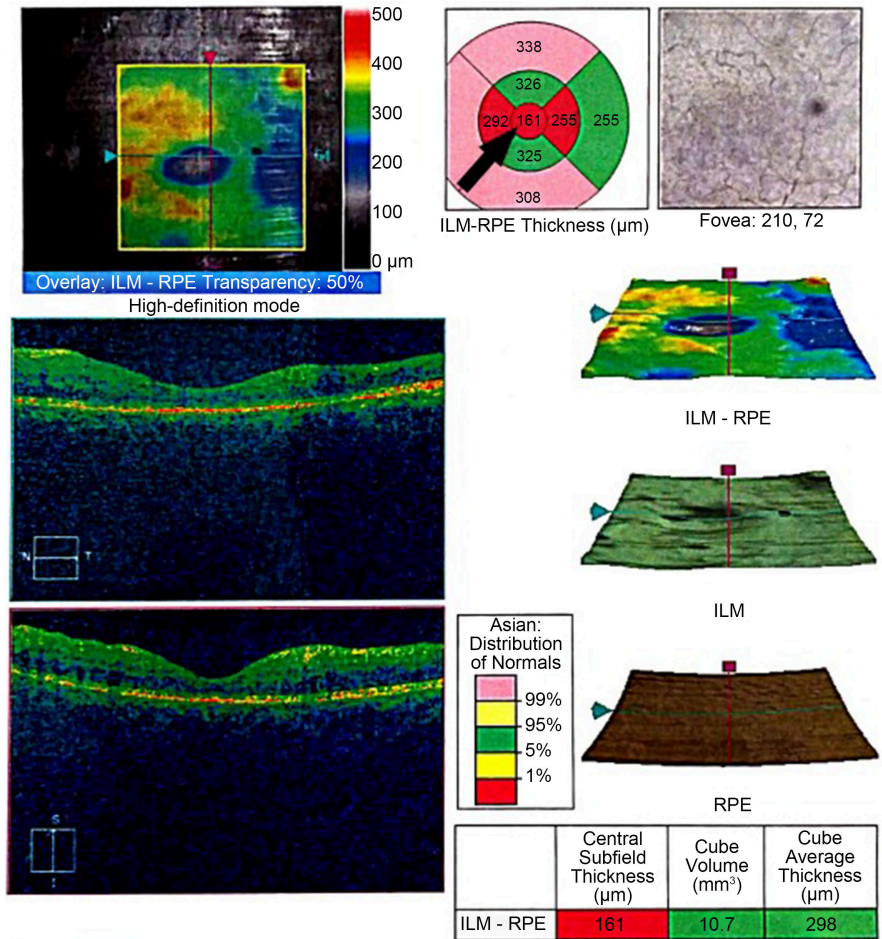


**Figure 6.** Optical Coherence Tomography of left eye showing Cystoid Macular Edema (white arrowhead). ILM-RPE thickness map is showing increased (317 microns) foveolar thickness (black arrow).

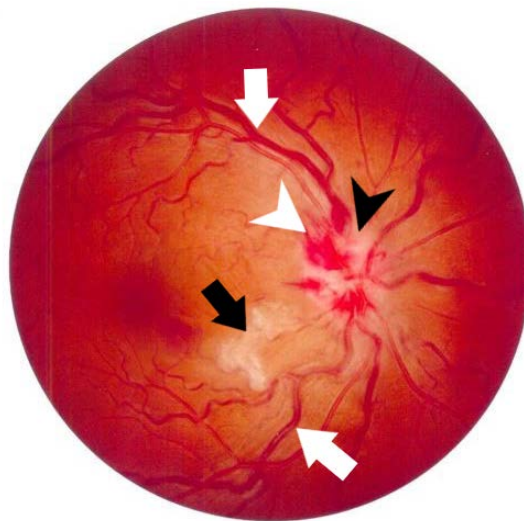
He was diagnosed with ischaemic central retinal vein occlusion of left eye and was advised with 1 dose of intra-vitreous ranibizumab (0.5 mg) every month for 3 consecutive months. One additional dose of intravitreal ranibizumab was given as cystoid macular edema did not fully resolve after 3 doses. One month after the 4<sup>th</sup> injection, his unaided visual acuity was 4/60 OS. OCT macula (**Figure 7**) showed foveolar thinning (161 microns).

#### 2.4. Case 4

A 32-year-old normotensive, non-diabetic, hypothyroid female (on Tab. Levothyroxine 50 mcg daily) presented to the Ophthalmology out-patient department with the history of slight blurring of vision for 2 days in her right eye. She gave no other history of trauma, blood dyscrasia, pregnancy or any other chronic diseases. She received her 2nd dose of COVISHIELD vaccine (ChAdOx1-S-AZD1222)



**Figure 7.** Optical Coherence Tomography of macula (left eye) showing thinning of fovea (161 microns) (arrow) after 4 doses of intra-vitreous ranibizumab.



**Figure 8.** Color fundus photograph of right eye showing disc swelling (black arrowhead) with flamed shaped haemorrhages (white arrowhead), cotton wool spots (black arrow) and tortuous retinal blood vessels (white arrow).

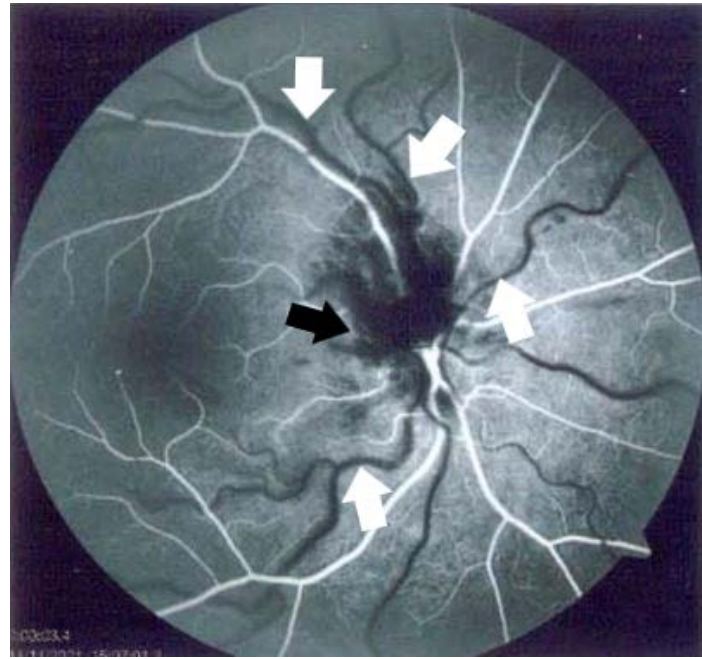
against SARS-CoV-2 virus about 2 days before this incident. Her physical examination showed no abnormality. Her unaided visual acuity for distance was 6/6 in both eyes. IOP and anterior segment were normal. Fundus examination of right eye (**Figure 8**) revealed, disc swelling with flame shaped haemorrhages, cotton wool spots and tortuous retinal blood vessels. Left fundus was normal. Fundus fluorescein angiogram of right eye (**Figure 9**) showed, arterio-venous filling delay (37 sec) with normal foveal avascular zone. OCT macula of right eye (**Figure 10**) showed normal contour of the fovea with no sign of cystoid macular edema (foveolar thickness = 221 microns). Her haematological profile showed borderline platelet count (140,000/cu mm). Her Hb%, WBC count, ESR, Prothrombin time, APTT, fasting lipid profile, CRP, Protein C, Protein S, D-dimer, Fasting and post-prandial blood sugar all were within normal limits. RT-PCR for COVID-19 was negative. After excluding blood dyscrasia and vasculitis, she was diagnosed with non-ischaemic central retinal vein occlusion. Patient was examined every 2 weeks for any neovascularization in the anterior or posterior segment. After 6 months her visual acuity did not deteriorate and there was resolution of the disc haemorrhage without any change in the macula.

### 3. Discussion

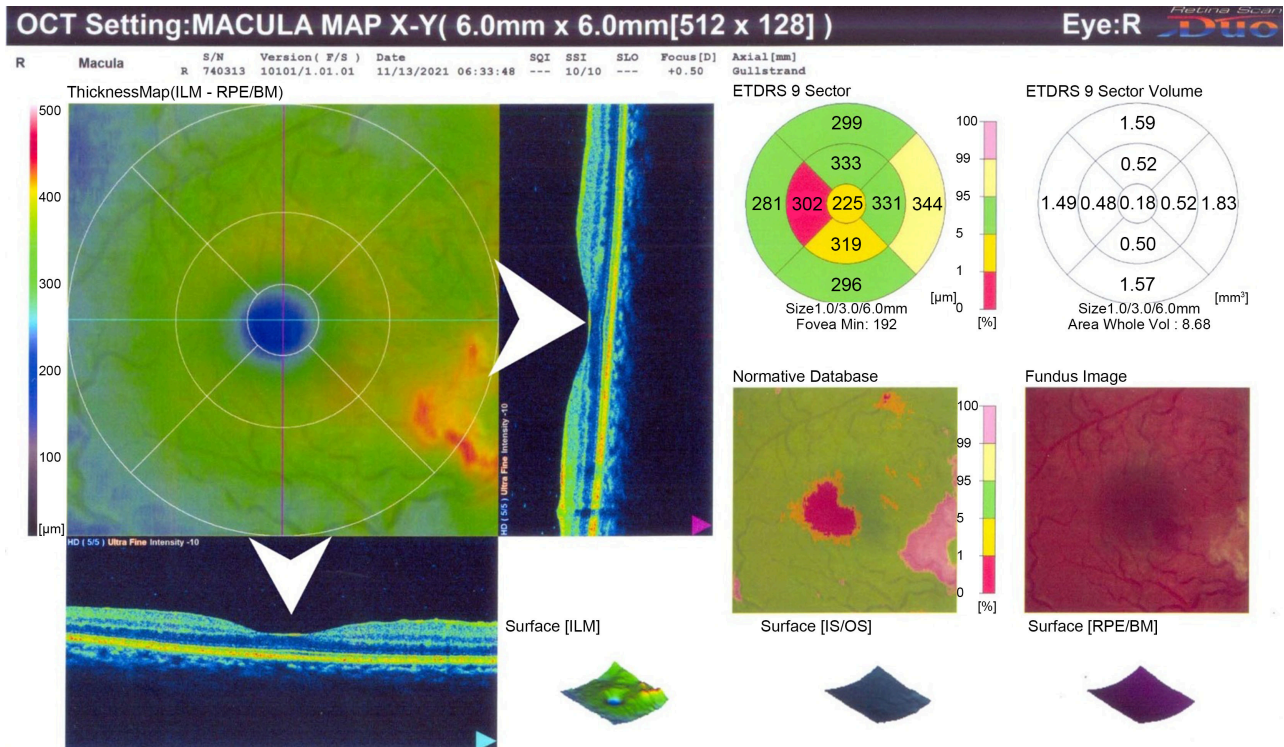
The risk factors of retinal vein occlusion include cardiovascular disease, hypertension, glaucoma, diabetes mellitus, hyperlipidaemia, thrombophilia, history of previous thrombosis, or family history of thrombosis etc. Usually, retinal vein occlusion occurs in older population. But, hypercoagulable states like hyperhomocysteinemia and circulating antiphospholipid antibodies were proved to be associated with CRVO under 56 years of age [4]. Thromboembolic events have been reported after SARS-COV-2 vaccines. The intense immunological response evoked by the second dose of vaccine could be a trigger for the thrombotic event. Deep vein thrombosis has been reported in a 66-year-old woman after the second dose of the mRNA Pfizer/BioNTech vaccine. The reported patient did not have an abnormal coagulation profile, thrombocytopenia, or raised D-dimer [5].

There are recently published cases of thrombotic thrombocytopenia and cerebral VST occurring in 9 patients after receiving the adenovirus-based vaccine (AstraZeneca). Vaccination with ChAdOx1 nCov-19 can result in the rare development of immune thrombotic thrombocytopenia mediated by platelet-activating antibodies against platelet factor 4, which clinically mimics autoimmune heparin-induced thrombocytopenia [6]. In this case series, 2 patients who received ChAdOx1 nCov-19 (AstraZeneca) showed slightly low or borderline thrombocytopenia. Although the reduction of the platelet count was not significant, we believe that autoimmune thrombocytopenia might have played a role in their retinal vein occlusion. The first case of CRVO following COVID-19 vaccine was reported in October 2021. The patient was a 52-year-old male, who developed CRVO 15 days following Pfizer vaccine (mRNA-BNT162b2-Comirnaty). Similar to three of our patients, he had no known risk factors for CRVO [7].





**Figure 9.** FFA (right eye) showing delayed arterio-venous filling (white arrows) at 37 seconds and blocked fluorescence (black arrow) due to flame shaped haemorrhages & cotton wool spots.



**Figure 10.** Optical Coherence Tomography (OCT) of the macula (right eye) showing no sign of Cystoid Macular Edema (Foveolar thickness = 225 microns) (arrowhead).

A 33-year-old healthy man, 2 hours after he received one dose of COVID-19 vaccine (Pfizer-BioNTech) developed CRVO. All his thrombotic work up were

negative, no evidence of inherited thrombophilia, antiphospholipid syndrome, vasculitis, and myeloproliferative neoplasms. COVID-19 vaccine-induced immune thrombotic thrombocytopenia (VITT) was ruled out by normal platelets count, normal D-dimer, negative heparin-induced thrombocytopenia (HIT) enzyme-linked immunosorbent assay. So the authors believe that the only possible explanation for this CRVO was post-COVID pseudo-vasculitis state as a result of a viral infiltration of the endothelial cells or a hypercoagulable condition, characterized by a disseminated intravascular coagulation-like (DIC-like) [8] [9] [10]. One limitation of this case series is that, we could not do extensive investigations like hyperhomocysteinemia, antiphospholipid antibodies, anti-nuclear antibodies (ANA) to completely rule out other causes of autoimmune vasculitis. As the vein occlusions occurred within a few days of receiving vaccines, we believe that Vaccine Induced Immune Thrombotic thrombocytopenia (VITT) or vaccine induced vasculitis might have caused central retinal vein occlusion in all 4 cases.

#### 4. Conclusion

In this case series, we reported 4 different cases of central retinal vein occlusion in apparently healthy young adults after receiving COVID-19 vaccines. Authors believe the autoimmune thrombocytopenia and post-COVID pseudo-vasculitis state might have played a role in the pathogenesis of these post-vaccination events. But, further research is needed to detect the exact pathophysiology of post-vaccination retinal vein occlusion.

#### Conflicts of Interest

The authors declare no conflicts of interest regarding the publication of this paper.

#### References

- [1] (2022) WHO Coronavirus Disease (COVID-19) Dashboard. World Health Organization, Geneva. <https://covid19.who.int/>
- [2] COVID-19 Dynamic Dashboard for Bangladesh (2022) Directorate General of Health Services. <http://103.247.238.92/webportal/pages/covid19-vaccination-update.php>
- [3] Ng, X.L., Betzler, B.K., Testi, I., Ho, S.L., Tien, M., Ngo, W.K., *et al.* (2021) Ocular Adverse Events after COVID-19 Vaccination. *Ocular Immunology and Inflammation*, **29**, 1216-1224. <https://doi.org/10.1080/09273948.2021.1976221>
- [4] Lahey, J.M., Tunç, M., Kearney, J., Modlinski, B., Koo, H., Johnson, R.N., *et al.* (2002) Laboratory Evaluation of Hypercoagulable States in Patients with Central Retinal Vein Occlusion Who Are Less Than 56 Years of Age. *Ophthalmology*, **109**, 126-131. [https://doi.org/10.1016/s0161-6420\(01\)00842-9](https://doi.org/10.1016/s0161-6420(01)00842-9)
- [5] Carli, G., Nichele, I., Ruggeri, M., Barra, S. and Toso, A. (2021) Deep Vein Thrombosis (DVT) Occurring Shortly after the Second Dose of mRNA SARS-CoV-2 Vaccine. *Internal and Emergency Medicine*, **16**, 803-804. <https://doi.org/10.1007/s11739-021-02685-0>

- [6] Greinacher, A., Thiele, T., Warkentin, T.E., Weisser, K., Kyrle, P.A. and Eichinger, S. (2021) Thrombotic Thrombocytopenia after ChAdOx1 nCov-19 Vaccination. *The New England Journal of Medicine*, **384**, 2092-2101. <https://doi.org/10.1056/NEJMoa2104840>
- [7] Endo, B., Bahamon, S. and Martínez-Pulgarín, D.F. (2021) Central Retinal Vein Occlusion after mRNA SARS-CoV-2 Vaccination: A Case Report. *Indian Journal of Ophthalmology*, **69**, 2865-2866. [https://doi.org/10.4103/ijoo.IJO\\_1477\\_21](https://doi.org/10.4103/ijoo.IJO_1477_21)
- [8] Al-Abri, M., Al-Musalami, A., Al-Rawahi, B., Al-Hinai, A. and Al-Fadhil, N. (2021) Central Retinal Vein Occlusion in a Young Healthy COVID-19 Patient: A Case Report and Literature Review. *Middle East African Journal of Ophthalmology*, **28**, 199-202. [https://doi.org/10.4103/meajo.meajo\\_271\\_21](https://doi.org/10.4103/meajo.meajo_271_21)
- [9] Varga, Z., Flammer, A.J., Steiger, P., Haberecker, M., Andermatt, R., Zinkernagel, A.S., *et al.* (2020) Endothelial Cell Infection and Endotheliitis in COVID-19. *Lancet (London, England)*, **395**, 1417-1418. [https://doi.org/10.1016/S0140-6736\(20\)30937-5](https://doi.org/10.1016/S0140-6736(20)30937-5)
- [10] Tang, N., Li, D., Wang, X. and Sun, Z. (2020) Abnormal Coagulation Parameters Are Associated with Poor Prognosis in Patients with Novel Coronavirus Pneumonia. *Journal of Thrombosis and Haemostasis*, **18**, 844-847. <https://doi.org/10.1111/jth.14768>