

Erysipelas in Children: Risk Factors and Management in the Pediatric Emergency Department

Issam Taha*, Ilham Tadmori, Widade Kojmane, Moustapha Hida

Mother-Child Hospital, Hassan II University Hospital, Fez, Morocco
Email: *issam0taha@gmail.com

How to cite this paper: Taha, I., Tadmori, I., Kojmane, W. and Hida, M. (2023) Erysipelas in Children: Risk Factors and Management in the Pediatric Emergency Department. *Open Journal of Pediatrics*, 13, 914-920.
<https://doi.org/10.4236/ojped.2023.136100>

Received: October 22, 2023

Accepted: November 14, 2023

Published: November 17, 2023

Copyright © 2023 by author(s) and Scientific Research Publishing Inc. This work is licensed under the Creative Commons Attribution International License (CC BY 4.0).

<http://creativecommons.org/licenses/by/4.0/>



Open Access

Abstract

The aim of this study is to describe the epidemiological, clinical, biological profile, etiology and management of erysipelas in pediatric emergency departments. In this retrospective study carried out over a period of 12 months, we identified 20 cases of erysipelas, with an incidence of 2%, and a female predominance of 65% of cases. Age average patient age was 6 years, and the average consultation time was 5 days. The Diagnosis of erysipelas is mainly based on clinical features, including the presence of erythema associated with inflammatory signs, which were present in all cases. Satellite lymphadenopathy was observed in five cases, and fever was present in all patients. The therapeutic approach is mainly based on the administration of injectable antibiotics in children, using amoxicillin-clavulanate dose of 80 mg/kg/day in three doses.

Keywords

Erysipelas, Fever, Antibiotic Therapy, Child

1. Introduction

Erysipelas is an acute infection of the skin and subcutaneous tissue caused primarily by streptococcal bacteria, characterized by the sudden appearance of an inflammatory area accompanied by fever. The diagnosis is mainly based on clinical evaluation, although sometimes it can be difficult to distinguish it from other similar conditions (such as osteomyelitis, osteoarthritis, malignant staphylococcal disease, necrotizing fasciitis, cellulitis), due to the frequency of incomplete clinical presentations in children and infants. The lower extremities are the most common site of this infection. Additional tests have limited utility in the diagno-

sis and management of erysipelas. The treatment of erysipelas is mainly based on active antibiotic therapy directed against streptococci, using penicillin G [1].

2. Methods and Materials

This is a retrospective study covering cases of erysipelas admitted to the pediatric emergency room of the Hassan II University Hospital of Fez, over a period of 12 months, from October 1, 2021 to September 30, 2022. The data were extracted from the files computerized medical records of all patients. The inclusion criteria were defined as follows: all patients were children aged less than 15 years and presented symptoms of erysipelas on clinical examination. The information was collected using a pre-established operating sheet, and data entry was carried out automatically using Excel software. The parameters examined in this study include anamnestic, clinical, radiological, biological, therapeutic and evolutionary aspects.

3. Results

In this clinical study, we included 20 cases over a period of 12 months, which corresponds to an incidence of 20 cases per year, representing approximately 2% of all children admitted to pediatric emergencies for various pathologies. The average age of patients was 6 years and 1 month, with ages ranging from 7 months to 13 years. We observed a slight female predominance, with 65% of cases in girls, which gives a sex ratio of 0.53. The main risk factor associated with erysipelas was the presence of a portal of entry, most often in the form of a superinfected wound, observed in 13 children. Second, scratching lesions due to dermatological conditions such as chickenpox or atopic dermatitis, as well as the presence of a boil, were identified in two cases each. Additionally, an insect bite was reported in a child. For the remaining two children, no specific risk factors were identified.

The diagnosis of erysipelas is mainly based on clinical signs. It is characterized by the sudden appearance of an inflammatory plaque in the form of a warm, painful and edematous erythema, which gradually spreads over a few days. Lesions generally have well-defined boundaries with a raised margin, a feature present in all patients in this study (**Figure 1**, **Figure 2**). This condition is often accompanied by satellite lymphadenopathy, which was observed in five cases. A high fever, usually reaching 40°C on admission, was observed in all children, with figures varying between 38°C and 40°C.

The predominant location of erysipelas was in the lower limbs in 15 cases, with bilateral involvement in five children. Localization in the upper limb was observed in three cases, but no facial localization was noted in this series given its rarity. The most frequent clinical form of erythema in this work was the edematous form present in 15 cases. Four cases presented with a bullous form of the disease, while one case had a hemorrhagic presentation (**Figures 3(a)-(c)**) no cases of the necrotic form were recorded in this study. The duration of symptom

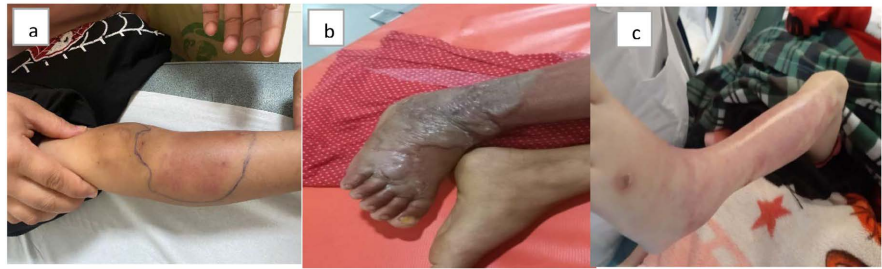

Figure 1. Photos (a, b, c): Images of erysipelas in children in our series.

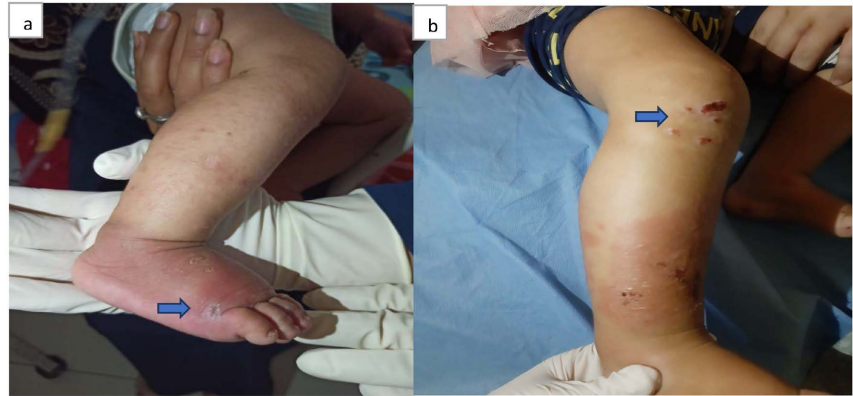


Figure 2. Localized erysipelas Lower limb with portal of entry (Images a, b, blue arrow).

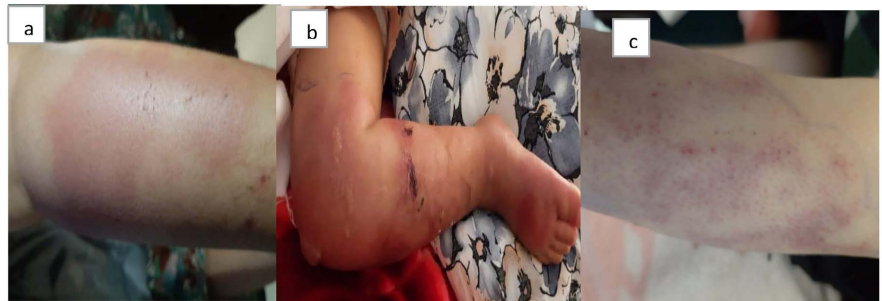

Figure 3. Photos of patients in our series showing the different types of erysipelas: (a) Erythematous appearance; (b) Bullous appearance; (c) Purpuric appearance.

progression before hospitalization varied between 2 and 7 days. Biologically, a blood analysis revealed leukocytosis predominantly neutrophils (PNN) with values varying between 13,500 and 22,400 elements/uL in 15 patients. C-reactive protein (CRP) was elevated in 17 children, with values ranging from 45 mg/dL to 130 mg/dL. Three children had negative CRP, probably due to taking antibiotics before admission.

Regarding ultrasound assessments, they were carried out in 13 children, revealing the presence of abscesses in two cases and which required surgical drainage.

The therapeutic approach is mainly based on the administration of antibiotics intravenously in children, using amoxicillin-clavulanic acid at a dose of 80 mg/kg/day in three doses, with a transition to administration orally after clinical

and biological improvement. In three cases (a 7-month-old infant and two children with an abscessed collection), an aminoglycoside was added to the treatment. In addition, surgical treatment was indicated in two cases. The average length of hospitalization was 5.1 days, with a variation ranging from two days to 11 days.

The evolution was favourable in 17 children (**Figure 4**) with apyrexia obtained within a period varying between 24 and 72 hours. However, complications were observed in three cases, of which two developed a subcutaneous abscess, and a recurrence was noted in one girl one month after stopping treatment. In the latter case, an immune deficiency assessment was requested to investigate the reasons for the recurrence.

4. Discussion

Erysipelas is an acute infection of the skin and subcutaneous tissues, remarkable for its rarity in children and infants [1]. In France, pediatric cases are sporadic, with no notable increase in frequency. The annual incidence generally remains low, affecting less than one in 100,000 individuals [2]. Recent Anglo-Saxon literature has observed a resurgence of erysipelas, accompanied by an increase in morbidity and mortality due to toxic shock syndrome and necrotizing fasciitis [3].

The gateway is often identified when it is actively sought, which is the case in 67% - 72% of cases in the literature [4] [5]. The main recognized entry points in erysipelas affecting the lower limbs are as follows: Interdigital intertrigo, skin wounds, pre-existing dermatoses such as psoriasis, boils, impetigo, particularly when they are pruritic, erosive dermatoses (eczema, chickenpox), insect or arthropod bites, venous ulcers of the lower limb [6], which is consistent with the results of this work. Other factors, notably locoregional factors such as venous insufficiency, which can facilitate dermo-hypodermal dissemination of the pathogen, are relatively rare in pediatric cases [7]. Lymphedema can manifest as primary or secondary in origin [8]. General predisposing factors include diabetes, obesity, use of nonsteroidal anti-inflammatory drugs and corticosteroid therapy, whether administered systemically or topically, nephrotic syndrome and primary or acquired immune deficiencies [9] [10]. None of the cases in this work have these risk factors.

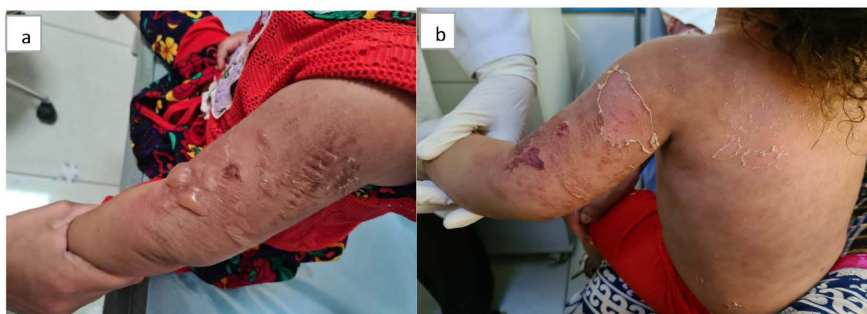

Figure 4. Erysipelas of the left MS in a 23-month-old girl showing the evolution before treatment (image a) and after (image b).

In the literature, the criteria for hospitalization were the severity of the general clinical presentation (high fever, deterioration of general condition, marked septic state, streptococcal shock leading to dysfunction of several organs). The nature of the local manifestations justifies caution (vesicles, purpura, limited tissue necrosis, extent of the lesion), or the presence of a high-risk site (such as facial involvement). And local complications (abscess, superficial tissue necrosis) requiring surgical intervention. Sometimes the presence of comorbid conditions (diabetes, obesity, immunodeficiency, infants under one year old). Hospitalization after the initiation of oral antibiotic therapy is necessary in the event of total or partial therapeutic ineffectiveness, the appearance of worrying local indicators, the absence of disappearance of the fever within 72 hours or the occurrence of complications [11] [12].

First-line antibiotic treatment options belong to the beta-lactam family. Injectable penicillin G is the reference antibiotic for the treatment of erysipelas, in the absence of contraindications. The recommended dosage for children and infants is 50,000 to 100,000 IU/kg/day intravenously in 4 to 6 divided doses per day [13] [14].

Combined treatment with amoxicillin-clavulanic acid (80 mg/kg/day in 3 doses) or cephalosporins (50 mg/kg/day) [15], which is the case of this study. In case of beta-lactam allergy, alternatives include pristinamycin (50 mg/kg/day orally in two or three doses) as a second-line treatment due to its limited gastrointestinal tolerability. Clindamycin (10 to 25 mg/kg/day orally every 6 to 8 hours, or 15 to 25/kg/day intravenously or intramuscularly in 3 to 4 administrations) or macrolides such as erythromycin (30 at 50 mg/kg/day) or roxithromycin (5 to 6 mg/kg/24h) for a duration of 10 days [16].

When afebrile is stable and local symptoms improve, one can switch to oral antibiotics administered three times daily. Commonly used antibiotics are: Amoxicillin: 80 mg/kg/day in 3 divided doses [7].

According to the authors, treatment is often initiated intravenously. In a hospital setting, beta-lactams remain the standard treatment. In the absence of bacteriological confirmation, amoxicillin-clavulanic acid remains the antibiotic of choice to ensure activity against streptococci, group A beta-hemolytic streptococci and possibly *Staphylococcus aureus*. Intravenous administration is continued until general symptoms resolve, after which oral treatment with the same agent can be initiated. In addition, some recommend active antibiotic therapy targeting *Haemophilus influenza* [17].

5. Conclusion

Erysipelas is a skin infection that requires hospitalization for intravenous antibiotic treatment and carries a significant risk of complications if not adequately managed. Implementation of primary prevention measures, by acting on risk factors such as wounds, could effectively reduce the incidence of erysipelas and its associated complications.

Conflicts of Interest

The authors declare that they have no conflict of interest in relation to this article.

References

- [1] Jait, N. (2015) Erysipèle chez l'enfant: Diagnostic et traitement. These, Université Mohamed V, Rabat.
- [2] Bernard, P. (1992) Dermo-Hypodermal Bacterial Infections: Current Concepts. *European Journal of Medicine*, **1**, 97-104.
- [3] Goettsch, W.G., Bouwes Bavinck, J.N. and Herings, R.M. (2006) Burden of Illness of Bacterial Cellulites and Erysipelas of the Leg in the Netherlands. *Journal of the European Academy of Dermatology and Venereology*, **20**, 834-835. <https://doi.org/10.1111/j.1468-3083.2006.01657.x>
- [4] Kacem, I., Habboul, Z., Kortas, H., Guedria, A., Mejaouel, H., Hmidi, N., Mlika, A., Khammeri, S. and Ben Helel, K. (2012) Erysipèle Du Nourrisson Et De L'enfant: À propos de 30 cas Service de pédiatrie de l'hôpital régional de Kairouan.
- [5] Douhi, Z., Meziane, M., Bouzidi, H., Amraoui, N., Gallouj, S., Mikou, O., Mernissi, F. and Hida, M. (2018) Erysipèle chez l'enfant: À propos de 11 cas pédiatriques Service de dermatologie-vénérologie, CHU Hassan II Fès, Maroc. La société Marocaine de dermatologie pédiatrique. Le congrès national de dermatologie pédiatrique. Les 16-17. <http://www.smdermato.org/ancien%20siteweb/revue3/RMD%203.pdf>
- [6] Del Guidice, P., Tattevin, P. and Etienne, J. (2012) Infections à *Staphylococcus aureus* résistants à la meticilline communautaires. *La Presse Médicale*, **41**, 713-720. <https://doi.org/10.1016/j.lpm.2011.10.022>
- [7] Crickx, B., Chevron, F., Sigal-Nahum, M., Bilet, S., Faucher, F., Picard, C., et al. (1991) Érysipèle: Données épidémiologiques cliniques et thérapeutiques. *Annales de Dermatologie et de Vénérologie*, **118**, 11-16.
- [8] Lorette, G., Vaillant, L. and Baulieu, F. (2001) Lymphœdèmes de l'enfant. *Annales de Dermatologie et de Vénérologie*, **128**, 674-676.
- [9] Dupuy, A., Benchikhi, H., Roujeau, J.C., Bernard, P., Vaillant, L., Chosidow, O., et al. (1999) Risk Factors for Erysipelas of the Leg (Cellulitis): Case-Control Study. *British Medical Journal*, **318**, 1591-1594. <https://doi.org/10.1136/bmj.318.7198.1591>
- [10] Mokni, M., Dupuy, A., Denguezli, M., Dhaoui, R., Bouassida, S., Amri, M., et al. (2006) Risk Factors for Erysipelas of the Leg in Tunisia: A Multicenter Case-Control Study. *Dermatology*, **212**, 108-112. <https://doi.org/10.1159/000090649>
- [11] Jégou, J., Hansmann, Y., Chalot, F., Roger, M., Faivre, B., Granel, F., et al. (2002) Hospitalization Criteria for Erysipelas: Prospective Study in 145 Cases. *Annales de Dermatologie et de Vénérologie*, **129**, 375-379.
- [12] Moulin, F., Quinet, B., Raymond, J., et al. (2008) Propositions thérapeutiques pour le traitement des infections cutanées bactériennes. *Archives de Pédiatrie*, **15**, S62-S67. [https://doi.org/10.1016/S0929-693X\(08\)74218-0](https://doi.org/10.1016/S0929-693X(08)74218-0)
- [13] Ronnen, M., Suster, S., Schewach-Millet, M. and Modan, M. (1985) Erysipelas. Changing Faces. *International Journal of Dermatology*, **24**, 169-172. <https://doi.org/10.1111/j.1365-4362.1985.tb05750.x>
- [14] Chartier, C. and Grosshans, E. (1990) Erysipelas. *International Journal of Dermatology*, **29**, 459-467. <https://doi.org/10.1111/j.1365-4362.1990.tb04833.x>
- [15] Larru, B. and Gerber, J.S. (2014) Cutaneous Bacterial Infections Caused by *Staphy-*

Staphylococcus aureus and *Streptococcus pyogenes* in Infants and Children. *Pediatric Clinics of North America*, **61**, 457-478. <https://doi.org/10.1016/j.pcl.2013.12.004>

- [16] Daniel, R. (1991) Azithromycin, Erythromycin and Cloxacillin in the Treatment of Infections of Skin and Associated Soft Tissues. *Journal of International Medical Research*, **19**, 433-435. <https://doi.org/10.1177/030006059101900602>
- [17] Pichichero, M.E. (2005) A Review of Evidence Supporting the American Academy of Pediatrics Recommendation for Prescribing Cephalosporin Antibiotics in Penicillin-Allergic Patients. *Pediatrics*, **115**, 1048-1057. <https://doi.org/10.1542/peds.2004-1276>