

Undifferentiated Arthritis Revealing Cogan's Disease

Paul Eloundou¹, Aly Badra Kamissoko², Francine Same Bebey¹, Marina Sanda²,
Al Mâmy Aboubakar³, William Nguekou⁴, Abèni Faouziyath Yaya¹, Mireille Yomba⁴,
Severin Noubissi⁴

¹Faculty of Medicine and Pharmaceutical Sciences, University of Douala, Douala, Cameroon

²Faculty of Health Sciences and Techniques, Gamal Abdel Nasser University of Conakry, Conakry, Guinea

³Faculty of Medicine, University of Ngaoundéré, Garoua, Cameroon

⁴Cite verte District Hospital, Yaoundé, Cameroon

Email: eloundouonomo@yahoo.fr

How to cite this paper: Eloundou, P., Kamissoko, A.B., Bebey, F.S., Sanda, M., Aboubakar, A.M., Nguekou, W., Yaya, A.F., Yomba, M. and Noubissi, S. (2022) Undifferentiated Arthritis Revealing Cogan's Disease. *Open Journal of Rheumatology and Autoimmune Diseases*, 12, 29-34.

<https://doi.org/10.4236/ojra.2022.121004>

Received: August 23, 2021

Accepted: January 8, 2022

Published: January 11, 2022

Copyright © 2022 by author(s) and Scientific Research Publishing Inc.

This work is licensed under the Creative Commons Attribution International License (CC BY 4.0).

<http://creativecommons.org/licenses/by/4.0/>



Open Access

Abstract

Background: Cogan's syndrome is a rare autoimmune vasculitis (less than 300 cases described in the literature) characterized in its typical form by cochleovestibular involvement, interstitial keratitis, and an inflammatory involvement of large vessels. It is frequently accompanied by general signs and cardio-vascular, rheumatologic, and digestive complications. Its management is essentially based on the use of corticosteroids and immunosuppressants. The outcome of the treatment, even if rapid, does not always avoid functional complications. This disease is probably under-diagnosed in Africa. **Objective:** The objective of this study was to report a case of Cogan syndrome in sub-Saharan Africa. **Case report:** A 78 year old black African female patient presented with arthritis of the left knee without fever. The examination also revealed a bilateral deafness of rapidly progressive onset. The patient was known to be diabetic and hypertensive, and was regularly monitored. The biology revealed an inflammatory syndrome and an inflammatory joint puncture fluid. Pure tone audiometry confirmed a 77% hearing loss. The ophthalmological examination revealed stromal oedema and hypertensive retinopathy of Kendall stage III. The rheumatological evolution was good under methylprednisolone and methotrexate, but the deafness persisted. The occurrence of a fever on day 12 of treatment required further investigations (blood culture, PCR-Covid 19 test, cytobacteriological examination of sputum, thoracic CT). The evolution was unfavourable with the death of the patient. **Conclusion:** Cogan's disease is a rare inflammatory disease. Its diagnosis and management are multidisciplinary. The treatment can be disappointing.

Keywords

Cogan's Syndrome, Arthritis, Non-Syphilitic Interstitial Keratitis, Bilateral Deafness

1. Introduction

Cogan's syndrome also known as Cogan's disease is a systemic vasculitis. It is a very rare inflammatory condition. Its clinical presentation often combines non-syphilitic ophthalmologic and cochleovestibular involvement [1] [2]. In its atypical form, cochleovestibular involvement may occur more than two years before or after ocular involvement [3]. Its signs are similar to those seen in Menière's disease [4]. Cogan's syndrome is frequently accompanied by general signs and cardiovascular, rheumatologic, and digestive complications [5]. Frank arthritis, myalgia and arthralgia can be found in about one third of patients with this vasculitis [6]. The cause of Cogan's disease is still unknown. Like many systemic diseases, an infectious cause has been suggested [5] [7] but studies conducted to identify an infectious agent have been inconclusive [8] [9]. To date, there are no specific antibodies pathognomonic for this condition, nor is it easy to identify vasculitis lesions involving the inner ear on histopathology [5]. This very rare inflammatory disease affects young adults by predilection, but paediatric and late-onset forms have already been described [10] [11] [12]. There appears to be no gender or race predilection [7], although no case has been reported in an African subject. Cogan syndrome is probably underestimated. Diagnostic difficulties make it difficult to identify less severe forms of the disease [4]. Treatment is not yet clearly codified, as the disease itself is not common. However, therapeutic data from small series support the use of corticosteroids and immunosuppressants [5] [7]. The outcome of treatment, even if rapid, does not always prevent functional complications. This study reports the case of a black African woman with Cogan's disease. To our knowledge, this is the first case reported in black Africa.

2. Case Presentation

A 78-year-old black African woman consulted for arthritis of the left knee, which had been evolving for a week without any quantified fever. At the same time, she had bilateral deafness without taking any ototoxic medication, and without prodrome. Her history included systolic and diastolic high blood pressure, well-balanced type 2 diabetes, and no known microcrystalline arthropathy or other inflammatory rheumatism. The patient was receiving metformin at a rate of 2 g/24 hours and amlodipine at 10 mg/day for her chronic conditions. Rheumatologic examination revealed arthritis of the left knee with moderate synovial effusion without satellite adenopathy. The contralateral joints above and below were otherwise unremarkable. Otosopic examination showed a normal pinna without

pain on tragus pressure. The eardrum was macroscopically normal, and no signs of inflammation were found. The paraclinical examinations revealed a non-specific biological inflammatory syndrome (erythrocyte sedimentation rate at 70 mm/h, C reactive protein at 64 mg/l, and electrophoretic profile of inflammatory type). The complete blood count showed a hyperleukocytosis of 11,000 with granulocytic predominance. The blood culture was sterile. Viral serologies (HIV, HCV and HBV) were negative. The syphilitic serology was negative. The liver and kidney functions were normal and blood sugar level was 1 g/l with a glycosylated haemoglobin level of 7%. Uricemia was 54 mg/l. Rheumatoid factor, anti-CCP antibody, antinuclear factors, ANCA and cryoglobulin were negative. The joint fluid was inflammatory type without crystals (7600 white blood cells, 96% neutrophils and 4% lymphocytes). Direct examination and culture of the fluid did not show any germs. Pure tone audiometry confirmed a 77% bilateral hearing loss (**Figure 1**).

Ophthalmologic examination showed a stromal oedema and fine retro-descemetic precipitates in favour of an interstitial keratitis (**Figure 2**).

There was a hypertensive retinopathy stage III of Kendall, no diabetic retinopathy. Comparative radiography of the knees in front and axial at 30° revealed a discrete bilateral medial femorotibial pinch without a calcium border. Brain MRI did not detect any signal abnormality or endolabyrinthine morphology, nor was there any ischaemia or tumor of the cerebellopontine angle. The combination of ocular and cochleovestibular involvement led to the diagnosis of Cogan's syndrome, with arthritis of the left knee as the systemic manifestation. Management consisted of methylprednisone in regressive doses starting at 1 mg/kg body weight. Methotrexate 25 mg weekly was combined with paracetamol 3 grams/day on demand. Folic acid was used at a distance from the methotrexate to limit its side effects and iterative punctures of the left knee were performed. The evolution was

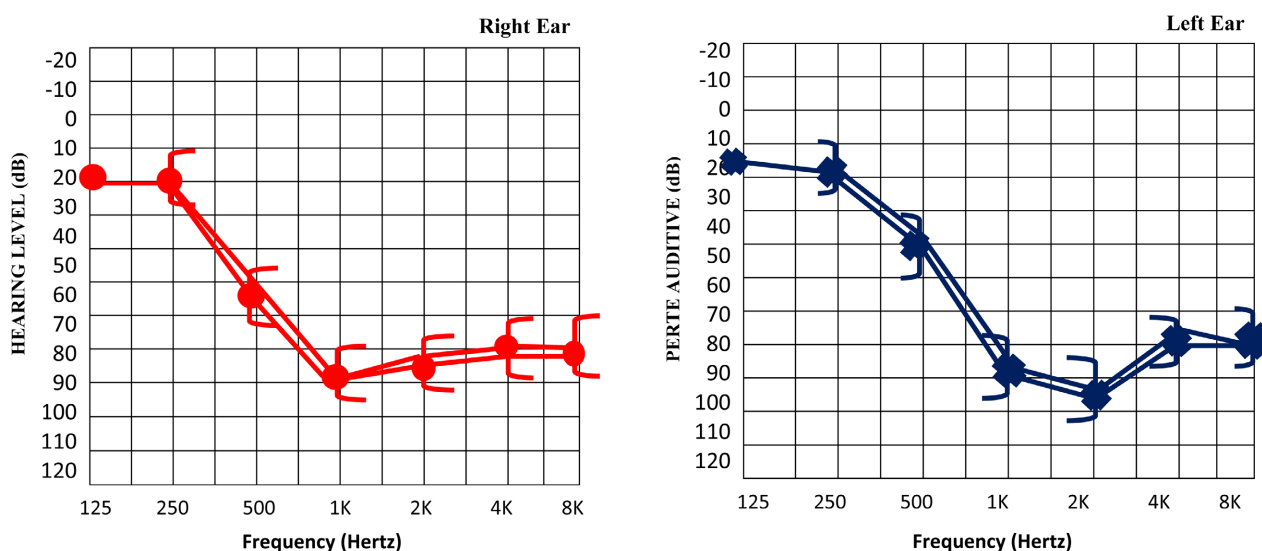


Figure 1. Pure tone audiometry (bilateral sensorineural hearing loss). Remarks: Severe Bilateral Sensorineural hearing loss. Right Ear Average hearing loss = 77.5 dB; Left Ear Average hearing loss = 76.25 dB.

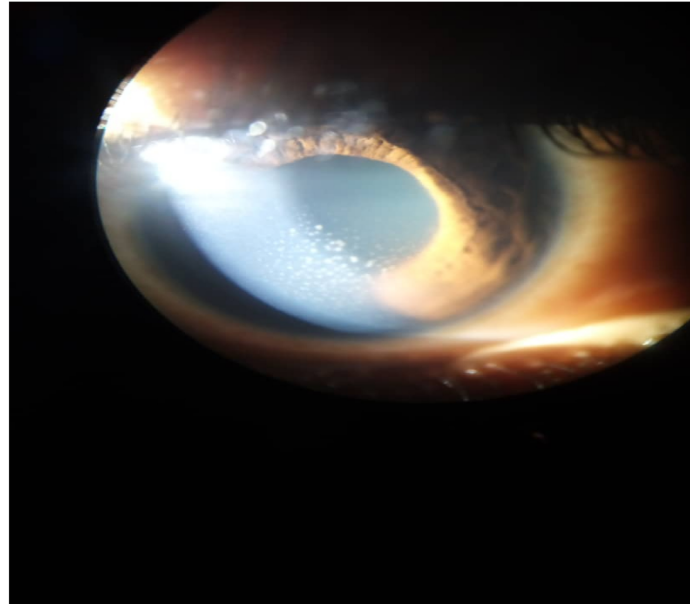


Figure 2. Retro-descemetite precipitates.

marked by the regression of knee pain and the disappearance of patellar shock but persistence of deafness. On day 12 of immunosuppressive treatment, fever, cough and general condition deteriorated. Blood cultures were negative as well as cytobacteriological examination of sputum and PCR-Covid 19 test. Chest CT scan showed an interstitial syndrome, but no biopsy could be performed. The patient died at day 17.

3. Discussion

This 78-year-old patient presented with Cogan's syndrome, which combines undifferentiated arthritis, sudden deafness, and interstitial non-syphilitic keratitis. Cogan's syndrome is classified as an autoimmune vasculitis although there is no specific antibody directed against the structures involved. This very rare condition is characterised by hypoacusis or sensorineural deafness, non-syphilitic keratitis which may associate inflammation of the vessels irrespective of the calibre, although it preferentially affects large vessels, in particular the aorta [1] [2]. The patient developed sensorineural hearing loss abruptly and bilaterally. Usually, the deafness develops progressively over a period of one to six months, usually unilateral, and may be accompanied by Menière syndrome [5]. This presentation of Cogan's syndrome in a 78 year old female patient was consistent with the description by Mazlumzadeh *et al.* [8] of the absence of Menière's disease symptoms and bilateral cochleovestibular involvement. However, the onset of deafness here was early. The ocular manifestation in this patient was an interstitial keratitis with few symptoms, in contrast to the noisy ocular manifestations often described in the literature [8] [11]. In this case, there was a known hypertensive retinopathy but no associated uveitis or scleritis, making the ocular involvement typical of Cogan disease. Gluth *et al.* reported 46 cases of interstitial keratitis in a

series of 60 cases of Cogan disease [10]. The gonarthrits found in this case is a known manifestation of Cogan disease. Frank arthritis, myalgia and arthralgia can be found in about one third of patients with Cogan syndrome [6]. Large vessel involvement is not uncommon in this inflammatory condition. It is usually manifested by non-syphilitic aortitis or aneurysmal dilatation and the thoracic or abdominal aorta are the most affected [13]. In this patient, further investigations did not reveal these lesions. The results of the paraclinical investigations corroborated the data in the literature. The biological inflammatory syndrome is almost constant [14], and antibodies and rheumatoid factors are rarely investigated because they are usually negative [7]. Normal MRI was also found in all cases at the Mayo Clinic [10] but contrasted with the literature [15] [16] where evidence of narrowing or obliteration of the vestibular labyrinth correlates with hearing prognosis. The medical treatment of Cogan's disease is based on corticosteroid therapy combined with immunosuppressive treatment. However, this treatment, even when taken early, does not always guarantee recovery and integrity or limitation of functional sequelae [9] [17]. In this case, the treatment did not lead to a favorable outcome, which corroborates the French data [4] stipulating that this is a serious disease with a poor prognosis.

4. Conclusion

Cogan's disease is a rare inflammatory disease. In its typical form, it is characterised by non-syphilitic ophthalmic involvement, cochleovestibular involvement and sometimes vasculitis. This rare condition is probably under-diagnosed. Its diagnosis and management are multidisciplinary. Treatment can be disappointing.

Consent

Informed consent was obtained from the patient son for publication of this case and accompanying images.

Conflicts of Interest

The authors declare no conflicts of interest regarding the publication of this paper.

References

- [1] Lunardi, C., Bason, C., Leandri, M., Navone, R., Lestani, M., *et al.* (2002) Autoantibodies to Inner Ear and Endothelial Antigens in Cogan's Syndrome. *The Lancet*, **360**, 915-921. [https://doi.org/10.1016/S0140-6736\(02\)11028-2](https://doi.org/10.1016/S0140-6736(02)11028-2)
- [2] Greco, A., Gallo, A., Fusconi, M., Magliulo, G., Turchetta, R., Marinelli, C., *et al.* (2013) Cogan's Syndrome: An Autoimmune Inner Ear Disease. *Autoimmunity Reviews*, **12**, 396-400. <https://doi.org/10.1016/j.autrev.2012.07.012>
- [3] Balayre, S., Cricquel, J.J., Mercie, M. and Dighiero, P. (2003) Syndrome de Cogan atypique. *Journal Français d'Ophtalmologie*, **26**, 64-68.
- [4] Perdu, J. (2004) Syndrome de Cogan. In: Emmerich, J. and Mourad, J.J., Eds., *Maladies*

rares des vaisseaux, John Libbey Eurotext, Paris, 58-62.

- [5] Mekinian, A., Pouchot, J., Zenone, T. and Fain, O. (2021). Syndrome de Cogan. *La Revue de Médecine Interne*, **42**, 269-274. <https://doi.org/10.1016/j.revmed.2020.07.007>
- [6] Haynes, B.F., Kaiser-Kupfer, M.I., Mason, P. and Fauci, A.S. (1980) Cogan Syndrome: Studies in Thirteen Patients, Long Term Follow-Up, and a Review of the Literature. *Medicine*, **59**, 426-441. <https://doi.org/10.1097/00005792-198011000-00003>
- [7] Zenone, T. (2013) Le Syndrome de Cogan. *La Presse Médicale*, **42**, 951-960. <https://doi.org/10.1016/j.lpm.2012.09.035>
- [8] Mazlumzadeh, M. and Matteson, E.L. (2007) Cogan's Syndrome: An Audiovestibular Ocular Systemic Autoimmune Disease. *Rheumatic Disease Clinics of North America*, **33**, 855-875. <https://doi.org/10.1016/j.rdc.2007.07.015>
- [9] Murphy, G., Sullivan, M.O., Shanahan, F., Harney, S. and Molloy, M. (2009) Cogan's Syndrome: Present and Future Directions. *Rheumatology International*, **29**, 1117-1121. <https://doi.org/10.1007/s00296-009-0945-0>
- [10] Gluth, M.B., Baratz, K.H., Matteson, E.L. and Driscoll, C.L. (2006) Cogan Syndrome: A Retrospective Review of 60 Patients throughout a Half Century. *Mayo Clinic Proceedings*, **81**, 483-488. <https://doi.org/10.4065/81.4.483>
- [11] Pagnini, I., Zannin, M.E., Vittadello, F., Sari, M., Simonini, G., et al. (2012) Clinical Features and Outcome of Cogan Syndrome. *The Journal of Pediatrics*, **160**, 303-307.E1. <https://doi.org/10.1016/j.jpeds.2011.07.051>
- [12] Orsoni, J.G., Zavota, L., Vincenti, V., Pellistri, I. and Rama, P. (2004) Cogan Syndrome in Children: Early Diagnosis and Treatment is Critical to Prognosis. *American Journal of Ophthalmology*, **137**, 757-758. [https://doi.org/10.1016/S0002-9394\(03\)01122-X](https://doi.org/10.1016/S0002-9394(03)01122-X)
- [13] Perdu, J. (2000) Syndrome de Cogan: Manifestations vasculaires et éléments du diagnostic. *Sang Thrombose Vaisseaux*, **12**, 111-114.
- [14] Grasland, A., Pouchot, J., Hachulla, E., Bletry, O., Papo, T., Vinceneux, P., et al. (2004) Typical and Atypical Cogan's Syndrome: 32 Cases and Review of the Literature. *Rheumatology*, **43**, 1007-1015. <https://doi.org/10.1093/rheumatology/keh228>
- [15] Casselman, J.W., Majoor, M.H.J.M. and Albers, F.W. (1994) MR of the Inner Ear in Patients with Cogan Syndrome. *American Journal of Neuroradiology*, **15**, 131-138.
- [16] Majoor, M.H.J.M., Albers, F.W.J. and Casselman, J.W. (1993) Clinical Relevance of Magnetic Resonance Imaging and Computed Tomography in Cogan's Syndrome. *Acta Oto-Laryngologica*, **113**, 625-631. <https://doi.org/10.3109/00016489309135875>
- [17] Covelli, M., Lapadula, G. and Pipitone, V. (1999) Cogan's Syndrome: Unsuccessful Outcome with Early Combination Therapy. *Clinical and Experimental Rheumatology*, **17**, 479-483.