

A Case of Multiple Idiopathic Root Resorption

Ryosuke Konishi, Arisa Mori, Takeshi Yoshida*

Department of Oral and Maxillofacial Surgery, Graduate School of Medicine, Kyoto University, Kyoto, Japan

Email: *t_yoshida91@kuhp.kyoto-u.ac.jp

How to cite this paper: Konishi, R., Mori, A. and Yoshida, T. (2023) A Case of Multiple Idiopathic Root Resorption. *Open Journal of Stomatology*, 13, 156-165.

<https://doi.org/10.4236/ojst.2023.134013>

Received: March 6, 2023

Accepted: April 25, 2023

Published: April 28, 2023

Copyright © 2023 by author(s) and Scientific Research Publishing Inc. This work is licensed under the Creative Commons Attribution International License (CC BY 4.0).

<http://creativecommons.org/licenses/by/4.0/>



Open Access

Abstract

Tooth root resorption is multifactorial, and its etiology and pathogenesis are poorly understood. Tooth root resorption is often incidentally revealed on radiographic examination. Here, we report a case of root resorption in multiple teeth of unknown etiology. Radiographic examination revealed root resorption in the cervical region of the left lateral incisor, canine, first and second premolars, and first and second molars of the mandible. Panoramic radiographs revealed no mandibular lesions that could cause tooth resorption. The patient did not wish to undergo any treatment and is currently under observation. Tooth root resorption with unknown etiology is rare, and further case collection is needed to determine the cause and treatment.

Keywords

Multiple Teeth, Cement Enamel Junction, External Cervical Resorption

1. Introduction

Resorption is a condition associated with physiological and pathological factors resulting in the loss of dentin, cement, or bone [1]. Various etiological factors for tooth root resorption have been reported, including trauma, pulpal infection, tooth bleaching, and orthodontic treatment [2] [3] [4] [5]. Despite various etiological factors, the etiology of some types of resorptions remains unclear [6] [7] [8]. Multiple idiopathic root resorption (MIRR) was first reported by Mueller [9] in 1930 and is an extremely rare disease of unknown etiology. MIRR is a rare condition in which diffuse external root resorption is observed in multiple teeth. We report a case of MIRR that was discovered incidentally during a radiological examination, along with bibliographical considerations.

2. Case Report

A 52-year-old Japanese woman was referred to our hospital for assessment of

cervical root resorption of multiple teeth. Her chief complaint was occlusal pain in the left premolar lesion. She had no significant medical or dental history. Oral examination showed no dental caries in the left mandibular teeth and mild gingivitis at the same site. The root resorption of the surface of the cervical region was not palpable through the gingival sulcus. A panoramic radiograph at the first visit showed root resorption of the cervical region of the teeth (left lateral incisor, canine, first and second premolars, and first and second molars of the mandible), and no abnormal findings were observed in the bone at the same site (**Figure 1**). We suspected a bone metabolic disease other than dental diseases and consulted the Department of Diabetes, Endocrinology, and Nutrition of our hospital. Blood test results (**Table 1**) were normal except for 1α , 25-dihydroxy vitamin D3, and tartrate-resistant acid phosphatase. 1α , 25-dihydroxy vitamin D3 was 15 ng/ml (normal, 20 ng/mL), and tartrate-resistant acid phosphatase was 597 mU/dl (normal range, 120 to 420 mU/dl). In addition, Young Adult Mean values of the lumbar spine, femur, and forearm were 54%, 59%, and 85%, respectively. The patient was diagnosed with osteoporosis; however, no systemic disease leading to root resorption was found. Based on the findings, this case was diagnosed as multiple idiopathic root resorption. Since the patient did not wish to undergo treatment, it was decided to follow up until the teeth were fractured. One year later, the oral examination showed unchanged from the first examination (**Figure 2**). A panoramic radiograph showed that the cervical root resorption

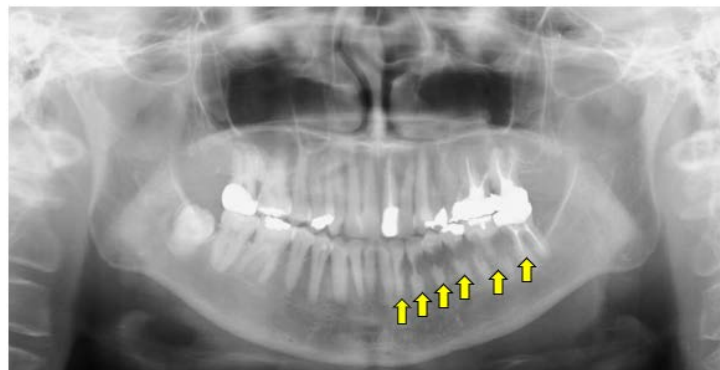


Figure 1. Panoramic radiograph at the initial visit.

Table 1. Blood test results.

Blood test results	
ALP (38 - 113 U/L)	110 U/L
Ca (87 - 10.1 mg/dl)	9.2 mg/dl
IP (2.6 - 4.5 mg/dl)	3.3 mg/dl
urine creatinine (<30 mg/dl)	24 mg/dl
urine calcium (2.0 - 40 mg/dl)	7.1 mg/dl
1α , 25-dihydroxy vitamin D3 (20 ng/ml)	15 ng/ml
tartrate-resistant acid phosphatase (120 - 420 mU/dl)	597 mU/dl

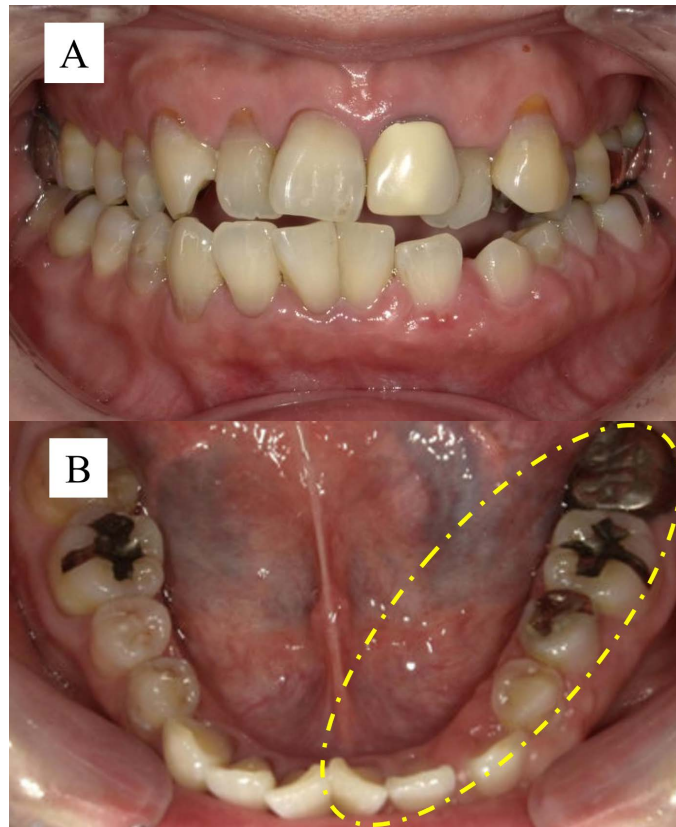


Figure 2. Intraoral photographs one year after initial visit. (A) Frontal view; (B) lower view.

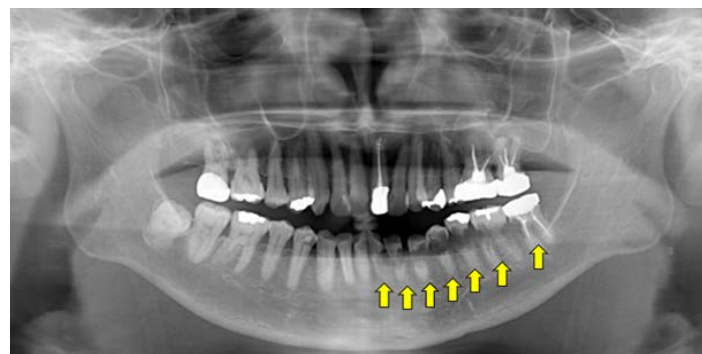


Figure 3. Panoramic radiograph one year after initial visit.

of the left lateral incisor, canine, first and second premolars, and first and second molars of the mandible had progressed, and the extent of cervical resorption had expanded to the left central incisor of the mandible (**Figure 3**). Since the patient did not wish to undergo treatment, it was decided to follow up until the teeth were fractured.

3. Discussion

Root resorption is classified as internal or external [10]. External resorption is classified into five categories: inflammation, replacement, cervical, surface, and

transient apical breakdown [10]. External cervical resorption (ECR) progresses in the cervical region of teeth. Although the etiology of ECR remains unclear, several factors have been suggested [10] including trauma [8] [11] [12], orthodontic treatment [8] [12], periodontal treatment [8] [11], intracoronal bleaching [8] [13], playing wind instruments [14], and idiopathic etiology. In this case, cervical root resorption was observed and classified as ECR. Additionally, idiopathic root resorption was diagnosed because there was no history of trauma, orthodontic treatment, or periodontal treatment. MIRR has been reported in 45 cases between 1970 and 2022 [15]-[49] (Table 2). The male-to-female ratio was 1:2.

Table 2. Clinical features of MIRR cases.

Number	Author	Sex	Age	General condition	Reason for visit	Starting tooth position	New disease tooth position
1	Kerr <i>et al.</i> (1970)	Female	68	Osteoarthritis. Hypophosphatemia. Hypocalcemia. Low alkaline phosphatase level, returning to normal after 9 years	Routine oral examination	16 - 14, 12, 21 - 26, 42, 43	13, 11, 36 - 41, 44, 46, 47
2	Kerr <i>et al.</i> (1970)	Female	30	Hormone therapy for menstrual disorders	Root resorption	16, 14, 13 - 11, 23 - 27, 37, 33 - 43, 45	/
3	George and Miller (1986)	Female	40	No obvious abnormality	Routine oral examination	11, 12, 13, 32, 33, 34, 35, 36	No
4	George and Miller (1986)	Female	20	Regular review within 2 years without exception follow orthodontic treatment; no new lesions for 4 years after the initial visit and treatment; new root resorption detected after pregnancy	Looseness and pain of teeth	23, 25, 26, 27	No
5	Lydiatt <i>et al.</i> (1989)	Female	39	No obvious abnormality, underwent two gynecological operations	Routine oral examination	26, 27	The entire maxillary dentition
6	Moody <i>et al.</i> (1990)	Male	27	No obvious abnormality	Routine oral examination	17, 16, 25, 26, 27, 31, 33 - 37, 41, 43 - 47	No
7	Moody <i>et al.</i> (1990)	Male	20	No obvious abnormality	Abnormal dental imaging	15, 16, 44, 45, 46	13, 14, 17, 18
8	Moody <i>et al.</i> (1990)	Female	44	Gastric regurgitation	Abnormal dental imaging	25 - 27, 34, 35, 44 - 47	/
9	Liang <i>et al.</i> (2003)	Female	19	No obvious abnormality, no significant progression of root resorption within 2 years after initial visit, new root resorption occurred after 2 years, during which the patient became pregnant	Looseness and pain of teeth	41, 42, 43	15 - 17, 24 - 27, 31 - 33, 44 - 46
10	Liang <i>et al.</i> (2003)	Male	68	No obvious abnormality	Bite discomfort	43 - 45	42, 46, 47
11	Liang <i>et al.</i> (2003)	Male	50	Underwent cholecystectomy 5 years previously	Supplement shedding	34, 35	16, 17, 21 - 25, 42 - 44, 46, 47

Continued

12	Iwamatsu-Kobayashi <i>et al.</i> (2005)	Female	49	Hyper-alkaline-phosphatemia and osteoporosis	Difficulty chewing	11 - 13, 15, 17, 21 - 25, 31 - 35, 41 - 45, 47	No
13	Coyle <i>et al.</i> (2006)	Female	33	The patient had a repair of an incomplete cleft palate with an autogenous bone graft as an infant, and again at 17 years	Routine oral examination	21 22, 23	17 - 14, 24, 25
14	Neely and Gordon (2007)	Male	63	Vitiligo on the skin, after colon cancer surgery, mild heart attack	Root resorption	13, 48	17, 16, 13, 12, 23, 24, 25, 26, 27, 37, 36, 34, 33, 45, 44,
15	Mattar <i>et al.</i> (2010)	Female	23	No obvious abnormality, deep overbite	Crown fracture	46, 45, 32, 31	No
16	von Arx <i>et al.</i> (2009)	Female	50	No obvious abnormality, history of cat exposure	Abnormal dental imaging	12, 11, 21, 22, 23, 24	17, 16, 15, 14, 13, 25, 26, 27
17	von Arx <i>et al.</i> (2009)	Female	58	No obvious abnormality, history of cat exposure	Root resorption	35 - 44	No
18	von Arx <i>et al.</i> (2009)	Male	68	No obvious abnormality, history of cat feces exposure	Root resorption	14, 13, 12, 11, 21, 22, 42, 43, 44, 45, 46	/
19	von Arx <i>et al.</i> (2009)	Male	66	Blind, contact with guide dogs, maybe indirectly exposed to cats	Root resorption	13 - 26, 36 - 44, 47	/
20	Yu <i>et al.</i> (2011)	Male	33	No obvious abnormality	Implanted teeth	15 - 25, 37 - 47	Full mouth teeth
21	Arora <i>et al.</i> (2012)	Female	36	No obvious abnormality	Tooth pain	23, 24, 25, 26	/
22	Roy <i>et al.</i> (2012)	Male	32	No obvious abnormality	Repair missing teeth	13, 23, 24, 25	/
23	Kjær <i>et al.</i> (2012)	Female	28	Pertussis	Root resorption	25, 26, 31, 32	21 - 24, 27, 33
24	Haeberle (2013)	Female	19	No obvious abnormality	Abnormal dental imaging	/	Full mouth teeth
25	Ge and Wang (2013)	Female	27	Discovery of lesions during pregnancy	Tooth pain	22, 23, 26	/
26	Chowdhury and Bashar (2014)	Male	37	Total urine phosphate level is low	Difficulty chewing, tooth pain	31, 41, 42, 43, 48	11 - 18, 21, 23, 27
27	Lu and Li (2014)	Female	30	Healthy	Loose lower front teeth with swollen gums	32 - 42, 35, 37, 45 - 47	/
28	Jiang <i>et al.</i> (2014)	Female	26	No obvious abnormality	Bite discomfort	31 - 46	No
29	Kesary <i>et al.</i> (2014)	Male	17	No obvious abnormality	Swollen gums, loose teeth	17, 16, 14 - 23, 31 - 33, 41 - 47	/
30	Wu <i>et al.</i> (2016)	Female	27	No obvious abnormality, history of cat exposure	Chewing pain, loose teeth	32 - 35	12 - 18, 21 - 26, 31, 36, 37, 48, 41 - 46
31	Neely <i>et al.</i> (2016)	Male	43	Healthy	Root resorption	16	26
32	Neely <i>et al.</i> (2016)	Female	60	Hormone replacement therapy for hypothyroidism as a child	The neck of tooth absorption	23	No

Continued

33	Kumar <i>et al.</i> (2018)	Male	18	History of hepatitis B virus infection	Root absorption	36, 37, 42 - 47	12 - 15, 24 - 26, 33 - 38, 48
34	Dobroś <i>et al.</i> (2018)	Male	41	Celiac disease	Loose teeth	16, 17, 13 - 21	No
35	Shashidara <i>et al.</i> (2018)	Male	32	/	Missing teeth requiring restoration	15, 14, 23 - 25	No
36	Li <i>et al.</i> (2019)	Female	31	No obvious abnormality	Routine oral examination	21, 36	37, 38
37	Llavayol <i>et al.</i> (2019)	Female	26	History of chemotherapy for ovarian cancer	Root absorption	23 - 26, 33 - 35, 43 - 47	36
38	Sharma <i>et al.</i> (2019)	Female	23	No obvious abnormality	Pain and loosening of tooth	23 - 25, 33 - 45	16 - 23, 25 - 28, 34 - 36, 46, 47
39	Deeb <i>et al.</i> (2019)	Female	69	Various systemic diseases, discontinue denosumab for osteoporosis	Pain and sensitivity of the tooth	27, 37	12 - 22, 36, 32 - 44
40	Chen <i>et al.</i> (2020)	Female	29	Discovery of lesions during pregnancy	Loose teeth	17 - 27, 41 - 37, 44 - 47	42, 43, 18, 28, 38, 48
41	Macaraeg <i>et al.</i> (2020)	Female	10	Congenitally missing ossicles, familial expansile osteolysis	Imaging shows root resorption	21, 22, 23, 31, 41	/
42	Samara <i>et al.</i> (2021)	Female	16	History of sepsis	Generalized dull and continuous pain; mild mobility in lower anterior teeth.	14 - 16, 32-36, 41 - 47	37
43	Yilmaz <i>et al.</i> (2022)	Female	36	No systemic health issues or medication use	Unable to chew due to loss of maxillary teeth	11 - 24, 35 - 45	No
44	Mikušková <i>et al.</i> (2022)	Female	74	Arterial hypertension, glaucoma, and postmenopausal osteoporosis with multiple osteoporotic thoracic vertebral fractures	Occasional pain, thermal sensitivity, and slightly increased mobility of the left mandibular second premolar	16, 15, 13 - 26, 37 - 45	/
45	Beaumont <i>et al.</i> (2022)	Female	55	De novo bone metastatic breast cancer	Pain localized to upper right molars	18 - 24, 26 - 28, 38-42, 44 - 48	/

Wang *et al.* [50] reported that the occurrence and progression of MIRR may be related to hormonal changes in females because patients had a history of hormonal changes, including pregnancy, hormone therapy, and gynecological treatment. Considering the patient's age, it is thought that there was a female hormone decrease, and there is a possibility that root resorption and a decrease in hormones are related. The mandibular premolars are most frequently affected during the early stages of MIRR [15]. In this case, the mandibular premolars were within the range of the MIRR. Patients typically experience tooth pain and mobility. The other patients were incidentally diagnosed with MIRR during a radiographic examination. In the present case, occlusal pain was observed, but no other subjective symptoms were reported. The patient was incidentally diag-

nosed with MIRR during a radiographic examination. Resorption often originates from the mesial or distal Cement Enamel Junction, and its image resembles apple cores [17]. Similar characteristics were observed in the present case. Treatment options generally include tooth extraction and replacement with a partial denture, surgical exposure, lesion curettage, and restoration [27] [31]. In this case, because the patient did not wish to undergo treatment, follow-up performs until the teeth will be fractured.

4. Conclusion

In this case, we have performed all possible tests, but have not been able to determine the cause of MIRR. Further case accumulation is needed for MIRR.

Conflicts of Interest

The authors declare no conflicts of interest associated with this manuscript.

Ethics Approval Statement

We conducted this study in accordance with the current revision of the 1975 Declaration of Helsinki.

References

- [1] American Association of Endodontists (2020) Glossary of Endodontic Terms Tenth Edition. Chicago. <http://www.aae.org/glossary/>
- [2] Tronstad, L. (1988) Root Resorption—Etiology, Terminology and Clinical Manifestations. *Dental Traumatology*, **4**, 241-252. <https://doi.org/10.1111/j.1600-9657.1988.tb00642.x>
- [3] Al-Badri, S., Kinirons, M., Cole, B. and Welbury, R. (2002) Factors Affecting Resorption in Traumatically Intruded Permanent Incisors in Children. *Dental Traumatology*, **18**, 73-76. <https://doi.org/10.1034/j.1600-9657.2002.180205.x>
- [4] Heboyan, A.G., Avetisyan, A.A. and Margaryan, M.M. (2018) Clinical Case of a Rarely Diagnosed Tooth Root Internal Resorption. *The New Armenian Medical Journal*, **12**, 87-92.
- [5] Consolaro, A. (2019) Extreme Root Resorption in Orthodontic Practice: Teeth Do Not Have to Be Replaced with Implants. *Dental Press Journal of Orthodontics*, **24**, 20-28. <https://doi.org/10.1590/2177-6709.24.5.020-028.oin>
- [6] Patel, S. and Ford, T.P. (2007) Is the Resorption External or Internal? *Dental Update*, **34**, 218-229. <https://doi.org/10.12968/denu.2007.34.4.218>
- [7] Mavridou, A.M., Bergmans, L., Barendregt, D. and Lambrechts, P. (2017) Descriptive Analysis of Factors Associated with External Cervical Resorption. *Journal of Endodontics*, **43**, 1602-1610. <https://doi.org/10.1016/j.joen.2017.05.026>
- [8] Heithersay, G.S. (1999) Invasive Cervical Resorption: An Analysis of Potential Predisposing Factors. *Quintessence International*, **30**, 83-95.
- [9] Mueller, E. and Rony, H.R. (1930) Laboratory Studies of a Usual Case of Resorption. *The Journal of the American Dental Association*, **17**, 326-334.
- [10] Patel, S. and Saberi, N. (2018) The Ins and Outs of Root Resorption. *British Dental Journal*, **224**, 691-699. <https://doi.org/10.1038/sj.bdj.2018.352>

- [11] Trope, M. (2002) Root Resorption Due to Dental Trauma. *Endodontic Topics*, **1**, 79-100. <https://doi.org/10.1034/j.1601-1546.2002.10106.x>
- [12] Mavridou, A.M., Bergmans, L., Barendregt, D. and Lambrechts, P. (2017) Descriptive Analysis of Factors Associated with External Cervical Resorption. *Journal of Endodontics*, **43**, 1602-1610. <https://doi.org/10.1016/j.joen.2017.05.026>
- [13] Harrington, G.W. and Natkin, E. (1979) External Resorption Associated with the Bleaching of Pulpless Teeth. *Journal of Endodontics*, **5**, 344-338. [https://doi.org/10.1016/S0099-2399\(79\)80091-6](https://doi.org/10.1016/S0099-2399(79)80091-6)
- [14] Gunst, V., Huybrechts, B., De Almeida, N.A, Bergmans, L., Van Meerbeek, B. and Lambrechts, P. (2011) Playing Wind Instruments as a Potential Aetiologic Cofactor in External Cervical Resorption: Two Case Reports. *International Endodontic Journal*, **44**, 268-282. <https://doi.org/10.1111/j.1365-2591.2010.01822.x>
- [15] Kerr, D.A., Courtney, R.M. and Burkes, E.J. (1970) Multiple Idiopathic Root Resorption. *Oral Surgery, Oral Medicine, Oral Pathology*, **29**, 552-565. [https://doi.org/10.1016/0030-4220\(70\)90467-6](https://doi.org/10.1016/0030-4220(70)90467-6)
- [16] George, D.I. and Miller, R.L. (1986) Idiopathic Resorption of Teeth A Report of Three Cases. *American Journal of Orthodontics*, **89**, 13-20. [https://doi.org/10.1016/0002-9416\(86\)90108-9](https://doi.org/10.1016/0002-9416(86)90108-9)
- [17] Lydiatt, D.D., Hollins, R.R. and Peterson, G. (1989) Multiple Idiopathic Root Resorption: Diagnostic Considerations. *Oral Surgery, Oral Medicine, Oral Pathology*, **67**, 208-210. [https://doi.org/10.1016/0030-4220\(89\)90333-2](https://doi.org/10.1016/0030-4220(89)90333-2)
- [18] Moody, A.B., Speculand, B., Smith, A.J. and Basu, M.K. (1990) Multiple Idiopathic External Resorptions of Teeth. *International Journal of Oral & Maxillofacial Surgery*, **19**, 200-202. [https://doi.org/10.1016/S0901-5027\(05\)80389-3](https://doi.org/10.1016/S0901-5027(05)80389-3)
- [19] Liang, H., Burkes, E.J. and Frederiksen, N.L. (2003) Multiple Idiopathic Cervical Root Resorption: Systematic Review and Report of Four Cases. *Dentomaxillofacial Radiology*, **32**, 150-155. <https://doi.org/10.1259/dmfr/12925020>
- [20] Iwamatsu-Kobayashi, Y., Satoh-Kuriwada, S., Yamamoto, T., Hirata, M., Toyoda, J., Endo, H., Kindaichi, K. and Komatsu, M. (2005) A Case of Multiple Idiopathic External Root Resorption: A 6-Year Follow-Up Study. *Oral Surgery, Oral Medicine, Oral Pathology, Oral Radiology*, **100**, 772-779. <https://doi.org/10.1016/j.tripleo.2004.11.047>
- [21] Coyle, M., Toner, M. and Barry, H. (2006) Multiple Teeth Showing Invasive Cervical Resorption—An Entity with Little Known Histologic Features. *Journal of Oral Pathology & Medicine*, **35**, 55-57. <https://doi.org/10.1111/j.1600-0714.2005.00371.x>
- [22] Neely, A.L. and Gordon, S.C. (2007) A Familial Pattern of Multiple Idiopathic Cervical Root Resorption in a Father and Son: A 22-Year Follow-Up. *Journal of Periodontology*, **78**, 367-371. <https://doi.org/10.1902/jop.2007.060155>
- [23] Mattar, R., De Lima, S.A.P., Rodor, R.C. and Rodrigues, D.B.R. (2008) External Multiple Invasive Cervical Resorption with Subsequent Arrest of the Resorption. *Dental Traumatology*, **24**, 556-559. <https://doi.org/10.1111/j.1600-9657.2007.00553.x>
- [24] von Arx, T., Schawalder, P., Ackermann, M. and Bosshardt, D.D. (2009) Human and Feline Invasive Cervical Resorptions: The Missing Link? —Presentation of Four Cases. *Journal of Endodontics*, **35**, 904-913. <https://doi.org/10.1016/j.joen.2009.03.044>
- [25] Yu, V.S.H., Messer, H.H. and Tan, K.B. (2011) Multiple Idiopathic Cervical Resorption: Case Report and Discussion of Management Options. *International Endodontic Journal*, **44**, 77-85. <https://doi.org/10.1111/j.1365-2591.2010.01820.x>

- [26] Arora, A., Acharya, S.R., Muliya, V.S. and Sharma, P. (2012) Multiple Idiopathic Cervical Resorption: A Diagnostic Dilemma. *Quintessence International*, **3**, 187-190
- [27] Roy, D.K., Sharma, S., Suwal, P., Singh, V.P. and Ayer, A. (2012) Multiple Idiopathic Cervical Resorption: A Case Report. *Bangladesh Journal of Medical Science*, **11**, 151-153. <https://doi.org/10.3329/bjms.v11i2.8680>
- [28] Kjær, I., Strøm, C. and Worsaae, N. (2012) Regional Aggressive Root Resorption Caused by Neuronal Virus Infection. *Case Reports in Dentistry*, **2012**, Article ID: 693240. <https://doi.org/10.1155/2012/693240>
- [29] Haeberle, C.B. (2013) Prosthodontic Rehabilitation of a Patient Diagnosed with Multiple Idiopathic Root Resorption. *The Journal of Prosthetic Dentistry*, **110**, 442-446. <https://doi.org/10.1016/j.prosdent.2013.08.002>
- [30] Ge, Y.N. and Wang, X.M. (2013) A Case of Multiple Root and Neck Resorption. *Journal of Oral Science*, **29**, 98-99.
- [31] Chowdhury, S.S. and Bashar, A.K.M. (2014) Progressive Idiopathic External Root Resorption in Multiple Teeth: A 6-Year Follow-Up Study. *Update Dental College Journal*, **4**, 14-19. <https://doi.org/10.3329/updcj.v4i2.24042>
- [32] Lu, H. and Li, S.J. (2014) A Case of Multiple External Tooth Neck Absorption. *Chinese Journal of Conservative Dentistry*, **24**, 567.
- [33] Jiang, Y.H., Lin, Y., Ge, J., Zheng, J.W., Zhang, L. and Zhang, C.Y. (2014) Multiple Idiopathic Cervical Root Resorptions: Report of One Case with 8 Teeth Involved Successively. *International Journal of Clinical and Experimental Medicine*, **7**, 1155-1159.
- [34] Kesary, S., Mengji, A.K., Yaga, U.S. and Panta, P. (2014) An Unusual Case of Idiopathic Multiple Invasive Cervical Resorption. *Journal of Indian Academy of Oral Medicine & Radiology*, **26**, 229-232. <https://doi.org/10.4103/0972-1363.143713>
- [35] Wu, J., Lin, L.Y., Yang, J., Chen, X.F., Ge, J.Y., Wu, J.R. and Sun, W.B. (2016) Multiple Idiopathic Cervical Root Resorption: A Case Report. *International Endodontic Journal*, **49**, 189-202. <https://doi.org/10.1111/iej.12440>
- [36] Neely, A.L., Thumbigere-Math, V., Somerman, M.J. and Foster, B.L. (2016) A Familial Pattern of Multiple Idiopathic Cervical Root Resorption with a 30-Year Follow-Up. *Journal of Periodontology*, **87**, 426-433. <https://doi.org/10.1902/jop.2015.150536>
- [37] Kumar, V., Chawla, A. and Kaur, A. (2018) Multiple Idiopathic Cervical Root Resorptions in Patients with Hepatitis B Virus Infection. *Journal of Endodontics*, **44**, 1575-1577. <https://doi.org/10.1016/j.joen.2018.06.017>
- [38] Dobroś, K., Myciński, P., Borowy, P. and Zarzecka, J. (2018) Multiple Invasive Cervical Resorption and Celiac Disease: A Case Report. *Quintessence International*, **49**, 407-412.
- [39] Shashidara, R., Sudheendra, U.S., Aparna, H.G. and Kavita, A.P. (2018) Multiple Idiopathic Cervical Resorption a Case Report. *Journal of Multidisciplinary Dental Research*, **4**, 34-38.
- [40] Li, S.S., Lin, J.J., Shi, N.L. and Zheng, Y. (2019) One Case of Multiple Idiopathic Root and Neck Absorption Preservation Treatment. *Beijing Journal of Stomatology*, **27**, 342-344.
- [41] Llavayol, M., Pons, M., Ballester, M.L. and Berástegui, E. (2019) Multiple Cervical Root Resorption in a Young Adult Female Previously Treated with Chemotherapy: A Case Report. *Journal of Endodontics*, **45**, 349-353. <https://doi.org/10.1016/j.joen.2018.12.012>

- [42] Sharma, S., Kumar, P., Jain, V. and Logani, A. (2019) Multiple Idiopathic Cervical Root Resorption: Diagnosis, Clinical/Radiographical/Histological Presentation and Rehabilitation—A 7-Year Follow-Up Case Report. *Journal of Conservative Dentistry*, **22**, 313-317. https://doi.org/10.4103/JCD.JCD_445_18
- [43] Deeb, J.G., Azarnoush, K., Laskin, D.M. and Deeb, G.R. (2019) Discontinuation of Denosumab as a Potential Cause of Generalized External Cervical Root Resorption: A Case Report. *Journal of Endodontics*, **45**, 640-644. <https://doi.org/10.1016/j.joen.2019.02.013>
- [44] Chen, X., Yu, X., Yan, K., Liu, S., Sun, Z. and Li, S. (2020) Multiple Idiopathic Cervical Root Resorption Involving All Permanent Teeth. *Australian Endodontic Journal*, **46**, 263-271. <https://doi.org/10.1111/aej.12398>
- [45] Macaraeg, K., Lee, S.M., Kalra, L., Velasco, M. and Hajishengallis, E. (2020) Multiple External Root Resorption in a Pediatric Patient with Familial Expansile Osteolysis. *Pediatric Dentistry*, **42**, 62-65.
- [46] Samara, E., Kelly, E., Walker, R. and Borumandi, F. (2021) Multiple Idiopathic Cervical Root Resorption: Case Report of an Unusual Presentation. *Special Care in Dentistry*, **41**, 98-102. <https://doi.org/10.1111/scd.12539>
- [47] Yilmaz, B., Diker, E., Ovchinnik, V. and Abou-Ayash, S. (2022) Management of a Partially Edentulous Patient with Idiopathic Root Resorption by Using Digital and Conventional Implant Planning Technologies. *The Journal of Prosthetic Dentistry*, **127**, 15-21. <https://doi.org/10.1016/j.prosdent.2021.01.011>
- [48] Mikušková, K., Vaňuga, P., Adamicová, K., Stelová, D., Janíčková, M., Malachovský, I. and Siebert, T. (2022) Multiple Idiopathic External Cervical Root Resorption in Patient Treated Continuously with Denosumab: A Case Report. *BMC Oral Health*, **22**, Article No. 129. <https://doi.org/10.1186/s12903-022-02165-7>
- [49] Beaumont, S., Angel, C.M. and Dawson, S.J. (2022) Denosumab and Invasive Cervical Root Resorption: A Case Report. *Australian Dental Journal*, **67**, 183-189. <https://doi.org/10.1111/adj.12897>
- [50] Wang, N., Zhang, M., Zhu, J., Zhu, Y. and Wu, J. (2022) Multiple Idiopathic Cervical Root Resorption: A Systematic Review. *Oral Diseases*. <https://doi.org/10.1111/odi.14406>