

Twisting of the Spermatic Cord in an Elderly Subject at the Yaounde Central Hospital: About a Case

Jean Cedrick Fouda^{1,2}, Junior Barthelemy Mekeme Mekeme^{1,2}, Philip Fernandez Owon'Abessolo^{1,3}, Marcella Derboise Christelle Biyouma², Ranibel Allo², Axel Stephane Nwaha Makon², Frantz Guy Ngalle Epoupa², Landry Oriole Mbouche², Cedric Mayopa Dongmo², Achille Aurèle Mbassi^{1,3}, Medjo Hell⁴, Pierre Joseph Fouda^{1,2}, Arthur Essomba²

¹Yaounde Central Hospital, Yaounde, Cameroon

²University of Yaounde I, Yaounde, Cameroon

³University of Douala, Douala, Cameroon

⁴Private Hospital, Cameroon

Email: cedrickfouda@gmail.com

How to cite this paper: Fouda, J.C., Mekeme, J.B.M., Owon'Abessolo, P.F., Biyouma, M.D.C., Allo, R., Makon, A.S.N., Epoupa, F.G.N., Mbouche, L.O., Dongmo, C.M., Mbassi, A.A., Hell, M., Fouda, P.J. and Essomba, A. (2022) Twisting of the Spermatic Cord in an Elderly Subject at the Yaounde Central Hospital: About a Case. *Open Journal of Urology*, 12, 394-400.

<https://doi.org/10.4236/oju.2022.127038>

Received: April 30, 2022

Accepted: July 15, 2022

Published: July 18, 2022

Copyright © 2022 by author(s) and Scientific Research Publishing Inc. This work is licensed under the Creative Commons Attribution International License (CC BY 4.0).

<http://creativecommons.org/licenses/by/4.0/>



Open Access

Abstract

Introduction: Twisting of the spermatic cord is part of urological emergencies. It can occur at any age with a predilection for children and adolescents. There is no literature on spermatic cord torsion in octogenarians, probably due to its rarity. The majority of recent studies show spermatic cord torsion in patients under 55 years of age. This is why we present a case of spermatic cord torsion in an 80 years old subject. **Case Presentation:** We present a case of torsion of the spermatic cord in an 80-year-old subject. The diagnosis was made on anamnestic and clinical grounds. The patient presented with scrotal pain, unilateral, of sudden onset, violent intensity without urinary signs with an ascended testicle. The urine dipstick was unremarkable. Management was done surgically and as an emergency. The postoperative course was satisfactory. **Conclusion:** Spermatic cord torsion in octogenarians is exceptional and should be suspected in the first instance in the presence of any sudden onset, severe testicular pain without urinary signs with an ascended testicle and a negative urine dipstick.

Keywords

Twisting of the Spermatic Cord, 80-Year-Old Subject, Diagnostic, Emergency

1. Introduction

The twisting of the spermatic cord is a urological emergency. It is due to a rota-

tion of the testicle on its vascular-nervous axis resulting in a partial or permanent cessation of blood flow. It quickly brings into play the functional and vital prognosis of the gland. New-borns, children and adolescents are the most exposed [1] [2]. The torsion is most often unilateral [3]. There is no literature on spermatic cord torsion in octogenarians, probably due to its rarity. The majority of recent studies show spermatic cord torsion in patients under 55 years of age [4] [5]. The case we report is that of a twist of the spermatic cord in an octogenarian subject

2. Case Presentation

Mr. AA, 80, a teacher by profession, had been seen for brutal right testicular pain while he was watching television. The history of the disease indicates the occurrence of pain a few minutes before the consultation, abrupt installation, without irradiation, dagger-like, intense, without lull factor, aggravated by palpation and accompanied by difficulty walking. He had no specific history and the patient had no particular voiding disorders and no history of recent unprotected intercourse. He does a regular annual check-up. He has not had questionable sex in the past six months. The physical examination made it possible to note a good general state, normo-colored mucous membranes, a flexible abdomen without palpable mass; the cardiovascular and pleuro-pulmonary examination was without pathological particularity. The hernia openings were free. The penis was normal in appearance. Examination of the testicles revealed a right testicle in the purses, there was an elevation and horizontalization of the testicle and pain was present when lifting the testicle. The cremasteric reflex was abolished. The testicle was sensitive. The scrotum was wrinkled and non-inflammatory. The left testicle was normal.

In total, we concluded that the spermatic cord was twisted in an 80-year-old subject. We had done a Doppler ultrasound which confirmed the existence of a twisted spermatic cord and a viable testicle (**Figure 1**). We performed a urine dipstick which was unremarkable. An operational assessment had been made and was within normal limits.

Surgically, we made an incision on the medial raphe and dissected the different parietal planes, thereby exposing the right testicle. We objectified a turn of the turn, the testicle was macroscopically normal but bluish in colour (**Figure 2**). We twisted and fixed the testicle to the wall with a 4/0 prolene at 3 a.m. and 9 a.m. the contralateral testicle was fixed in the same way. We then closed the scrotal wall.

The surgery was well tolerated by the patient. The post-operative course was simple and unremarkable. The patient was discharged three days later with a favourable evolution. The patient was seen again at two weeks, one and three months post-operatively. Examination of the testicle revealed a normal looking testicle.

3. Discussion

A brutal testicular pain occurring in an elderly subject can evoke a certain number

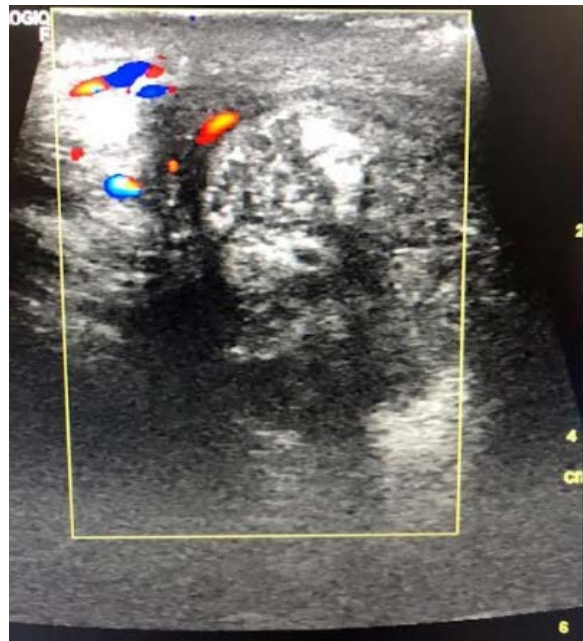


Figure 1. Existence of a twisted spermatic cord and a viable testicle.

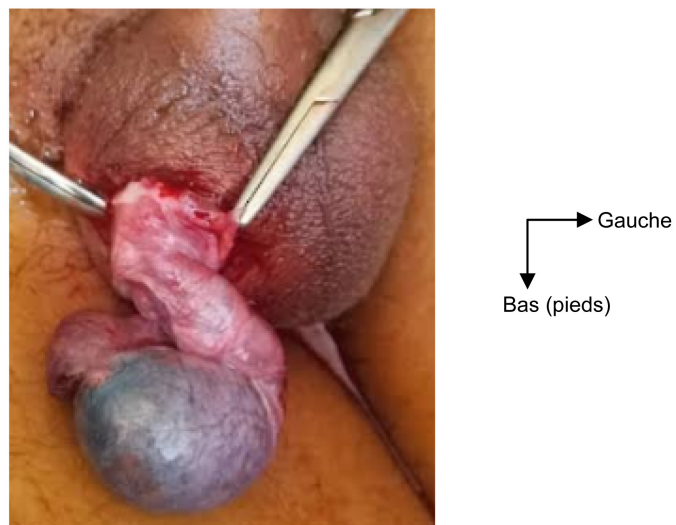


Figure 2. Torsion of the right testicle with testicle and epididymis in full pain but not necrotic (bluish appearance of the testicle).

of pathologies among which a strangulated inguino-scrotal hernia, a trauma, an acute orchiepidymitis, a testicular cancer revealing itself in an acute mode. Spermatic cord torsion remains an often overlooked diagnosis of acute scrotal pain in adults [6].

Testicular torsion is a surgical urological emergency. Hypoxia of the gland prolonged beyond six hours definitively compromises its function. Twisting of the spermatic cord can occur at any age but with predominance for those under 25 [1] [2] [7]. There is no literature on spermatic cord torsion in octogenarians, probably due to its rarity. The majority of studies show spermatic cord torsion in

patients under 55 years of age [4] [5].

Studies show that the oldest patients were 44 [4], 55 [5] and 46 [8] years old respectively. Skoglund, in his study, had a patient of 78 years but the mean age was 14.9 years [9]. Our patient was 80 years old. Furthermore, twisting of spermatic cord, classically, presents two peaks of frequency in children: the neonatal period and adolescence [4]. This shows the rarity of cases of spermatic cord torsion in the elderly (**Table 1**).

The average consultation time was 102 hours, 24.6 hours and 27.5 hours respectively in Senegal [4], Burkina Faso [5] and France [8]. Our patient consulted less than 6 hours after the onset of pain. This can be explained by the fact that the elderly have less tolerance for pain than young adults. Another explanation for the rapid consultation time is that the patient's children are more sensitive to the onset of a painful condition, as the life expectancy of this patient is considerably reduced.

The patient presented with pain in the bursa, ascending and horizontalizing of the testicle and no pain in the elevation of the testicle. Pain is the most common symptom [4] [5] [10]. Horizontalization of the testis and lack of pain on elevation of the testis are the dominant clinical features of spermatic cord torsion [10]. The absence of testicular swelling in the patient may be explained by the delay in consultation. The abolition of the cremasteric reflex remains an important clinical feature in the diagnosis of spermatic cord torsion as in our patient.

Della-Negra *et al.* [6] noted in their study that it is necessary to systematically evoke a torsion of the spermatic cord in front of an adult presenting with scrotal pain which combines:

- Absence of urinary signs;
- Negative urine dipstick;
- Severe pain;
- Ascending testis;
- Superacute stage.

Our patient had all these characteristics.

Some studies advise against ultrasound for diagnostic confirmation as scrotal ultrasound is falsely reassuring in 10% [8] and Doppler ultrasound only confirms the diagnosis in 5 out of 8 cases [5]. However, in our patient, his age and the incidence of spermatic cord torsion led us to request an ultrasound scan. Furthermore, Zini and al. mentioned the problem of ultrasound in patients who had a rather long delay in consultation [8].

Table 1. Distribution of ages of occurrence of spermatic cord torsion by study.

Articles	Age group
Sarr A, 2010 (Senegal) [4]	1 - 44 years
FA Kabore, 2011 (Burkina Faso) [5]	16 - 55 years
Laurent ZINI, 2003 [8]	1 - 46 years
Skoglund, 1970 [9]	Neo-natal period - 78 years

Our patient had testicular pain on the right side. The majority of patients have right-sided testicular pain [4].

The urine dipstick did not find anything unusual. Della-Negra *et al.* [6] recommend the systematic use of urine strips in adults to rule out acute orchid-epididymitis in cases of acute painful bursa, especially as torsion of the spermatic cord is an often overlooked diagnosis in the face of acute scrotal pain in adults [6].

We performed a bilateral orchidopexy. Delay in consultation seems to be the main predictive factor for orchiectomy for testicular necrosis [5] and the only predictive factor for testicular necrosis is the delay in management [6]. The sixth hour seems to be the upper limit after which testicular necrosis occurs [6], so we can say that the early management of this patient was an important factor in safeguarding testicular vitality. Fixation of the contralateral testis with a torsion of the spermatic cord is currently recommended by all authors [8] [10] [11]. Our preference is bilateral orchidopexy when the testicle is alive, as do some authors [6] [8]. This attitude is justified by the real risk of subsequent torsion of the contralateral testicle which is 3% to 18% depending on the authors [11].

Spermatic cord torsion is the most common subject of medico-legal dispute in urological practice [8]. The most common torts are diagnostic uncertainty, diagnostic and therapeutic delays and diagnostic errors that can lead to organ loss [8]. Elderly patients and those with atypical symptoms are the most likely to complain [8]. Therefore, clinical management of spermatic cord torsion is of major interest, especially for patients over 50 years old. The mastery of the clinic of the torsion of the spermatic cord remains of major interest especially for a subject over 50 years.

4. Conclusions

Spermatic cord torsion in octogenarians is rare and should be suspected in the first instance in the presence of any sudden onset, severe testicular pain without urinary signs with an ascended testicle and a negative urine dipstick. The diagnosis is primarily clinical. And, there may be a medico-legal situation that requires clinical and surgical mastery of the torsion of the spermatic cord.

Learning Points/Take Home Messages

It is always necessary to think of a twisting of the spermatic cord (urological surgical emergency) in front of an acute testicular pain whatever the age of the patient, especially if the clinic is evocative.

Acknowledgements

We would like to thank the administration and staff of the Urology Department of the Yaounde Central Hospital.

Ethics Approval and Consent to Participate

We got a research permit from the Ethics Committee at the Central Hospital of

Yaounde.

Consent for Publication

We obtained consent from the patient and we got a research permit from the Ethics Committee at the Central Hospital of Yaounde.

Authors' Contributions

- FJC operated on the patient and wrote this case report;
- MMJB was the surgery supervisor;
- OA was the operating assistant;
- BMDC and RA have supervised the translation process of this case report;
- MLO, MC and MAA were on the reading committee;
- MH did the Doppler ultrasound of the testicles;
- FPJ and SMA supervised the writing of this case report.

All authors have read and approved the manuscript.

Consent to Publish

The patient gave consent.

Conflicts of Interest

We do not declare any conflict of interest within the framework of this study.

References

- [1] Rambeaud, J.J. and Descotes, J.L. (1991) Torsion du testicule et de ses annexes. *EncyclMéd Chir (Scientific and Medical Editions Elsevier SAS, Paris), Néphrologie-Urologie*, 18-622-A-10, 1-6
- [2] Hodonou, R., Soumanou-Kaffo, R. and Akpo, C. (1999) Torsion du cordon spermatique cordon spermatique: Facteurs étiopathogéniques, diagnostiques et thérapeutiques-concernant 33 Cas au CNHU de Cotonou. *Medicine in Black Africa*, **46**, 69-74.
- [3] Roth, C.C., Mingin, G.C. and Ortenberg, J. (2011) Salvage of Bilateral Asynchronous Perinatal Testicular Torsion. *The Journal of Urology*, **185**, 2464-2468. <https://doi.org/10.1016/j.juro.2011.01.013>
- [4] Sarr, A., Fall, B., Mouss, B., *et al.* (2010) Diagnostic and Therapeutic Aspects of Spermatic Cord Torsion at CHU Aristide-Le-Dantec de Dakar. *Basic and Clinical Andrology*, **20**, 203-208. <https://doi.org/10.1007/s12610-010-0083-2>
- [5] Kaboré, F.A., Zango, B., Yameogo, C., *et al.* (2011) Spermatic Cord Torsion in Adults at CHU Yalgado Ouédraogo de Ouagadougou. *Basic and Clinical Andrology*, **21**, 254-259. <https://doi.org/10.1007/s12610-011-0151-2>
- [6] Della-Negra, E., Martin, M., Bernardini, S. and Bittard, H. (2000) Spermatic Cord Torsion in Adults. *Progres en Urologie. Journal de L'Association Francaise D'Urologie et de la Societe Francaise D'Urologie*, **10**, 265-270.
- [7] Houlgatte, A., Fournier, R. and Berlizo, P. (2001) Torsion du cordon spermatique et des annexes testiculaires. *EncyclMéd Chir (Éditions Scientifiques et Médicales Elsevier SAS, Paris), Urgences*, 24-203-A-10, 1-6.
- [8] Zini, L., Mouton, D., Leroy, X., Valtille, P., Villers, A., Lemaitre, L. and Biserte, J.

- (2003) Should Scrotal Ultrasound Be Discouraged in Cases of Suspected Torsion of the Spermatic Cord Torsion? *Progres en Urologie. Journal de L'Association Francaise D'Urologie et de la Societe Francaise D'Urologie*, **13**, 440-444.
- [9] Skoglund, R.W., Mcroberts, J.W. and Ragde, H. (1970) Torsion of the Spermatic Cord: A Review of the Literature and an Analysis of 70 New Cases. *The Journal of Urology*, **104**, 604-607. [https://doi.org/10.1016/S0022-5347\(17\)61792-0](https://doi.org/10.1016/S0022-5347(17)61792-0)
- [10] Bah, O.U., Roupret, M., Guirassy, S., Diallo, A.B., Diallo, M.B. and Richard, F. (2010) Clinical and Therapeutic Aspects of Spermatic Cord Torsion: Study of 27 Cases. *Progrès en Urologie*, **20**, 527-531. <https://doi.org/10.1016/j.purol.2009.12.011>
- [11] Mongiat-Artus, P. (2004) Torsion du cordon spermatique et des annexes testiculaires. *Annales D'Urologie*, **38**, 25-34. <https://doi.org/10.1016/j.anuro.2003.11.001>