

BNL 18401

Conf-740203--1

RECEIVED BY TIG JAN 3 1974

COMPARATIVE EVALUATION OF ^{123}I AND $^{99\text{m}}\text{Tc}$
FOR THYROID STUDIES

H.L. Atkins, A.N. Ansari, P.R. Bradley-Moore,
R. Lambrecht and A. Wolf

Medical Department and Chemistry Department
Brookhaven National Laboratory
Upton, New York 11973

For presentation at the International Symposium on Radiopharmaceuticals,
Atlanta, Georgia, February 12-15, 1974

NOTICE

This report was prepared as an account of work sponsored by the United States Government. Neither the United States nor the United States Atomic Energy Commission, nor any of their employees, nor any of their contractors, subcontractors, or their employees, makes any warranty, express or implied, or assumes any legal liability or responsibility for the accuracy, completeness or usefulness of any information, apparatus, product or process disclosed, or represents that its use would not infringe privately owned rights.

MASTER

DISTRICT

129

COMPARATIVE EVALUATION OF ^{123}I AND $^{99\text{m}}\text{Tc}$
FOR THYROID STUDIES

H.L. Atkins, A.N. Ansari, P.R. Bradley-Moore,
R. Lambrecht and A. Wolf

Technetium-99m as pertechnetate is now widely used for imaging the thyroid. It is used to a somewhat lesser extent for assessment of the functional status of the thyroid. Technetium can be so utilized because of its being "trapped" by the thyroid.

In addition to being trapped, iodine is organically bound within the thyroid. Radioiodine has been used to study both trapping and binding functions of the thyroid. Iodine-131 has been the isotope of iodine most widely used for these applications but is far from ideal for several reasons.

Recently iodine-123 has received wide attention because it combines some of the favorable physical attributes of technetium-99m with the biological characteristics of iodine. Both technetium-99m and iodine-123 possess short physical half-lives, intermediate range gamma photon energies and virtual absence of beta-like emissions. These features allow large amounts of radioactivity to be administered without excessive radiation dose to the patient.

Both technetium-99m and iodine-123 can be utilized efficiently with the gamma camera. The intermediate gamma energy is readily collimated and detected. The slightly higher energy of iodine-123 is advantageous in that separation of photopeak from Compton scatter is more readily accomplished than with technetium-99m. Theoretically this should provide slightly better resolution for ^{123}I over $^{99\text{m}}\text{Tc}$.

Dynamic studies of radionuclide uptake by the thyroid can be performed with both ^{123}I and $^{99\text{m}}\text{Tc}$. A comparison study of this phase of thyroid metabolism has begun and, to date, twenty-six patients have had thirty-minute uptake curves determined with both radionuclides. In addition, comparison images have been obtained at 30 minutes with technetium-99m and at 30 minutes and 24 hours with iodine-123.

One would expect that, at comparable times following intravenous injection, the thyroïdal accumulation of iodine would always be higher than with technetium. This has not always been true. The series is too small at this time to reach any definite conclusions. It does seem that the two radionuclides provide complementary information and should help to provide a better understanding of the initial phase of radionuclide uptake by the thyroid.

INTRODUCTION

The most commonly used radiopharmaceutical for in-vivo investigation of thyroid function and anatomy is sodium iodide, iodine-131. However, the radiation dose for usually administered doses is excessively high, higher than for any other radionuclide examination. Ready availability at low cost with good shelf-life accounts for its widespread use. Thyroid function tests have been standardized to its use.

In an attempt to improve the quality of imaging procedures and to reduce radiation dose some have advocated the use of iodine-125 (1-3). The radiation dose from iodine-125 is still rather high and technical problems are encountered in its use for quantitative studies.

More recently technetium-99m, as pertechnetate has enjoyed increasing popularity as an imaging agent (4-7) in addition to its use for functional evaluation of the thyroid (8-10). Reasons for its popularity are low cost, ready availability, high photon yield and low radiation dose. Some clinicians remain reluctant to accept it as an agent for assessment of thyroid function because it is not a natural metabolite of the gland. A number of other drawbacks to its use have been noted. On occasion there may be a difference between the technetium (trapping) and iodine (binding) image (11-16). These differences occur for a variety of reasons and are a source of confusion. When the thyroid gland is large or substernal in location, a poor image is obtained. Often, with low uptakes the image is not diagnostic due to the low target-nontarget ratio.

The physical properties of iodine-123 are such that it has been considered an ideal radionuclide for thyroid diagnostic use (17-18). Similarities to technetium-99m in decay characteristics plus the biological behavior of iodine indicate that it should be superior to technetium. The only drawback has been lack of availability due to limited production capabilities of most cyclotrons. Hopefully this limitation can be overcome in the near future.

PHYSICAL ASPECTS

The decay characteristics of technetium-99m and iodine-123 are rather similar. Both possess principal gamma photons of intermediate energy and minimal amounts of beta-type emission. Iodine-123 also possesses a 530 keV gamma photon in 1.3% abundance. This is insufficient to cause any problems in imaging or quantitative studies. Both nuclides can be efficiently used with the gamma camera and low energy collimators.

The principal gamma energy of iodine-123 (159 keV) is somewhat higher than the 140 keV gamma of technetium-99m. This results in some advantage to the use of iodine-123 as can be seen in Figure 1. There is a better separation of the photopeak from the Compton scatter and the level of scattered radiation relative to the height of the photopeak is more favorable for iodine-123.

The short physical half-life of six hours for technetium-99m is appropriate to the studies performed with it. It presents no problem so far as availability is concerned because of its production by decay of molybdenum-99. The physical half-life of iodine-123, while nearly ideal for the usual studies of thyroid physiology, presents problems with supply. Shelf-life ordinarily can be no more than one day, and even this is not possible if there is any serious contamination with longer-lived

radioisotopes of iodine, especially iodine-124 and iodine-130.

BIOLOGICAL BEHAVIOR

Technetium-99m has been utilized to study the trapping function of the thyroid, this being the rate limiting process in hyperthyroidism. Previous studies have shown that the 20 minute technetium uptake is as diagnostically reliable as the 24 hour iodine uptake in assessment of the functional status of the thyroid (8). Another advantage of radio-pertechnetate is the ability to evaluate functional status while the patient is on thyroid blocking agents.

Diagnosis of hypothyroidism is no more accurate with technetium than with radioiodine. The uptake of technetium is affected by exogenous iodine, thyroid hormones and thyroid stimulating hormone in the same way as radioiodine uptake (8,19). The usual range of uptake of pertechnetate is rather low, on the average about 1-2%. This results in high levels of background activity, making determination of uptake somewhat more difficult. Recently computer techniques have been used which aid in this determination (9,20).

Radioiodine can also be used to evaluate trapping. However, binding occurs very rapidly so that in order to completely separate out the binding phase it would be necessary to use a binding blocking agent. Iodine-131 has not been entirely successful for this because of the high radiation dose incurred from the use of sufficient radioactivity to effectively determine early uptake of small proportions of the administered activity.

CLINICAL UTILIZATION

The determination of technetium-99m uptake by the thyroid is a convenient, one visit procedure. Usually the 20 minute uptake is determined (9). This may not be the maximal uptake during the first half-hour but

rarely would the error be of any significance. A variety of techniques utilizing the scanner (8,21) or camera (9,20,22) have been devised to determine uptake. The level of administered radioactivity has varied from one institution to another. We prefer to use about 2.5 - 3.5 mCi.

The radiation dose from ^{99m}Tc to the thyroid is about 0.3 rad/mCi. The whole body dose is somewhat more significant than with radiiodine, being about 0.013 rad/mCi (23). This should be compared with a radiation dose of about 1 rad/100 μCi to the thyroid and about 3 mrad/100 μCi whole body dose. This assumes a pure product. Even a small amount of longer-lived contaminants can double or treble the radiation dose.

The normal range of technetium uptake in the thyroid in our studies has been from 0.5 to 3.75%. This compares well with other series using imaging techniques for quantitation of uptakes. Others have found higher uptakes probably because of difficulties with high circulating background and salivary gland activity.

We have been looking at the clinical utilization of iodine-123, not only in comparison with iodine-131 for conventional uptake studies, but also in comparison with technetium-99m for trapping studies, in addition to comparing the imaging qualities of both radionuclides. A previous publication (15) indicated some differences in quality of images obtained with ^{99m}Tc and ^{123}I . Biological differences between the "trapping phase" image at 30 minutes and the "binding phase" image at 24 hours were noted in a few instances.

The radioiodine image is superior when uptake is very low (Fig. 2), in the presence of substernal extension (Fig. 3) and for detection of nodules along the border of the gland (Fig. 4). In several instances functioning nodules seen on the pertechnetate image were either normally

functioning or hypofunctioning relative to surrounding thyroid tissue on the radioiodine scan. This has also been noted by a number of other observers (11-16). The clinical diagnoses have varied in these patients and the clinical significance is not settled at this time.

We have, more recently, been carrying out two further studies of iodine-123 utilizing the intravenous route. These studies were initiated to determine the most appropriate time for imaging with iodine-123, to see if the standard apparatus for radioiodine uptakes is applicable to iodine-123 and to evaluate iodine-123 in the early phase of uptake, the "trapping phase" and compare its behavior with technetium. This last study is still being carried out.

In a now completed study (24) we determined thyroid uptake of intravenously administered iodine-123 and orally administered iodine-131 at 2, 6 and 24 hours. At 2 and 6 hours the percent uptake of the intravenous dose was slightly higher than the oral dose although not of statistical significance. The uptake at 24 hours was approximately the same for both routes (Fig. 5). The increase in the fraction of the dose in the thyroid at 24 hours over that in the gland at 6 hours was about 50 - 60%. This hardly compensates for radioactive decay. Assuming 15% uptake at 6 hours and 22% at 24 hours after a $100\mu\text{Ci}$ dose, the level of radioactivity in the gland at 6 hours would be $11\mu\text{Ci}$ and at 24 hours, $6\mu\text{Ci}$. Therefore, imaging at 6 hours could be performed with one-half the administered activity required for 24 hour imaging. The study also indicated no advantage to the intravenous route of administration.

A number of investigators have studied the early uptake of radioiodine after intravenous administration (25-29). The difficulties in quantitating these uptakes are the same as those encountered with technetium-99m,

compounded by a low photon flux. Most of these studies were performed prior to the availability of the gamma camera-computer combination. The presence of this equipment in combination with the use of iodine-123 makes such a study possible with a high degree of accuracy.

Our method of ^{99m}Tc uptake has been previously presented (20). It has now been utilized for early iodine-123 uptakes as well. The pin-hole collimator is positioned 19cm above the surface of the neck and sequential images are obtained over the next half-hour following intravenous administration of the radiopharmaceutical. A 4.75 mm pinhole is used with technetium-99m. For the dynamic part of the study, a 10 mm pinhole is used with iodine-123 because of the relatively low level of activity per patient available to us with this radionuclide ($\sim 90\mu\text{Ci}$). For detailed anatomical study with iodine-123 the smaller pinhole is used. The radioiodine studies were performed on each patient the day following the technetium study.

Following field correction of the pinhole images, curves were generated of counts per minute over the thyroid area and a background area just beneath the thyroid. The background curve was subtracted from the thyroid area curve to obtain a net thyroid uptake curve. The results were converted to percent uptake in the thyroid by comparison of a standard in a neck phantom counted with the same geometry and corrected for radioactive decay. The results were then submitted to a larger computer facility for processing using the Berman and Weiss SAAM program (30). This program smoothed the curves by least squares fitting and gave the slopes and intercepts for a two component solution.

At the time of this writing 26 patients have been studied by this procedure. Of these, three were hyperthyroid and 23 euthyroid. One patient was thought to have Hashimotos thyroiditis. A comparison of the

technetium and radioiodine uptakes in a typical euthyroid individual are seen in Fig. 6. As expected the technetium uptake is very rapid in the first ten minutes ($T_{1/2} \sim 5$ min.) and then levels off. The iodine uptake is also very rapid in this same period of time with the level of uptake somewhat higher than the technetium uptake. It too, levels off to a slope approaching zero in the time scale of the graph. The second component of this curve can not be accurately determined because it has a $T_{1/2}$ of about 6 - 10 hours and recording was only for 1/2 hour.

Several interesting examples have been noted already in our short series. One patient (Fig. 7) with hyperthyroidism confirmed by several in-vitro studies had a technetium curve which was distinctly abnormal (maximum uptake 5.1%) while the radioiodine uptake during the first half hour was consistently lower than the technetium uptake. The twenty-four hour radioiodine uptake in this patient was only 24.9%. A more typical example of hyperthyroidism is patient J.C. (Fig. 8) where the iodine uptake was always higher than the technetium uptake with both being high.

Another interesting variant is the data on patient D.H. (Fig. 9), thought to have Hashimotos' thyroiditis although autoantibodies were negative and the serum thyroxine level was normal. The 24 hour radioiodine uptake was elevated (47.6%). The curves show an early peak of technetium uptake at about 12 minutes and then a decline. The radioiodine uptake was consistently high, reaching 9.1% at 30 minutes.

The study is continuing and it is hoped to learn more about the early thyroid uptake of iodine and technetium. We are also obtaining close-up scintiphotos of the thyroid at 30 minutes with technetium, and at 30 minutes and 24 hours with radioiodine. It should be interesting to see any correspondance between the 30 minute images of the two radiopharmaceuticals

in situations where the 24 hour iodine image differs substantially from the technetium image.

With this technique it should be possible to evaluate the effects of washout with small doses of intravenous perchlorate. It may be possible to localize areas within the gland where there may be a binding deficit and to quantify the binding of iodine at these very early times after administration.

CONCLUSIONS

Both technetium-99m and iodine-123 can be used to advantage in assessing thyroid function and anatomy. They have similar principal gamma photons and their short physical half-lives result in low radiation dose, thus allowing administration of large quantities of activity. The very early uptakes of these radionuclides by the thyroid do not bear a consistent relationship and this requires further study. The clinical value of iodine-123 depends on its being consistently available at a reasonable cost.

REFERENCES

1. Ben Porath, M., Hochman, A., Gross, J. A comparison of iodine-125 and iodine-131 as tracers in the diagnosis of thyroid disease. II. Clinical Aspects. *J. Nucl. Med.* 7: 99-106, 1966.
2. Charkes, N.D., Sklaroff, D.M. The use of iodine-125 in thyroid scintiscanning. *Am. J. Roentgenol; Radium Ther. and Nucl. Med.* 90: 1052-1058, 1963.
3. Endlich, H., Harper, P., Beck, R., Siemans, W., Lathrop, K. The use of I^{125} to increase isotope scanning resolution. *Am. J. Roentgenol; Radium Ther. and Nucl. Med.* 87: 148-155, 1962.
4. Dodds, W. J., Powell, M.R. Thyroid scanning with technetium-99m pertechnetate. *Radiology* 91: 27-31, 1968.
5. Sanders, T.P., Kuhl, D.E. Technetium pertechnetate as a thyroid scanning agent. *Radiology* 91: 23-26, 1968.
6. Haas, J.T., Schmidt, K.J., Wolf, R.E. Erfahrungen mit der Schilddrüsenszintigraphie unter Verwendung von ^{99m}Tc -Pertechnetat, Übersicht über 2000 Fälle. *Fortschr. Roentgenstr.* 109: 222-226, 1968.
7. Hurley, P.J., Strauss, H.W., Pavoni, P., Langan, J.K., Wagner, H.N. The scintillation camera with pinhole collimator in thyroid imaging. *Radiology* 101: 133-138, 1971.
8. Atkins, H.L. Technetium-99m pertechnetate uptake and scanning in the evaluation of thyroid function. *Sem. Nucl. Med.* 1: 345-355, 1971.
9. Hurley P.J., Maisey, M.N., Natarajan, T.K., Wagner H.N. Jr. A computerized system for rapid evaluation of thyroid function. *J. Clin. Endocr. and Metab.* 34: 354-360, 1972.

10. DeGrossi, O., Gotta, H., Olivari, A., Pecorini, V., Chwojnik, A.
Possibilities of using Tc^{99m} in place of radioiodine in thyroid function studies. *Nuclearmed.* 4: 383-390, 1965.
11. Massin, J.P., Karam, J., Savoie, J.C. Comparison du technetium 99m et de l'iode 131 en scintigraphie thyroïdienne. *Annales d'Endocrin.* 31: 962-968, 1970
12. Steinberg, M., Cavalieri, R.R., Choy, S.H. Uptake of technetium-99-pertechnetate in a primary thyroid carcinoma: need for caution in evaluating nodules. *J. Clin. Endocr. and Metab.* 31: 81-84, 1970
13. Strauss, H.W., Hurley, P.J., Wagner, H.N. Jr. Advantages of ^{99m}Tc pertechnetate for thyroid scanning in patients with decreased radioiodine uptake. *Radiology* 97: 307-310, 1970
14. dos Remedios, L.V., Weber, P.M., Jasko, I.A. Thyroid scintigraphy in 1000 patients: rational use of ^{99m}Tc and ¹³¹I compounds. *J. Nucl. Med.* 12: 673-677, 1971.
15. Atkins, H.L., Klopper, J.F., Lambrecht, R. Wolf, A. A comparison of ^{99m}Tc and ¹²³I in thyroid imaging. *Am. J. Roentgenol; Radium Ther. and Nucl. Med.* 117; 195-201, 1973
16. Usher, M.S., Arzoumanian, A.Y. Thyroid nodule scans made with pertechnetate and iodine may give inconsistent results. *J. Nucl. Med.* 12: 137-138, 1971.
17. Myers, W. Radioiodine-123 for scanning. *J. Nucl. Med.* 7: 390, 1966.
18. Goolden A., Glass H., Silvester, D. The choice of a radioactive isotope for the investigation of thyroid disorders. *Brit. J. Radiol.* 41:20-25, 1968.

19. Kuba, J., Wiedermann, M., Komenda, S. Zur problematik der ^{99m}Tc -pertechnetatspeicherung in der Schilddrüse. *Nuclearmed.* 6: 53-64, 1967.
20. Atkins, H.L., Klopper, J.F. Measurement of thyroid uptake of technetium-99m measured by the gamma camera and computer. *Am. J. Roentgenol; Radium Ther. and Nucl. Med.* 118: 831-835, 1973.
21. Shimmins, J., Hilditch, T., Harden, R.McG., Alexander, W.D., Thyroidal uptake and turnover of the pertechnetate ion in normal and hyperthyroid subjects. *J. Clin. Endocrinol.* 28: 575-581, 1968.
22. Castronovo, F.P. Jr., Ring R. III The rapid determination of the early ^{99m}Tc pertechnetate thyroid uptake using a multichannel analyzer. *Int. J. Appl. Rad. and Isotopes* 24: 297-299, 1973.
23. Smith, E.M. Internal dose calculation for ^{99m}Tc . *J. Nucl. Med.* 6: 231-251, 1965.
24. Atkins, H.L., Bradley-Moore, P.R., Ansari, A., Lambrecht, R.M., Wolf, A.P. A comparison of the thyroidal uptake of radioiodine administered intravenously (^{123}I) and orally (^{131}I). Submitted for publication.
25. Higgins, H.P. The ten-minute uptake of I^{131} ; a clinical study and comparison with other tests of thyroid function. *J. Clin. End. and Metab.* 19: 557-566, 1959.
26. Kriss, J.P. Uptake of radioactive iodine after intravenous administration of tracer doses. *J. Clin. End. and Metab.* 11: 289-297, 1951.
27. Larsson, L., Jonsson, L., Continuous registration of thyroid uptake after intravenous injection of radioactive iodine. *Acta. Radiol.* 43: 81-88, 1955.
28. Rosenthal, L. A fifteen minute test of the rate of thyroid trapping of radioiodine. *J. Nucl. Med.* 5: 657-663, 1964.

29. Mosier, H.D., Armstrong, M.K., Schultz, M.A. Measurement of the early uptake of radioactive iodine by the thyroid gland. A method requiring reduced irradiation. *Pediatrics* 31: 426-432, 1963.
30. Berman, M., Weiss, M. Users manual for SAAM (Simulation, Analysis and Modeling), National Institutes of Health, Bethesda, Md. 1963.

ILLUSTRATIONS

- Fig. 1 Comparative spectra of iodine-123 and technetium-99m obtained with the use of a 2 x 2 inch sodium iodide crystal. The source of radioactivity was placed in an IAEA neck phantom used to measure thyroidal uptake of radioiodine. BNL Neg. #11-513-73
- Fig. 2 Residual thyroid tissue in the neck following previous thyroidectomy and radioiodine for carcinoma. The iodine-123 image (below) is clearly superior to the technetium-99m image.
BNL Neg. #12-106-71
- Fig. 3 Substernal nodular goiter. The technetium image (above) does not clearly delineate the gland but only suggests a functioning nodule in the left upper pole. There is no clear evidence of substernal extension. The radioiodine image (below) more clearly demonstrates multiple functioning nodules and definite substernal extension. Reproduced with permission of the American Journal of Roentgenology, Radium Therapy and Nuclear Medicine (Ref. 15) BNL Neg. #12-661-71.
- Fig. 4 The cold nodule along the left inferior portion of the thyroid is somewhat obscured by background activity in the technetium image (above) but clearly seen in the iodine image (below). Reproduced with permission of the American Journal of Roentgenology, Radium Therapy and Nuclear Medicine (Ref. 15) BNL Neg. #12-425-71
- Fig. 5 A comparison of the thyroidal uptake of radioiodine at 24 hours following intravenous (^{123}I) and oral ($^{99\text{m}}\text{Tc}$) administration in 29 patients. BNL Neg. #11-514-73

- Fig. 6** The early technetium and radioiodine uptake in a euthyroid individual. The horizontal broken line at 3.75% indicates in this, and subsequent figures, the upper limit of normal for technetium uptakes. BNL Neg. # 11-516-73
- Fig. 7** A patient with hyperthyroidism based on clinical evaluation and in-vitro tests shows the technetium uptake to be higher than the iodine uptake. The 24 hour radioiodine uptake was normal. BNL Neg. #11-728-73
- Fig. 8** Uptake curves in a patient with hyperthyroidism. Note an iodine uptake of greater than 20% in less than 30 minutes. BNL Neg. #11-729-73
- Fig. 9** Patient with suspected Hashimoto's thyroiditis. The radioiodine uptake at 24 hours was elevated. At 30 minutes it also seems high but no normal values for this technique have been established at this time. Note the early peaking and slow descent of the technetium curve. BNL Neg. #11-727-73

COMPARATIVE SPECTRA OF ^{99m}Tc
AND ^{123}I IN NECK PHANTOM

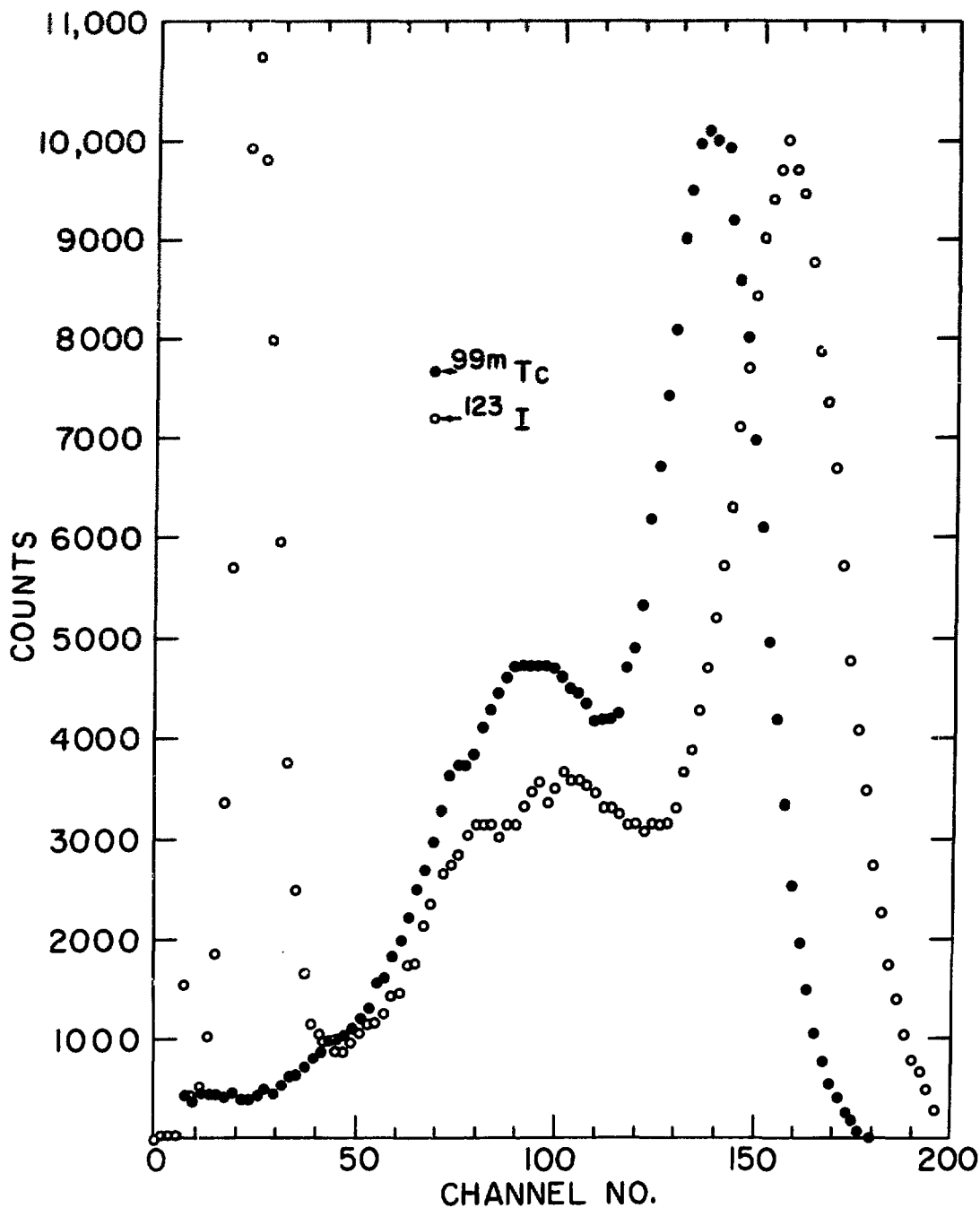
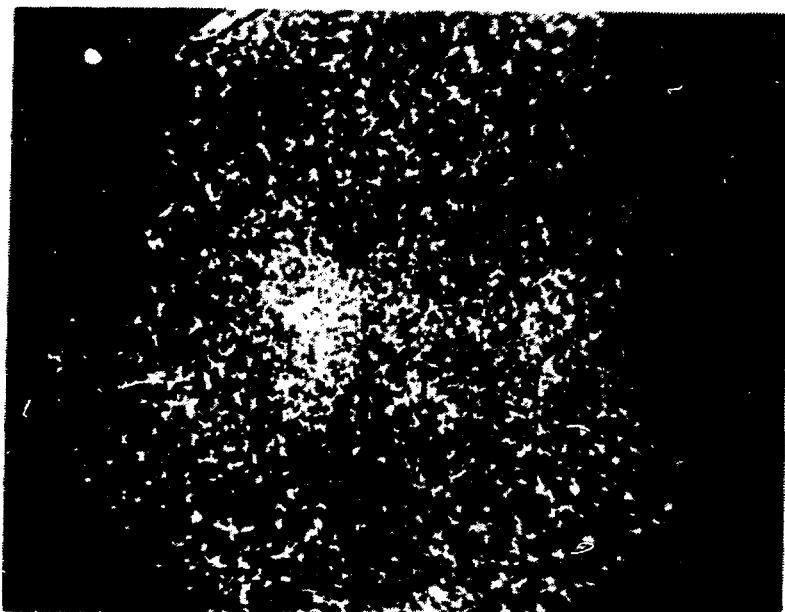
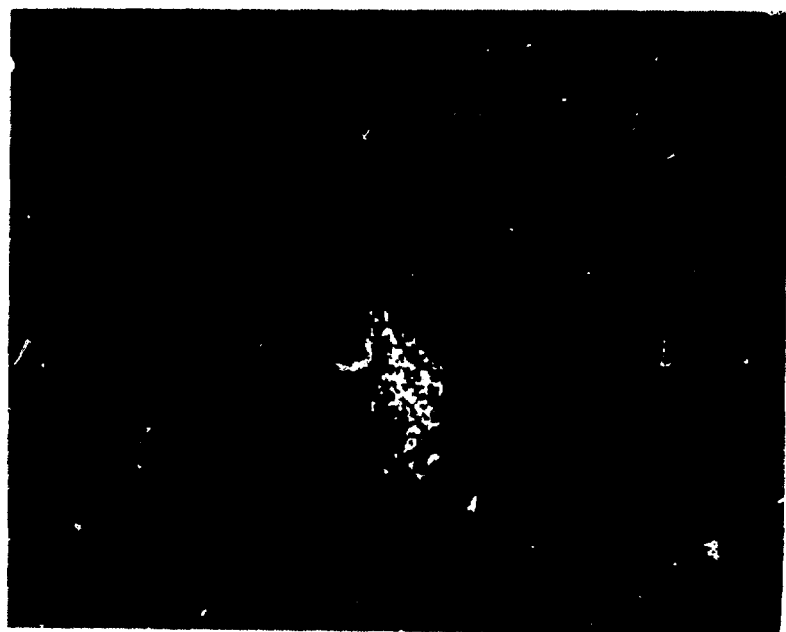

FIGURE 1

A.T. 53♀ HYPOTHYROID \bar{p} SURGERY & RAI




$^{99m}\text{TcO}_4^-$
0.01%



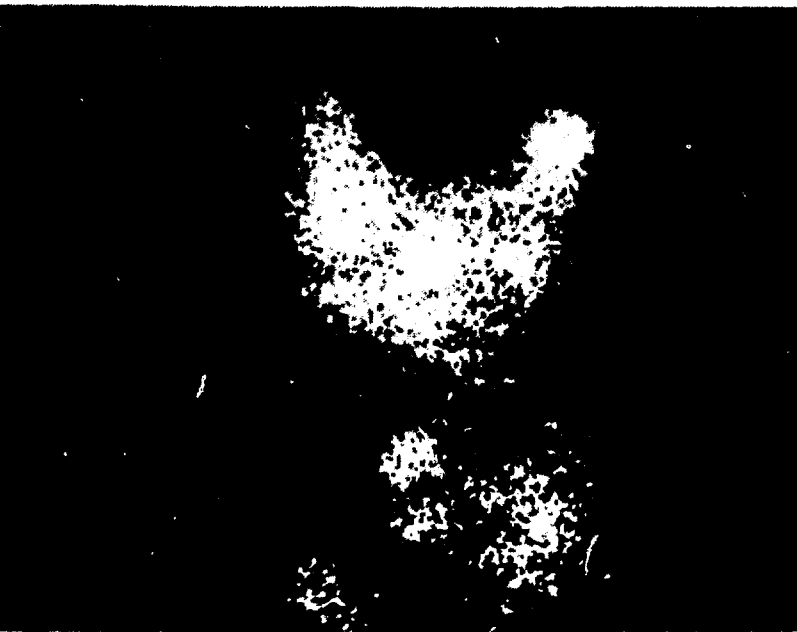$^{123}\text{I}^-$
2.4%

FIGURE 2

E.B. 53 ♀



$^{99m}\text{TcO}_4^-$

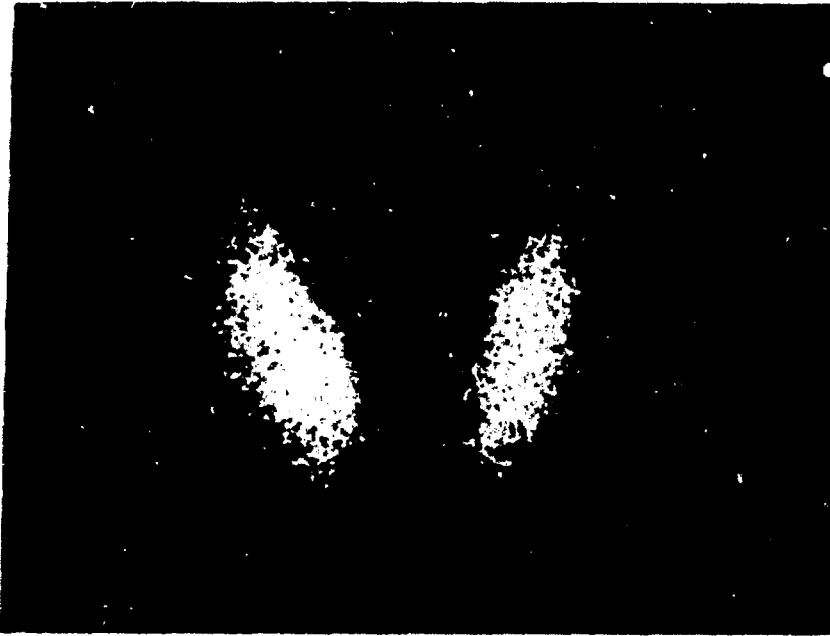


$^{123}\text{I}^-$

10.5%


FIGURE 3

J.F. 24 ♀



$^{99m}\text{TcO}_4^-$

1.37 %



$^{123}\text{I}^-$

23.5 %

FIGURE 4

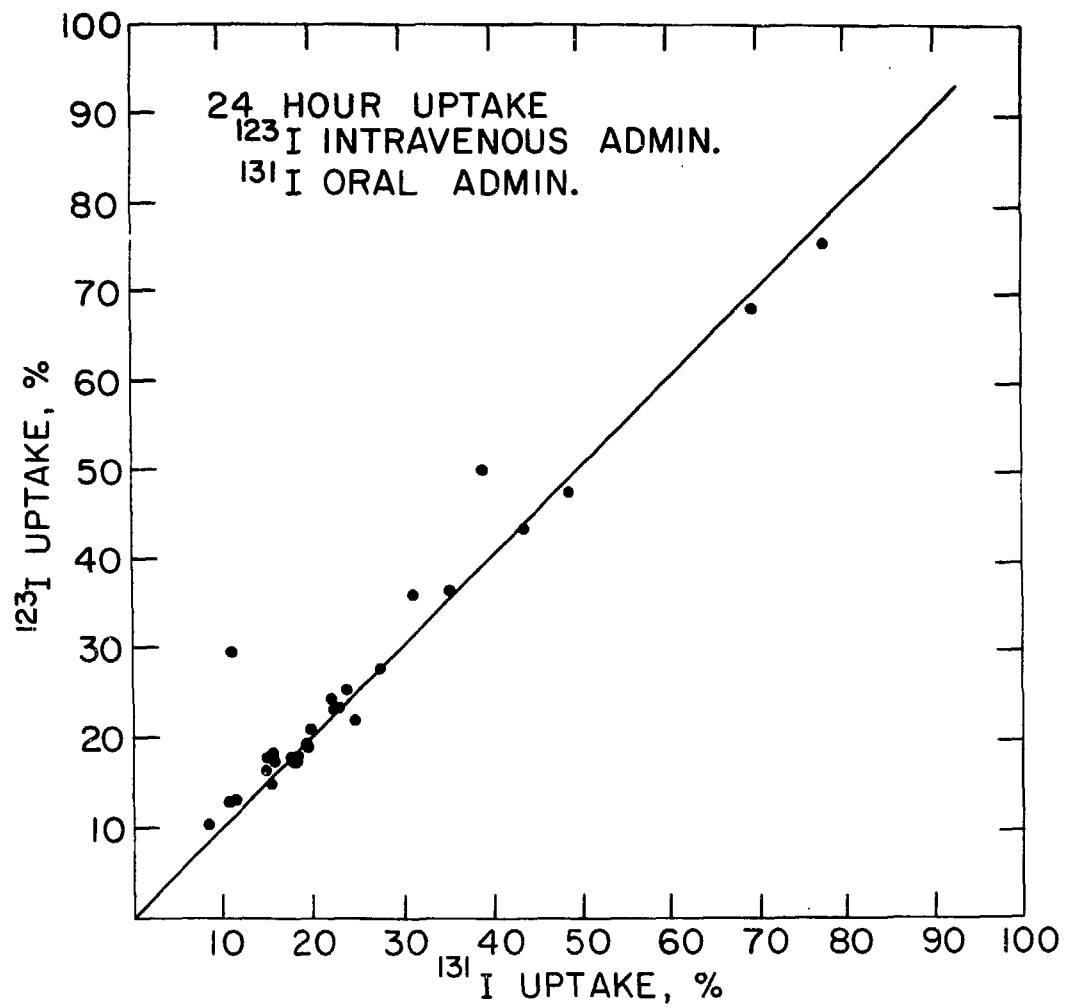


FIGURE 5

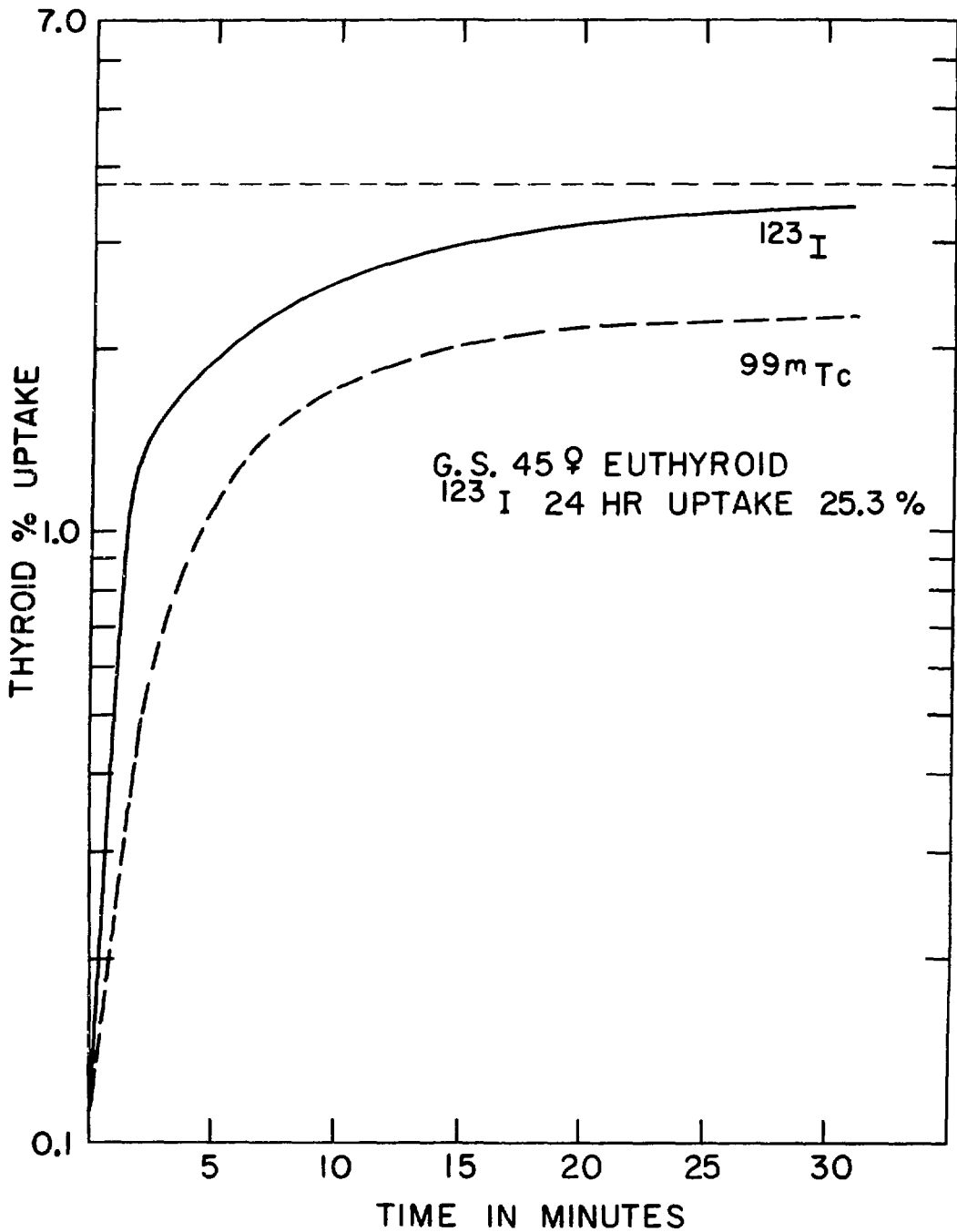


FIGURE 6

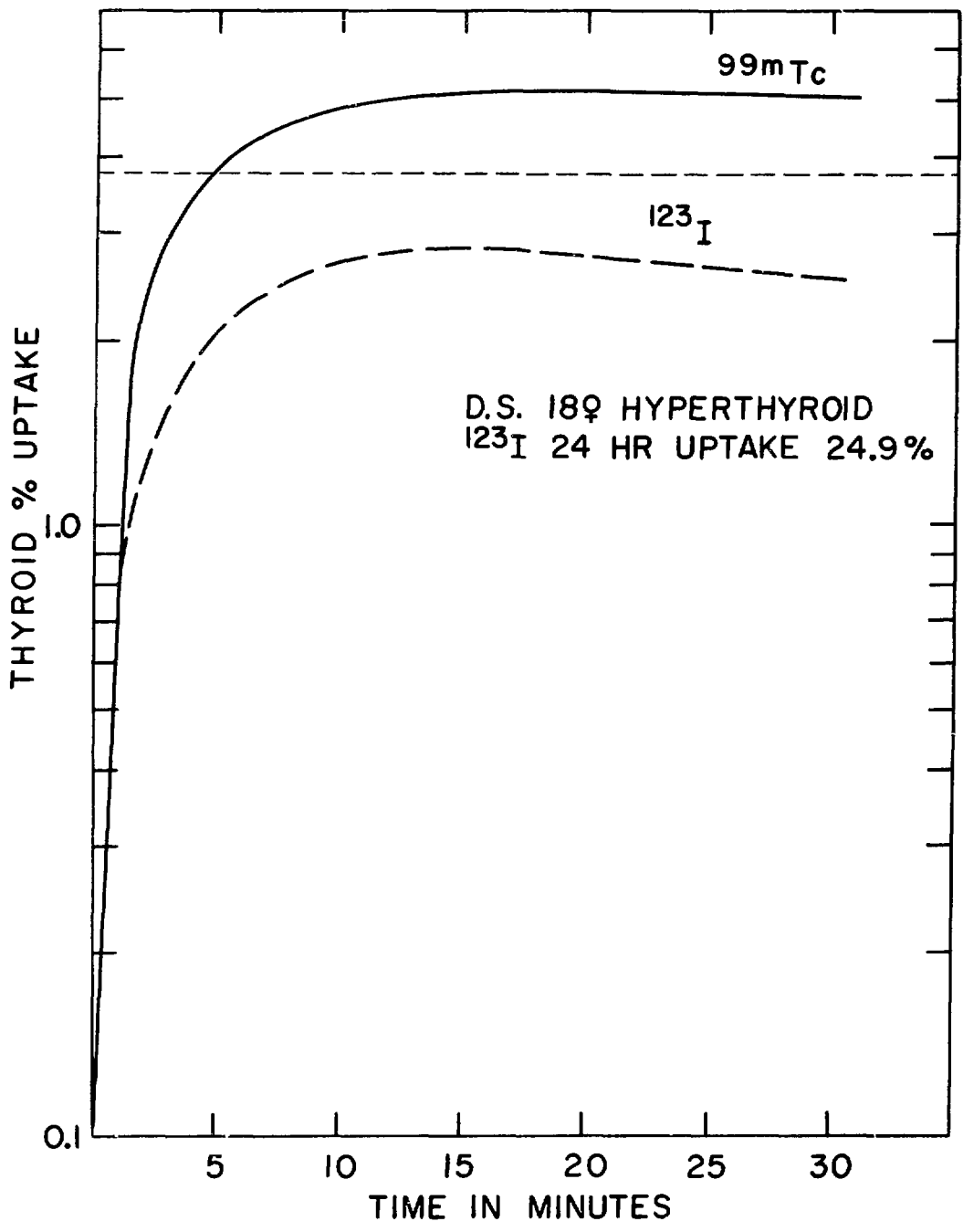


FIGURE 7

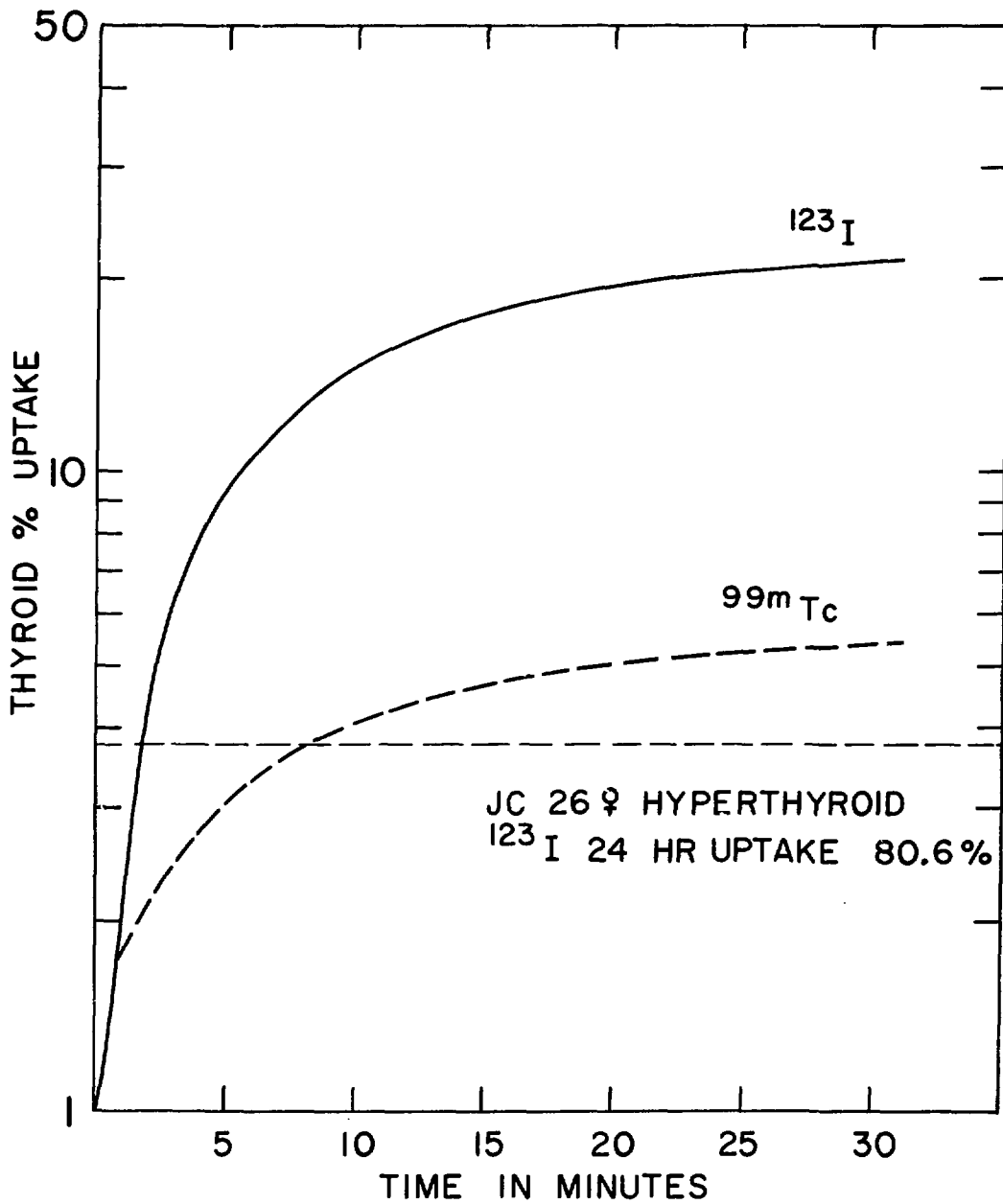


FIGURE 8

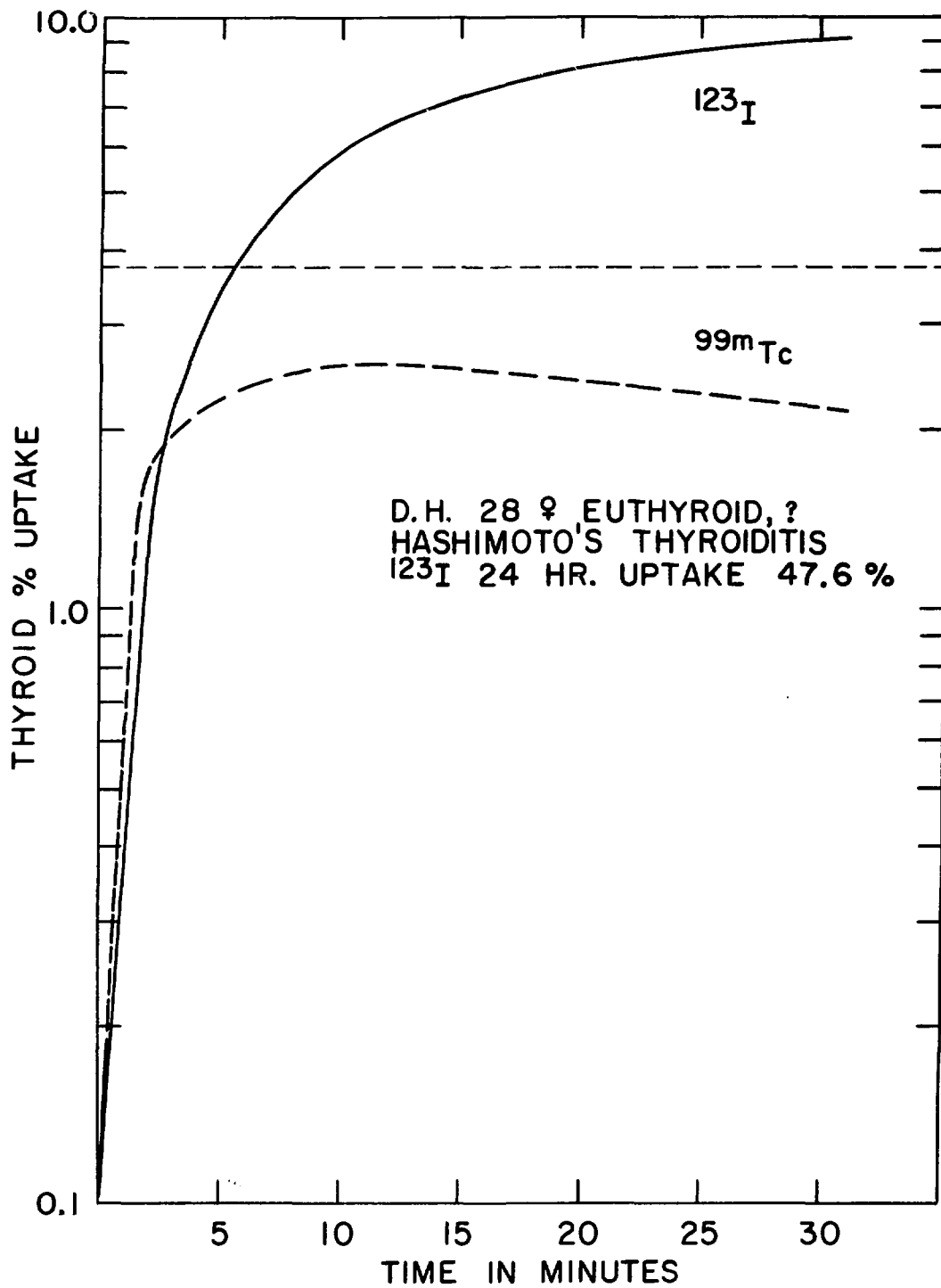


FIGURE 9