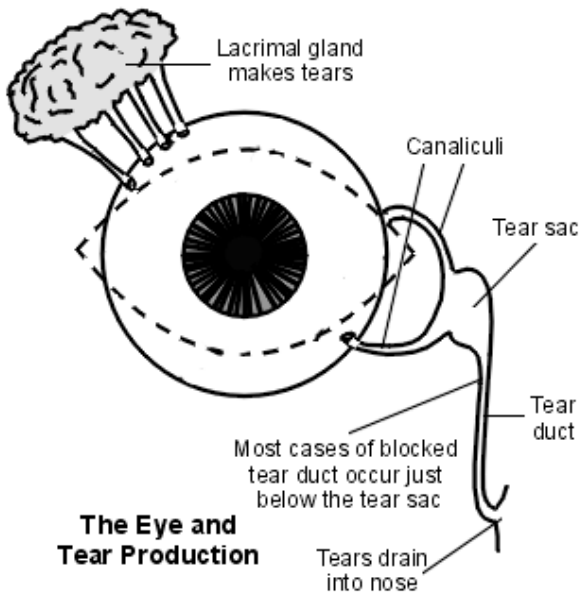


## Dacryocystitis and canaliculitis

The lacrimal drainage system consists of the puncta - upper and lower within the eyelids and which are the opening to the upper and lower canaliculus. These meet at the common canaliculus and open into the lacrimal (tear) sac. This runs parallel to the nose and is separated from the middle meatus of the nasal cavity by two thin plates of bone. It continues down to become the nasolacrimal duct (tear duct) which opens out into the inferior nasal meatus.



### Dacryocystitis<sup>[1]</sup>

Dacryocystitis is an inflammation of the lacrimal sac, often as a result of infection. It may be acute or chronic. For anatomical reasons, it occurs more frequently on the left side. An ocular origin for inflammation of the lacrimal system is less common than a nasal origin.

Rarely, congenital dacryocystocele can occur as part of the picture of nasolacrimal duct obstruction. The incidence of congenital dacryocystocele varies from 1% to 12%<sup>[2]</sup> This is a serious condition because the orbital septum is poorly formed in infants and there is a significant risk of spread (orbital cellulitis and its complications).

## Epidemiology

It is more common in females. It tends to occur either in infants (uncommon) or in adults (much more common) over the age of 40 years, peak age 60–70 years.

## Presentation

### Acute dacryocystitis

- Symptoms and signs are over the region of the lacrimal sac (but may spread to the nose and face with teeth pain being experienced by some). Therefore, look just lateral and below the bridge of the nose for:
  - Excess tears (epiphora) – almost invariably.
  - Pain.
  - Redness.
  - Swelling.

The patient may complain of decreased visual acuity owing to the excess tears and an abnormal tear composition<sup>[3]</sup>.

Examination will reveal a tender, tense, red swelling ( $\pm$  preseptal cellulitis in severe cases). Mucopurulent discharge can be expressed from the punctum. There may be a fever and an elevated leukocyte count too.

### Chronic dacryocystitis<sup>[4]</sup>

This may present with a history of chronic or recurring epiphora and may have persistent redness of the medial canthus. There may be a painless or recurring swelling over the lacrimal sac, and pressure over this will result in reflux of mucopurulent material through the lower punctum.

## Differential diagnosis

- [Orbital or facial cellulitis](#) (discharge cannot be expressed from the punctum).
- Acute ethmoid or frontal [sinusitis](#).

- Dacryocystocele (mild enlargement of a non-inflamed lacrimal sac in an infant).

## Investigations

- In severe or atypical cases (eg, non-responsive to antibiotics), culture the expressed contents of the sac.
- CT scan of the orbit and the paranasal sinuses can be useful.
- A dacryocystography (DCG) may be performed where structural abnormalities are suspected.

## Associated diseases

This is most commonly associated with nasolacrimal duct obstruction which results in stasis of the lacrimal sac contents. Less commonly, it is associated with anatomical abnormalities of the lacrimal sac or with nasal or sinus surgery. Nasal disease may be found in a number of these patients – eg, various forms of rhinitis, trauma or the presence of a foreign body. Some common systemic diseases associated with chronic dacryocystitis include [granulomatosis with polyangiitis](#), [sarcoidosis](#), and [systemic lupus erythematosus](#). Rarely, there may be a lacrimal sac tumour.

## Management

### Acute dacryocystitis management

- Patients tend to be managed on an outpatient basis unless they are systemically unwell.
- Initially, treatment of acute dacryocystitis is with oral antibiotics and analgesia. Empiric antibiotics should include Gram-positive and Gram-negative coverage<sup>[3]</sup>.
- The regime is guided by clinical response but, typically, a 10- to 14-day course is required.
- Incision and drainage may be considered if the infection extends outside the sac and a superficial skin abscess is formed. This carries the risk of forming a fistula, resulting in tears draining directly to the skin surface<sup>[5]</sup>. However, a study found that early surgery produced faster resolution of the condition than surgery which was deferred until the infection had been treated conservatively<sup>[6]</sup>.

## Chronic dacryocystitis management<sup>[7]</sup> <sup>[8]</sup>

- Non-surgical treatment involves warm compresses, massage and probing of the nasolacrimal duct.
- Probing involves inserting a fine metal probe via the punctum and canalicular system and passing it into the nasolacrimal sac, past the obstruction. This can often be done without a general anaesthetic. If there is acute infection, the procedure is usually deferred for a few days, until antibiotics have taken effect<sup>[9]</sup> .
- If this is not effective, surgical treatment is a DCR (see box below).
- Balloon dacryoplasty, nasolacrimal intubation and nasolacrimal stenting have all been attempted with varying degrees of success<sup>[3]</sup>

## Congenital dacryocystocele management<sup>[10]</sup>

- One study reported that conservative management, involving gentle massage over the lacrimal sac, warm compresses ± topical and systemic antibiotics, was effective in all cases.
- Probing and irrigation may resolve the obstruction.
- Be aware that serious infection can develop rapidly.

See also the separate [Congenital Nasolacrimal Duct Obstruction](#) article.

### Important information

#### DCR

This is a procedure that creates a drainage passage between the lacrimal sac and the nasal mucosa of the middle meatus so preventing accumulation of material in the lacrimal sac. It is indicated in adult patients who have a nasolacrimal duct obstruction that either causes symptoms or that results in infection of the lacrimal sac. It is carried out under general anaesthetic. It may be done externally by the ophthalmologists or - increasingly - endoscopically by an ophthalmology/ear, nose and throat team<sup>[7]</sup> .

Endolaser® techniques are also available and less disruptive (they cause less damage and can be performed under a local anaesthetic)<sup>[8]</sup> .

## Complications

These lie mainly in the risk of spread which can be superficial (eg, cellulitis), deep (eg, orbital cellulitis, orbital abscess, meningitis) or generalised (eg, sepsis) <sup>[11]</sup> . These complications are rare and tend to be seen in the immunocompromised individuals and in cases of congenital dacryocystitis.

Intraocular surgery – such as cataract surgery – should be postponed until the dacryocystitis (whether acute or chronic) has been treated, as there is a significant risk of ensuing endophthalmitis. However, there are complications associated with DCR too:

- Failed procedure.
- Cutaneous scarring.
- Epistaxis.
- Cellulitis.
- Cerebrospinal fluid rhinorrhoea (if the subarachnoid space is inadvertently entered).

## Prognosis

This is good if managed promptly and surgery is not delayed once the acute phase has resolved. However, congenital dacryocystitis can be very serious and is associated with significant morbidity and mortality if not treated promptly and aggressively.

## Chronic canaliculitis

This is an uncommon condition where the canaliculi become chronically infected. Common pathogens reported are *Staphylococcus* spp., *Streptococcus* spp., *Actinomyces* spp. and *Propionibacterium* spp. <sup>[12]</sup> .

## Presentation

### Symptoms

- Unilateral epiphora.
- Chronic mucopurulent conjunctivitis (refractory to usual treatment).

### Signs

- Oedema of the canaliculus: look for a swelling at the medial end of the upper or the lower lid.
- 'Pouting' punctum: this is turned out and is prominent.
- Gentle compression of the canaliculi results in expression of concretions: solid, pale-yellow fatty material.

## Investigation

High-resolution ultrasound biomicroscopy may be helpful<sup>[13]</sup> .

## Differential diagnosis

- Dacryocystitis.
- Nasolacrimal duct obstruction.
- [Conjunctivitis](#).

## Management<sup>[14]</sup>

- Removal of the obstruction concretions (by expressing them through the punctum) and topical antibiotics (eg, ciprofloxacin qds for 10 days) may be effective in some cases.
- Surgery (canaliculectomy or punctoplasty) is often performed, often with expression of concretions from the duct and irrigation with antibiotics or an iodine solution. Occasionally, more extensive surgery is needed.
- One study suggested that intracanalicular antibiotics can be helpful as an alternative to surgery.

## Canalicular obstruction<sup>[15]</sup> <sup>[16]</sup>

Obstruction of the lacrimal canaliculi may be congenital (see the separate [Congenital Nasolacrimal Duct Obstruction](#) article) or acquired. Acquired causes include trauma, scarring, inflammatory conditions, local tumours, Bell's palsy, radiotherapy and certain drugs - eg, docetaxel.

Presenting features are excess tearing ± sticky discharge and irritation.

## Investigations

- Syringing and probing to identify the site of obstruction.

- The Jones' fluorescein dye test.

## Management

- Treat infection if present.
- Syringing and probing may be used but they risk trauma to the duct and may aggravate the condition.
- Surgical treatment – there are various treatment methods, including punctoplasty, insertion of a silicone tube, trephination, balloon canaliculoplasty, endocanicular laser surgery, conjunctivodacryocystorhinostomy (CDCR) and canalicodacryocystorhinostomy (canaliculo-DCR)<sup>[17]</sup>. Laser or balloon canaliculoplasty may be well tolerated and a good alternative to CDCR<sup>[18]</sup>.

---

## Further reading

- [Cavazza S, Laffi GL, Lodi L, et al](#); Congenital dacryocystocele: diagnosis and treatment. *Acta Otorhinolaryngol Ital.* 2008 Dec;28(6):298–301.
- [Zaveri J, Cohen AJ](#); Lacrimal canaliculitis. *Saudi J Ophthalmol.* 2014 Jan;28(1):3–5. doi: 10.1016/j.sjopt.2013.11.003. Epub 2013 Nov 13.

## References

1. [Dacryocystitis \(acute\) – clinical management guidelines](#); College of Optometrists, September 2008
2. [Pujari A](#); Congenital dacryocystocele. *BMJ Case Rep.* 2016 Dec 9;2016. pii: bcr-2016-218029. doi: 10.1136/bcr-2016-218029.
3. [Taylor RS, Ashurst JV](#); Dacryocystitis
4. [Dacryocystitis \(chronic\) – clinical management guidelines](#); College of Optometrists, September 2008
5. [Barrett RV, Meyer DR](#); Acquired lacrimal sac fistula after incision and drainage for dacryocystitis: a multicenter study. *Ophthal Plast Reconstr Surg.* 2009 Nov-Dec;25(6):455–7. doi: 10.1097/IOP.0b013e3181b80c59.
6. [Li EY, Wong ES, Wong AC, et al](#); Primary vs Secondary Endoscopic Dacryocystorhinostomy for Acute Dacryocystitis With Lacrimal Sac Abscess Formation: A Randomized Clinical Trial. *JAMA Ophthalmol.* 2017 Dec 1;135(12):1361–1366. doi: 10.1001/jamaophthalmol.2017.4798.

7. [Endoscopic dacryocystorhinostomy](#); NICE Interventional Procedures Guidance, February 2005
8. [Zengin MO, Eren E](#); The return of the jedi: comparison of the outcomes of endolaser dacryocystorhinostomy and endonasal dacryocystorhinostomy. *Int Forum Allergy Rhinol.* 2014 Jun;4(6):480–3. doi: 10.1002/alr.21302. Epub 2014 Feb 20.
9. [Wong RK, VanderVeen DK](#); Presentation and management of congenital dacryocystocele. *Pediatrics.* 2008 Nov;122(5):e1108–12. Epub 2008 Oct 27.
10. [Mimura M, Ueki M, Oku H, et al](#); Process of spontaneous resolution in the conservative management of congenital dacryocystocele. *Clin Ophthalmol.* 2014 Feb 26;8:465–9. doi: 10.2147/OPHTH.S58342. eCollection 2014.
11. [Lee S, Yen MT](#); Management of preseptal and orbital cellulitis. *Saudi J Ophthalmol.* 2011 Jan;25(1):21–9. doi: 10.1016/j.sjopt.2010.10.004. Epub 2010 Dec 10.
12. [Zaldivar RA, Bradley EA](#); Primary canaliculitis. *Ophthal Plast Reconstr Surg.* 2009 Nov–Dec;25(6):481–4.
13. [Tao H, Xu LP, Han C, et al](#); Diagnosis of lacrimal canalicular diseases using ultrasound biomicroscopy: a preliminary study. *Int J Ophthalmol.* 2014 Aug 18;7(4):659–62. doi: 10.3980/j.issn.2222-3959.2014.04.15.13. eCollection 2014.
14. [Kaliki S, Ali MJ, Honavar SG, et al](#); Primary canaliculitis: clinical features, microbiological profile, and management outcome. *Ophthal Plast Reconstr Surg.* 2012 Sep–Oct;28(5):355–60. doi: 10.1097/IOP.0b013e31825fb0cd.
15. [Nasolacrimal duct obstruction \(nasolacrimal drainage dysfunction\)](#); College of Optometrists, March 2016
16. [Liarakos VS, Boboridis KG, Mavrikakis E, et al](#); Management of canalicular obstructions. *Curr Opin Ophthalmol.* 2009 Sep;20(5):395–400.
17. [Athanasiov PA, Prabhakaran VC, Mannor G, et al](#); Transcanalicular approach to adult lacrimal duct obstruction: a review of instruments and methods. *Ophthalmic Surg Lasers Imaging.* 2009 Mar–Apr;40(2):149–59.
18. [Baek BJ, Hwang GR, Jung DH, et al](#); Surgical results of endoscopic dacryocystorhinostomy and lacrimal trephination in distal or common canalicular obstruction. *Clin Exp Otorhinolaryngol.* 2012 Jun;5(2):101–6. doi: 10.3342/ceo.2012.5.2.101. Epub 2012 Jun 12.

**Disclaimer:** This article is for information only and should not be used for the diagnosis or treatment of medical conditions. Egton Medical Information Systems Limited has used all reasonable care in compiling the information but makes no warranty as to its accuracy. Consult a doctor or other healthcare professional for diagnosis and treatment of medical conditions. For details see our [conditions](#).



<b>Last updated by:</b> Dr Laurence Knott 17/08/2021	
<b>Peer reviewed by:</b> Dr Colin Tidy, MRCGP 17/08/2021	<b>Next review date:</b> 16/08/2026

---

View this article online at: [patient.info/doctor/dacryocystitis-and-canaliculitis](https://patient.info/doctor/dacryocystitis-and-canaliculitis)

Discuss Dacryocystitis and canaliculitis and find more trusted resources at [Patient](https://patient.info).

---



To find out more visit [www.patientaccess.com](https://www.patientaccess.com)  
or download the app



Follow us

