




Contents lists available at ScienceDirect

## The Journal of Foot &amp; Ankle Surgery

journal homepage: www.jfas.org



## Original Research

## Ankle Syndesmotic Fixation Using Two Screws: Risk of Injury to the Perforating Branch of the Peroneal Artery

Keith Penner, DPM<sup>1,2</sup>, Karim Manji, DPM<sup>3</sup>, Mathew Wedel, PhD<sup>4</sup>, David Shofler, DPM<sup>2</sup>, Jonathan Labovitz, DPM, FACFAS<sup>5</sup><sup>1</sup> Podiatrist, HealthCare Partners Affiliate Medical Group, Huntington Beach, CA<sup>2</sup> Assistant Professor, Department of Podiatric Medicine, Surgery, and Biomechanics, Western University of Health Sciences College of Podiatric Medicine, Pomona, CA<sup>3</sup> Richmond Square Medical Centre, Calgary, Alberta, Canada<sup>4</sup> Assistant Professor, Department of Anatomy, Western University of Health Sciences College of Osteopathic Medicine of the Pacific and College of Podiatric Medicine, Pomona, CA<sup>5</sup> Associate Professor, Department of Podiatric Medicine, Surgery, and Biomechanics, and Medical Director, Foot and Ankle Center, Western University of Health Sciences College of Podiatric Medicine, Pomona, CA

## ARTICLE INFO

Level of Clinical Evidence: 5

## Keywords:

ankle fracture  
complication  
screw fixation  
syndesmotic ligament  
tibia  
tibiofibular transfixation

## ABSTRACT

Trans-syndesmotic screws are commonly used to repair syndesmosis ruptures and stabilize the ankle joint. Just as with any surgery, the neurovascular structures can be compromised, causing complications. We evaluated the position of the perforating branch of the peroneal artery to define the risk of arterial compromise during placement of 2 trans-syndesmotic screws. In 37 cadaveric specimens, 2 trans-syndesmotic screws were inserted 2 and 4 cm proximal to the ankle joint. The distances between the perforating branch of the peroneal artery and the screws and the other anatomic landmarks were measured. Significant differences were calculated between the male and female limbs, and regression analysis was used to determine the significant associations between the tibial length and screw location. The perforating branch of the peroneal artery passed through the interosseous membrane  $3.42 \pm 0.6$  cm proximal to the tibial plafond. The artery was located up to 4 mm from the superior and inferior screws 51.4% and 10.8% of the time, respectively. A greater percentage of male specimens displayed close proximity between the artery and the superior screw, and the distance of the artery from the distal fibula was statistically significant compared with the distance in the female specimens. Regression analysis revealed that the greater the tibial length, the closer the superior screw was to the artery, with a negative correlation discovered for the inferior screw. We concluded that superior screw placement increased the risk of injuring the perforating branch of the peroneal artery injury, and the likelihood of injuring the artery with the inferior screw increased as the length of the tibia decreased.

© 2014 by the American College of Foot and Ankle Surgeons. All rights reserved.

Ankle injuries are one of the most common musculoskeletal complaints presenting to the emergency department and commonly involve injury to the ankle syndesmosis (1,2). Syndesmotic injury can be an isolated event or associated with ankle fracture. When syndesmotic injuries are associated with ankle fracture, they will most commonly occur with Weber C type ankle fractures (3,4). Residual widening of the ankle syndesmosis decreases the talocrural contact

area, leading to chronic ankle instability and post-traumatic ankle osteoarthritis (5,6). To prevent tibiofibular diastasis, the standard treatment for an unstable syndesmotic injury involves surgical reduction and stabilization (tibiofibular transfixation). However, no general consensus has been reached for the technique of syndesmotic repair (7,8).

The lack of standardization could in part have stemmed from a lack of information regarding other complications, such as iatrogenic compromise to the local vascular structures. In the case of syndesmotic injuries, the perforating branch of the peroneal artery is susceptible to injury. The distal tibiofibular syndesmosis is composed of 4 ligaments: the distal anterior tibiofibular ligament, distal posterior tibiofibular ligament, distal transverse tibiofibular ligament, and interosseous tibiofibular ligament. In a biomechanical study, Ogilvie-Harris et al (9) showed that the distal anterior tibiofibular ligament

**Financial Disclosure:** None reported.**Conflict of Interest:** None reported.

Address correspondence to: Keith Penner, DPM, HealthCare Partners Affiliate Medical Group, Department of Podiatric Medicine, Surgery, and Biomechanics, Western University of Health Sciences College of Podiatric Medicine, 19066 Magnolia Avenue, Huntington Beach, CA 92646.

E-mail address: [kpenner@healthcarepartners.com](mailto:kpenner@healthcarepartners.com) (K. Penner).

was responsible for 35% of the stability of the ankle joint, the deep portion of the distal posterior tibiofibular ligament for 33%, the interosseous tibiofibular ligament for 22%, and the distal posterior tibiofibular ligament for 9%.

The blood supply to the anterior portion of the syndesmotic ligaments derives from the perforating branch of the peroneal artery (PBPA) in most human specimens (10). Pai (11) described a traumatic aneurysm of the PBPA that he attributed to drilling for screw placement during ankle fracture repair. Fanter et al (12) evaluated the risk of PBPA injury when placing a single 4.5-mm trans-syndesmotic cortical screw 2 cm proximal to the tibiotalar articulation and concluded that an inherent risk of injury to the PBPA exists owing to the proximity of the screw to the artery on insertion of the fixation. However, because the number, size, and placement of screw fixation varies greatly and is dependent on many factors, such as the extent of the syndesmotic injury and surgeon preference, we sought to evaluate the risk associated with placement of 2 trans-syndesmotic screws in a cadaver model. We hypothesized that insertion of 2 screws would increase the potential for a PBPA injury compared with placement of a single screw.

### Materials and Methods

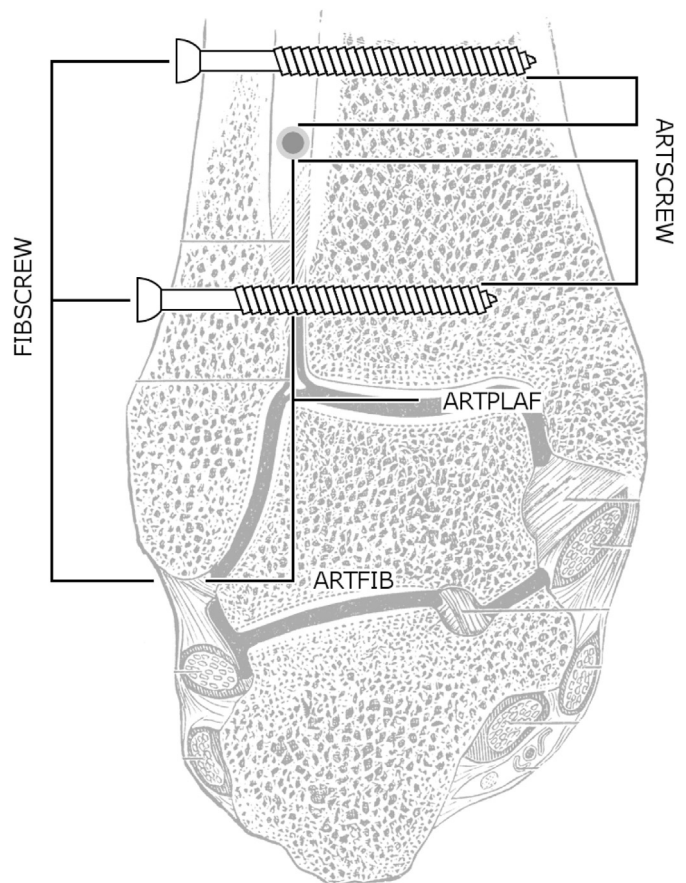
The Western University of Health Sciences institutional review board approved the present study. A total of 37 embalmed cadaveric lower extremities intact to the level of the hip joint were evaluated. The specimens were dissected using an anterior lateral approach, preserving the tendon and ligamentous structures. The dissections were conducted by 1 of us (K.P.). The anterior ankle was exposed by reflecting the extensor digitorum longus tendon medially and creating an anterolateral capsulotomy of the tibiotalar joint, after which the ankle joint and fibula were exposed, and marks were made on the lateral aspect of the fibula 2 and 4 cm proximal to the tibial plafond to identify the screw placement sites. The screw placed 2 cm proximal to the ankle joint was similar to the method used by Fanter et al (12) and based on the premise that syndesmotic screw placement 2 cm proximal to the tibiotalar joint would be a biomechanically reasonable position (12–14). Next, two 4.5-mm diameter  $\times$  45-mm long, fully threaded, self-tapping cortical screws were placed across the syndesmosis in all 37 specimens. The screws were inserted at the points marked on the fibula parallel to the tibiotalar joint in the coronal plane, oriented obliquely at 30° from posterolaterally to anteromedially, with the goal of bisecting the tibial incisura and crossing 3 cortices (lateral and medial fibular and lateral tibia). One of us (K.P.) inserted all the screws. Next, another of us (M.W.) dissected the vasculature around the ankle and then assessed the relationships of the PBPA to the screws and the anatomic landmarks using digital calipers (Absolute 500-196-20 Digital Caliper, Mitutoyo America, Chicago, IL), which has a stated accuracy of  $\pm 0.025$  mm.

These measurements were made in accordance with the protocols described by Fanter et al (12) as follows:

1. The minimum distance from the wall of the PBPA where it perforates the interosseous membrane to the threads along the shaft of each screw measured parallel to the shaft of the fibula in the sagittal plane
2. The distance from the distal tip of the lateral malleolus to the center of the head of each screw measured parallel to the fibular shaft in the sagittal plane
3. The distance from the distal wall of the PBPA where it perforates the interosseous membrane to the anterolateral tibial plafond measured parallel to the shaft of the fibula in the sagittal plane
4. The distance from the distal wall of the PBPA where it perforates the interosseous membrane to the tip of the lateral malleolus (ArtFib) measured parallel to the fibular shaft in the sagittal plane

The tibial length was also measured from the tibial plateau to tibial plafond, serving as a proxy for body size in the regression analyses (12) (Fig. 1 [15]). The anthropologic and forensic data have relied on the tibial length as a measure for body size, because it has had one of the lowest standard of error rates across all demographics, the irrelevance of limb asymmetry, and the stronger correlation between body size and lower limb measurement compared with measurements involving the upper extremity (16–19).

Statistical analyses were performed using the Statistical Package for Social Sciences, version 10.0 (SPSS, Chicago, IL), software package in a similar manner to the analysis performed by Fanter et al (12). Descriptive statistical analyses were performed with independent samples testing (unpaired Student's *t* tests) for both male and female specimens. Statistical significance was defined at the 5% ( $p \leq .05$ ) level. Pearson's correlations were calculated by performing a regression analysis to assess the strength of the clinically important relationships among the length of the tibia, screw placement, and arterial injury.



**Fig. 1.** Measurements of screw fixation and anatomic landmarks in relation to the perforating branch of the peroneal artery. ARTPLAF, distance from the distal wall of the perforating branch of the peroneal artery (PBPA) at the perforation of the interosseous membrane to the anterolateral tibial plafond; ARTFIB, distance from the distal wall of the PBPA at the perforation of the interosseous membrane to the distal tip of the lateral malleolus; ARTSCREW, distance from the distal wall of the PBPA at the perforation of the interosseous membrane to the threads along the shaft of the screw; FIBSCREW, distance from the distal tip of the lateral malleolus to the center of the screw head. (Modified from Gray H. Gray's Anatomy: Descriptive and Applied, ed 19, Lea & Febiger, Philadelphia, 1913, p. 1407, plate 343)

### Results

The anatomic data were assessed in all 37 limbs, with 20 limbs (54.05%) from 11 male cadavers and 17 (45.95%) from 10 female cadavers. Also, 19 (51.35%) were left limbs and 18 (48.65%) were right limbs (Table 1). The PBPA was situated at a mean distance of  $3.42 \pm .6$  cm from the tibial plafond to the point where it perforated the interosseous membrane. The male and female cadavers displayed a mean distance of  $3.64 \pm 0.5$  cm and  $3.15 \pm 1.0$  cm, respectively. The PBPA was within 4 mm of the superior screw in 19 cadavers (51.35%) and within 5 mm of the superior screw in 24 cadavers (64.86%). The prevalence of the superior screw being within 4 mm of the PBPA was 41.18% (7 of 17 cadaver limbs) in the female specimens and 60% (12 of 20 cadaver limbs) in the male specimens. The PBPA was within 4 mm of the inferior screw in 4 (10.81%) of the 37 limbs. In 3 (8.11%), the PBPA was observed to be in direct contact with the superior screw, 1 (2.7%) of which displayed the superior screw directly penetrating the artery (Fig. 2).

Independent samples tests of the null hypothesis were performed to compare the differences in the results between the male and female specimens (Table 1). A statistically significant difference was identified for the distance from the PBPA to the distal tip of the

**Table 1**  
Baseline characteristics and anatomic measurements

	Age (yr)	Tibial Length (mm)	ArtPlaf (mm)	ArtFib (mm)	ArtScrew (mm)		FibScrew (mm)	
					4 cm (proximal)	2 cm (distal)	4 cm (proximal)	2 cm (distal)
Combined (N = 37)								
Minimum	22.6	320	18.41	39.68	0	0	52.45	31.07
Maximum	97.1	398	67.96	88.97	19.36	35.65	72.32	51.02
Mean	71.6	357.71	34.15	54.32	4.97	11.92	60.75	41.56
SD	18.1	21.77	5.6	5.65	6.5	7.26	5.22	4.56
Male (n = 20)								
Minimum	22.6	343	26.54	47.67	0.00	0.00	52.96	34.51
Maximum	92.3	392	45.71	67.19	17.70	22.03	72.32	51.02
Mean	69.6	365.5	36.42	58.00	3.92	13.50	62.04	42.44
SD	19.8	17.75	4.97	4.80	5.69	6.60	5.28	4.19
Female (n = 17)								
Minimum	41.6	320	18.41	39.68	0.00	0.00	52.45	31.07
Maximum	97.1	377	67.96	88.97	19.36	35.65	69.63	50.87
Mean	69.6	344.25	31.53	52.74	6.20	10.05	59.21	40.52
SD	16.3	14.86	10.16	10.00	5.53	7.87	4.82	4.88
p Value*			.06	.04†	.22	.15	.10	.21

Abbreviations: ArtFib, distance from the distal wall of the PBPA at the perforation of the interosseous membrane to the distal tip of the lateral malleolus; ArtPlaf, distance from the distal wall of the PBPA at the perforation of the interosseous membrane to the anterolateral tibial plafond; ArtScrew, distance from the distal wall of the PBPA at the perforation of the interosseous membrane to the threads along the shaft of the screw; FibScrew, distance from the distal tip of the lateral malleolus to the center of the screw head; PBPA, perforating branch of the peroneal artery; SD, standard deviation.

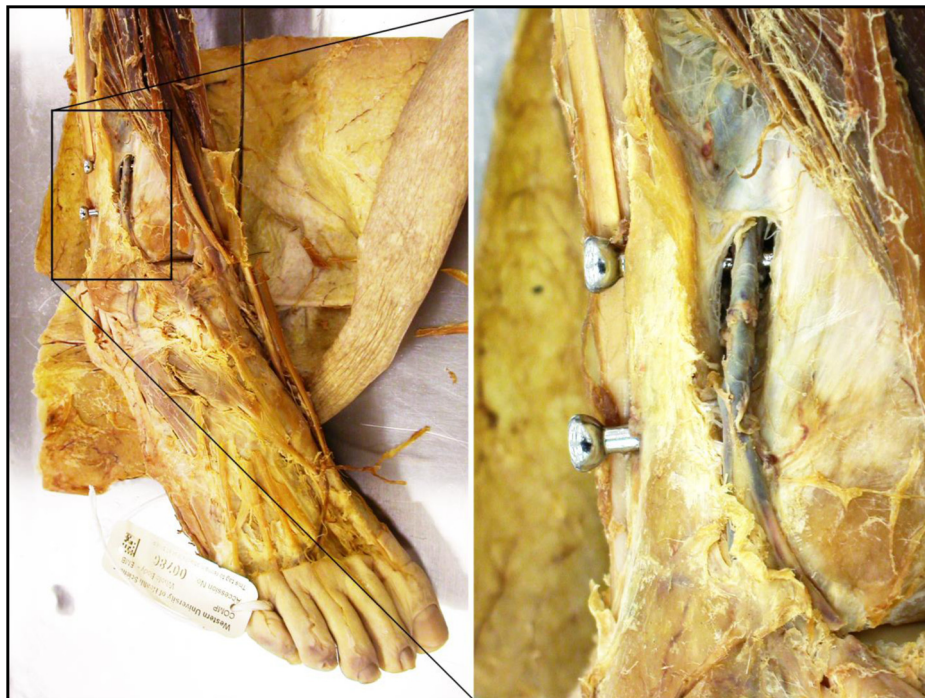\* Unpaired *t* test male versus female.

† Clinical significance defined at  $p \leq .05$ .

lateral malleolus (58.00 mm for males versus 52.74 mm for females;  $p = .04$ ). Also, a clinically significant ( $>10\%$ ) difference was found for the distance from the PBPA to the tibial plafond; however, the difference was not statistically significant (36.42 versus 31.53 mm;  $p = .06$ ).

Using the tibial length, ordinary least-squares regression analyses were performed to assess the relationship between physical stature and the PBPA anatomic measurements. When evaluating the data for the combined male and female limbs, a moderate negative correlation was found between the tibial length and the distance of the artery from the more superior screw ( $r = -0.440$ ,  $p = .007$ ). This result suggested that the greater the tibial length, the smaller the distance

from the superior screw to the PBPA. No other correlations involving tibial length were statistically significant in the combined data from all specimens (Table 2). In the male specimens, a moderate positive correlation was found between the tibial length and the distance of the artery from the inferior screw ( $r = 0.509$ ,  $p = .02$ ). This result suggested that, among the male limbs, the greater the tibial length, the larger the distance from the inferior screw to the PBPA. Similar to the combined male and female data analysis, a moderate negative correlation was found between the tibial length and the proximity of the artery to the superior screw in the male specimens ( $r = -0.465$ ,  $p = .04$ ). No statistically significant relationships were found in the separate evaluation of the female limbs (Table 3).



**Fig. 2.** Trans-syndesmotic screw fixation using 2 screws, with the superior screw penetrating the perforating branch of the peroneal artery.



**Table 2**  
Pearson correlations showing relationship between tibial length and anatomic and trans-syndesmotom screw fixation measurements (N = 37)

	ArtPlaf	ArtFib	ArtScrew		FibScrew	
			4 cm (proximal)	2 cm (distal)	4 cm (proximal)	2 cm (distal)
Combined (N = 37)						
Correlation (r)	0.169	0.144	-0.440	0.275	-0.010	-0.079
p Value combined	.32	.40	.007*	.10	.95	.65
Male (n = 20)						
Correlation (r)	0.358	0.293	-0.465	0.509	-0.282	-0.357
p Value male	.12	.21	.04*	.02*	.23	.12
Female (n = 17)						
Correlation (r)	-0.297	-0.382	-0.348	-0.292	-0.120	-0.176
p Value female	.25	.13	.17	.26	.65	.50

Abbreviations: ArtFib, distance from the distal wall of the PBPA at the perforation of the interosseous membrane to the distal tip of the lateral malleolus; ArtPlaf, distance from the distal wall of the PBPA at the perforation of the interosseous membrane to the anterolateral tibial plafond; ArtScrew, distance from the distal wall of the PBPA at the perforation of the interosseous membrane to the threads along the shaft of the screw; FibScrew, distance from the distal tip of the lateral malleolus to the center of the screw head; PBPA, perforating branch of the peroneal artery; SD, standard deviation.

\* Clinical significance defined at  $p \leq .05$ .

## Discussion

The precise location of the PBPA is highly variable, making the artery susceptible to vascular embarrassment during syndesmotom screw fixation. Initially, the PBPA branches from the peroneal artery deep in the posterior compartment of the leg and passes anteriorly through a hiatus in the interosseous membrane approximately 3 cm proximal to the ankle joint (10). Similar to these findings, our study showed the mean distance to be  $3.42 \pm 0.6$  cm proximal to the ankle joint. No significant difference was found when comparing the male and female cohorts in our study (12). The mean distance of the PBPA from the tibial plafond was less than 4.0 cm for all cohorts reported in published studies and in the specimens described in our study. This distance, therefore, can serve as a guideline for surgeons transfixating the tibiofibular syndesmosis with screws, because it defines a safe zone for screw placement. Specifically, screw placement situated more than 4 cm superior to the ankle joint will be unlikely to encounter the PBPA and, as such, will be unlikely to damage the vessel. The only statistically significant difference we observed between the male and female limbs was in the ArtFib, a value that was greater (more superiorly located) in the male specimens ( $p = .04$ ).

After passing through the interosseous membrane, the PBPA branches to provide the vascular supply to the anterior syndesmosis and travels distally, forming an anastomosis with 1 or more branches of the anterior tibial artery. At about the level of the tibial plafond, another lateral branch of the anterior tibial artery joins the PBPA, giving rise to the lateral malleolar artery (9). The variability of the branches of the PBPA can best illustrate its complexity. Beveridge et al (7) reported the 4 variable branches to be (1) a cutaneous branch to the lower leg, which is often reciprocal in size with the cutaneous branch of the lateral malleolar artery; (2) anterior and posterior lateral malleolar branches; (3) a small medial branch to the artery of the tarsal sinus; and (4) terminal branches that can anastomose with the posterior peroneal artery, lateral plantar arch, and lateral tarsal artery. It has also been reported that the PBPA usually contributes to the arterial plexus in the tarsal sinus but is typically not a significant source of blood supply. The role was only significant in 13% of the cases, when the artery of the tarsal sinus was a direct branch of the

PBPA (20). The lateral tarsal artery will be formed as a continuation of the PBPA in only 0.5% of cases (21).

The PBPA has particular clinical significance when the dorsalis pedis artery has derived from it instead of as the more common distal continuation of the anterior tibial artery. This occurrence has been reported in 3% and 6% of cases in 2 studies, with 1 patient in each study having a bilateral presentation (20,22). The geographic distribution and ethnic variability have been shown to influence these findings (11,23,24). In the present investigation, a single male cadaver also had the dorsalis pedis deriving from the PBPA bilaterally. This was the same cadaver in which the 4-cm screw on the right limb perforated the PBPA. This showed that although a dorsalis pedis derived from the PBPA is uncommon, it could be of particular surgical significance. In such cases, the PBPA will likely be larger to accommodate the increased vascular requirements of the dorsalis pedis artery distally. This could increase the risk of vascular injury, including perforation, during screw fixation.

To further highlight the complexity of the PBPA, it is important to recognize that, albeit rare, the PBPA could be absent. In these rare cases, the lateral branch of the anterior tibial artery will have replaced the PBPA (25). Mulfinger and Trueta (20) reported the absence of the PBPA in 3 (10%) of 30 specimens, but no other investigators have reported such a high incidence; thus, this could have been a peculiarity of the donor population or an effect of the small sample size. However, in more than 200 specimens between 2 studies, neither Huber (21) nor Beveridge et al (7) identified any limbs in which the PBPA was absent. Likewise, our study did not encounter an absent PBPA in 37 limbs.

Surgical repair of the syndesmosis with a single 4.5-mm cortical trans-syndesmotom screw inserted 2 cm proximal to the tibiotalar joint revealed a mean distance from the PBPA to the screw of  $1.30 \pm 0.59$  cm in males and  $0.85 \pm 0.53$  cm in females (12). The inferior screw placement in our study had a slightly greater mean distance from the PBPA at  $1.35 \pm 0.7$  cm for male cadavers, with a greater difference in the mean distance in the female cohort. The superior screw had a mean distance much less than that of the inferior screw and actually resulted in vascular embarrassment in 8.1% of the limb specimens. Additionally, the inferior screw was within 4 mm of

**Table 3**  
Screw fixation proximity to the perforating branch of the peroneal artery (N = 37)

Screw Location	Screw Proximity to Artery (mm)										
	0	1	2	3	4	5	6	7	8	9	10
Proximal screw (n)	10 (27)	13 (35)	15 (41)	17 (46)	19 (51)	24 (65)	27 (73)	29 (78)	30 (81)	31 (84)	32 (86)
Distal screw (n)	2 (5.4)	2 (5.4)	2 (5.4)	4 (10.8)	4 (10.8)	4 (10.8)	5 (14)	6 (16)	11 (30)	14 (38)	18 (49)

Data in parentheses are percentages.

the PBPA in 10.8% of specimens and the superior screw was within 4 mm of the PBPA in 51.4% of the cadavers. As the distance between the screw and the PBPA increased, the number of specimens showing a proximity that would place the artery at risk continued to increase (Table 3). Compared with the results from the study by Fanter et al (12) showing a distance of 1.0 cm or less in 6 (37.5%) of 16 limbs for the inferior screw, our study found that 49% of the limbs had a distance of 1.0 cm or less from the PBPA.

When evaluating the proximity of the screw fixation to the PBPA, our results showed that in 49% of cadavers for the inferior screw and 86% for the superior screw, the distance was 1.0 cm or less. In our study, the odds of the inferior screw being 1 cm or less from the PBPA was 1.3 and that for the superior screw was 2.3. This increased likelihood of the superior screw being closer to the PBPA demonstrated the increased risk of PBPA injury when inserting a more proximal screw 4 cm proximal to the ankle joint. Additionally, when using 2 syndesmotom screws, the odds of either screw being within 1.0 cm of the PBPA was 1.8 compared with the 1-screw technique studied by Fanter et al (12).

Using the femoral bi-epicondylar width as a proxy for body size, Fanter et al (12) found a significant relationship between body size and the anatomic measurements for the distance from the distal wall of the PBPA where it perforates the interosseous membrane to the anterolateral tibial plafond and ArtFib. As a result of the small sample size, no statistically significant size relationships were observed when evaluating the same gender samples. Our analysis was based on the tibial length as a proxy for the body size. Regression analysis of all samples found a statistically significant negative correlation between the tibial length and the anatomic measurement of the minimum distance from the wall of the PBPA where it perforates the interosseous membrane to the threads along the shaft of each screw of 4 cm ( $p = .007$ ). This result suggested that the larger the body size, the nearer the PBPA will be to the superior screw location. Dividing the data into same-gender samples revealed statistically significant correlations among the male specimens for the proximal and distal screws both. The relationships were such that the larger the tibial length among the male specimens, the further the PBPA can be expected from the more inferior screw, but the closer it would be to the superior screw (Table 2).

Although our study followed the methods used by Fanter et al (12) to assess a commonly used alternative approach of 2 screws to fixate an ankle syndesmotom injury, we recognize that our study had limitations. One such deficiency was appreciated in the measurement of the distance from the PBPA to the screw. The superoinferior absolute distance was measured, but the anteroposterior absolute distance from the artery to the screw was not measured. This led to several instances in which a 0 measurement was recorded but rather than penetrate the artery, the screw, in fact, was located either directly anterior or posterior to it, potentially overestimating the risk of injury. Another limitation was related to the sample size. Despite the consistency between general anatomic measurements regarding the PBPA location, the significant variability and complexity of the arterial patterns could require a larger sample than the 37 specimens used in the present study. This also created some limitations when comparing our results with those from the study by Fanter et al (12) owing to the even smaller population size used in their study and the known biases related to the use of historical controls. Finally, the diameter of the PBPA was not measured. At the closest point of the PBPA to the superior or inferior screw, the PBPA diameter could be a factor in the risk of injury.

In conclusion, trans-syndesmotom screw placement places the patient at risk of vascular embarrassment. We have identified an increased risk with a screw located 4 cm superior to the ankle joint compared with a more inferior screw located 2 cm proximal to the ankle joint and when using 2 screws compared with 1 screw. This was also supported by the positive correlation, showing the longer the tibia, the closer the artery is located to the superior screw placement and, in male subjects, the further the artery from the inferior screw placement. Ultimately, the more superior the screw placement and the larger the tibia, the more likely a PBPA injury can occur owing to trans-syndesmotom screw fixation. It is important to recognize the parameters for the likely position of the PBPA to prevent these injuries and still maximize the proper reduction of the syndesmosis.

## References

1. Court-Brown CM, McBurnie J, Wilson G. Adult ankle fractures—an increasing problem? *Acta Orthop Scand* 69:43–47, 1998.
2. Lindsjö U. Operative treatment of ankle fractures. *Acta Orthop Scand Suppl* 189:1–131, 1981.
3. Kennedy JG, Johnson SM, Collins AL, DalloVedova P, Hynes DM, Walsh MG, Stephens MM. An evaluation of the Weber classification of ankle fracture. *Injury* 29:577–580, 1998.
4. Petrone FA, Gail M, Pee D, Fitzpatrick T, Van Herpe LB. Quantitative criteria for prediction of the results after displaced fracture of the ankle. *J Bone Joint Surg Am* 65:667–677, 1983.
5. Miller AN, Carroll EA, Parker RJ, Boraiah S, Helfet DL, Lorich DG. Direct visualization for syndesmotom stabilization of ankle fractures. *Foot Ankle Int* 30:419–426, 2009.
6. Mosheiff R, Liebergall M, Margulies JY, Peyser A, London E, Segal D. Technical complications of the tibiofibular syndesmotom screw. *J Foot Ankle Surg* 32:462–466, 1993.
7. Beveridge J, Masquelet AC, Romana MC, Vinh TS. Anatomic basis of a fasciocutaneous flap supplied by the perforating branch of the peroneal artery. *Surg Radiol Anat* 10:195–199, 1988.
8. van den Bekerom MP, Hogervorst M, Bolhuis HW, van Dijk CN. Operative aspects of the syndesmotom screw: review of current concepts. *Injury* 39:491–498, 2008.
9. Ogilvie-Harris DJ, Reed SC, Hedman TP. Disruption of the ankle syndesmosis: biomechanical study of the ligamentous restraints. *Arthroscopy* 10:558–660, 1994.
10. McKeon KE, Wright RW, Johnson JE, McCormick JJ, Klein SE. Vascular anatomy of the tibiofibular syndesmosis. *J Bone Joint Surg Am* 94:931–938, 2012.
11. Pai VS. Traumatic aneurysm of the perforating peroneal artery following an ankle fracture. *J Foot Ankle Surg* 38:417–419, 1999.
12. Fanter NJ, Inouye SE, McBryde AM Jr. Safety of trans-syndesmotom fixation. *Foot Ankle Int* 31:433–440, 2010.
13. McBryde A, Chiasson B, Wilhelm A, Donovan F, Ray T, Bacilla P. Syndesmotom screw placement: a biomechanical analysis. *Foot Ankle Int* 18:262–266, 1997.
14. Boden SD, Labropoulos PA, McCowin P, Lestini WF, Hurwitz SR. Mechanical considerations for the syndesmotom screw: a cadaver study. *J Bone Joint Surg Am* 71:1548–1555, 1989.
15. Gray H. *Gray's Anatomy: Descriptive and Applied*, ed 19, Lea & Febiger, Philadelphia, 1913, p. 1407.
16. Trotter M. Estimation of stature from intact long limb bones. In: *Personal Identification in Mass Disasters*, pp. 71–83, edited by TD Steward, National Museum of Natural History, Smithsonian Institution, Washington, DC, 1970.
17. Jantz RL. Modification of the Trotter and Gleser female stature estimation formulae. *J Forensic Sci* 37:1230–1235, 1992.
18. Jantz RL, Hunt DR, Meadows L. The measure and mismeasure of the tibia: implications for stature estimation. *J Forensic Sci* 40:758–761, 1995.
19. Byers SN. *Introduction to Forensic Anthropology*, ed 2, Pearson Education, Boston, 2005, pp. 260–263.
20. Mulfinger GL, Trueta J. The blood supply of the talus. *J Bone Joint Surg Br* 52:160–167, 1970.
21. Huber JF. The arterial network supplying the dorsum of the foot. *Anat Rec* 80:373–391, 1941.
22. Keen JA. A study of the arterial variations in the limbs, with special reference to symmetry of vascular patterns. *Am J Anat* 108:245–261, 2005.
23. Yamada T, Glociczki P, Bower TC, Naessens JM, Carmichael SW. Variations of the arterial anatomy of the foot. *Am J Surg* 166:130–135, 1993.
24. Adachi B. *Anatomie der Japaner 1: Das Arteriensystem der Japaner [Anatomy of the Japanese 1: The Arterial System of the Japanese]*, Kaiserlich-Japanischen Universität zu Kyoto, Kyoto, Japan, 1928.
25. Edwards EA. Anatomy of the small arteries of the foot and toes. *Cells Tissues Organs* 41:81–96, 1960.