




Contents lists available at ScienceDirect

The Journal of Foot & Ankle Surgery

journal homepage: www.jfas.org

Case Reports and Series

Cutaneous Branch of the Obturator Nerve Extending to the Medial Ankle and Foot: A Report of Two Cadaveric Cases

Brittany Staples, DPM^{1,2}, Edward Ennedy, DO^{3,4}, Tae Kim, DO³, Steven Nguyen, DO^{3,5}, Andrew Shore, DO^{3,6}, Thomas Vu, DO^{3,7}, Jonathan Labovitz, DPM, FACFAS⁸, Mathew Wedel, PhD⁹¹ Student, Western University of Health Sciences College of Podiatric Medicine, Pomona, CA² Chief Surgical Resident, SSM Health DePaul Hospital, St. Louis, MO³ Student, Western University of Health Sciences College of Osteopathic Medicine of the Pacific, Pomona, CA⁴ Resident, Medical City Forth Worth and University of North Texas Health Science Center, Fort Worth, TX⁵ Resident, Einstein Healthcare Network, Philadelphia, PA⁶ Resident, University of Missouri School of Medicine, Kansas City, MO⁷ Resident, Mercy Health, Muskegon, MI⁸ Professor, Department of Podiatric Medicine, Surgery, and Biomechanics, and Associate Dean of Clinical Education and Graduate Placement, Western University of Health Sciences College of Podiatric Medicine, Pomona, CA⁹ Associate Professor, Department of Anatomy, Western University of Health Sciences College of Osteopathic Medicine of the Pacific and College of Podiatric Medicine, Pomona, CA

ARTICLE INFO

Level of Clinical Evidence: 4

Key Words:

anatomic variant
cutaneous nerve
dermatome
great saphenous vein
medial malleolus
obturator nerve
saphenous nerve

ABSTRACT

The area of skin supplied by the cutaneous branch of the obturator nerve (CBO) is highly variable. Although most introductory anatomy texts describe the CBO as innervating only a portion of the medial thigh, there are numerous reports in the literature of CBOs passing the knee to innervate the proximal, middle, or even distal leg. There are no previous reports of CBOs extending to the ankle and foot. Herein we describe 2 cases of CBOs extending at least to the medial foot. Both cases were discovered incidentally, during routine cadaver dissections by osteopathic and podiatric medical students in the anatomy laboratory of Western University of Health Sciences in California. In both instances, the anomalously long CBOs shared several characteristics: (1) they arose as direct branches of the anterior division of the obturator nerve, not from the subsartorial plexus; (2) they coursed immediately posterior to the great saphenous vein from the distal thigh to the distal leg, only deviating away from the saphenous vein just above the medial malleolus; and (3) they terminated in radiating fibers to the posterior half of the medial ankle and foot. In both cases, the saphenous branch of the femoral nerve was present but restricted to the area anterior to the great saphenous vein. It is likely that the variant CBOs carried fibers of the L4 spinal nerve and thus provided cutaneous innervation to the medial foot and ankle, a function most commonly reserved for the saphenous branch of the femoral nerve distal to the knee. Saphenous neuropathy is a common postoperative complication of saphenous cutdowns for coronary artery bypass grafts, so the potential involvement of a long CBO can add additional complexity to regional anesthetic blocks for foot and ankle surgery and procedures such as vein harvesting for coronary artery bypass grafts.

© 2019 by the American College of Foot and Ankle Surgeons. All rights reserved.

The cutaneous branch of the obturator nerve (CBO) is recognized in the literature to be highly variable, both in the region it supplies and in its connections, if any, to other nerves (1–4). Distal to the obturator canal, the obturator nerve separates into anterior and posterior divisions. The anterior division passes in front of both the obturator externus and adductor brevis muscles, supplies motor innervation to the

adductor longus and gracilis, and gives off the CBO. The posterior division passes behind or through the obturator externus, behind the adductor brevis, supplies motor innervation to the obturator externus and adductor longus, and sends a sensory branch to the hip joint. The adductor brevis is variably supplied by both the anterior and posterior divisions of the obturator nerve (1), and a sensory branch to the knee most commonly arises from the posterior division, but occasionally derives from the anterior division (5).

Sources vary as to the origin of the CBO. From the 20th edition (6) through the current 41st edition (7), *Gray's Anatomy* explicitly describes the CBO as a branch of the subsartorial plexus, formed by communicating branches of the obturator nerve to the medial cutaneous nerve of

Financial Disclosure: None reported.**Conflict of Interest:** None reported.

Address correspondence to: Brittany Staples, DPM, Western University of Health Sciences, College of Podiatric Medicine, 309 E. 2nd St, Pomona, CA 91766.

E-mail address: drbstaples@gmail.com (B. Staples).

the thigh and the saphenous nerve. Other authors described the CBO arising directly from the anterior division of the obturator nerve, in at least some cases, without any necessary involvement in the subsartorial plexus (1,4).

In most introductory anatomy texts, the CBO is described as supplying a relatively small area of skin over the medial and distal thigh (8–12). Primary sources and some more authoritative texts describe the CBO as occasionally supplying the popliteal fossa (13) and knee (4) or extending past the knee to the proximal half of the leg (2,3,6,7). Only Bardeen described the CBO extending past the midpoint of the leg (1: p. 285): “Out of 80 instances in which the nerves of the thigh were carefully charted, in 12, a large cutaneous branch passed from the obturator to the region of the knee and in 10 other instances one passed to or beyond the middle third of the crus.” In a later section, Bardeen described more specifically the courses of the CBOs in 2 cases: “In all instances extensive distribution of cutaneous branch: in one half way down back of leg, in another nearly to ankle” (1: p. 317).

There are no previous reports of the CBO reaching the medial ankle and foot. The purpose of this article is to describe 2 cases in which the CBO was traced as a distinct, separate structure from the anterior division of the obturator nerve, down the medial aspect of the lower extremity, and past the medial malleolus into the medial foot.

Case Report

Both of the following cases were discovered during routine cadaveric dissections in the gross anatomy lab at Western University of Health Sciences in Pomona, California, USA (WesternU). In both cases, the cadavers were donated through the University’s willed body program. After the conclusion of the relevant courses, the cadaveric remains were cremated, and the ashes were returned to the families. All dissections were performed by first-year osteopathic and podiatric medical students, using standard surgical dissection tools. This project was granted an expedited review and subsequently granted approval by the Western University of Health Sciences Institutional Review Board. High-resolution photographs of the 2 cases are available from the authors upon request.

The first case was identified during the Medical Gross Anatomy course at WesternU on October 2, 2013. The cadaver was that of a 70-year-old male, WesternU Cadaver Identification Number 890, who had died of glioblastoma. While skinning the left lower extremity, we noticed that the CBO extended past the knee (Fig. 1). The CBO in this case arose as a direct branch of the anterior division of the obturator nerve, not from the subsartorial plexus, emerging between the adductor longus and gracilis in the superior third of the thigh (Fig. 2A). Distally, the CBO traveled just posterior to the great saphenous vein, giving off small peripheral branches to the skin of the medial thigh, knee, and leg at regular intervals. About 5 cm superior to the medial malleolus, the CBO terminated in several branches that continued inferiorly, crossing over and immediately posterior to the medial malleolus before fanning out over the posterior half of the medial foot and ankle (Fig. 2B). The main trunk of the CBO and most of the side branches were distributed posterior to the great saphenous vein, whereas the saphenous branch of the femoral nerve coursed anterior to the great saphenous vein. We found no evidence of the CBO in the right lower extremity extending past the knee, thus making this finding asymmetrical in nature.

The second example was discovered during the Intensive Summer Anatomy Course at WesternU, on July 22, 2014. The cadaver was that of a 71-year-old male, WesternU Cadaver Identification Number 903, who had died of metastatic lung cancer. As in the previous case, while skinning the left lower extremity, we discovered that the CBO extended past the knee (Fig. 3). Above the distal leg, the 2014 example had essentially the same course and distribution as the previous case. The CBO arose as a direct branch of the anterior division of the obturator nerve

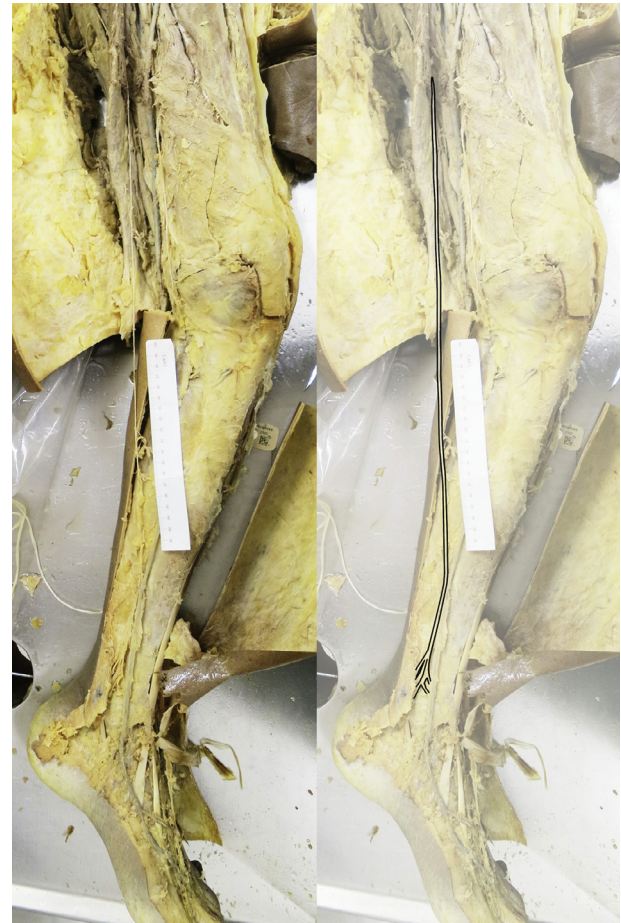


Fig. 1. A cutaneous branch of the obturator nerve extending to the medial foot and ankle in a 70-year-old male, discovered in the fall of 2013.

(Fig. 4), emerged between adductor longus and gracilis in the proximal thigh, and coursed posterior to the great saphenous vein from the distal thigh to the distal leg, giving off small side branches at regular intervals. As in the previous case, we found no evidence that the right CBO extended past the knee.

The 2014 example differed from the 2013 cases in 2 important respects. First, as the CBO passed the knee, it was threaded among branches of the saphenous nerve (Fig. 5), whereas no close relationship was observed in the 2013 dissection. Second, the main trunk of the CBO remained intact until the medial malleolus, at which point it terminated in a fan of small branches that were distributed both anterior and posterior to the malleolus. Within a few centimeters, the anterior branches curved inferiorly. At this point, the branches were extremely small (<1 mm) and almost impossible to trace, but they did not appear to reach any farther forward than the transverse tarsal joint. In both cases, both anatomic variants were ipsilateral and unilateral.

Discussion

In light of the report by Bardeen (1) of a CBO reaching “nearly to [the] ankle,” the 2 cases described here represent an incremental advance in the known distribution of the CBO. In other words, we found the CBO extending more distally than any previous report, but only by a few centimeters. Nevertheless, this demonstrates that the CBO can extend below the medial malleolus. This discovery brings the obturator nerve into the anatomic domain of the foot and ankle.

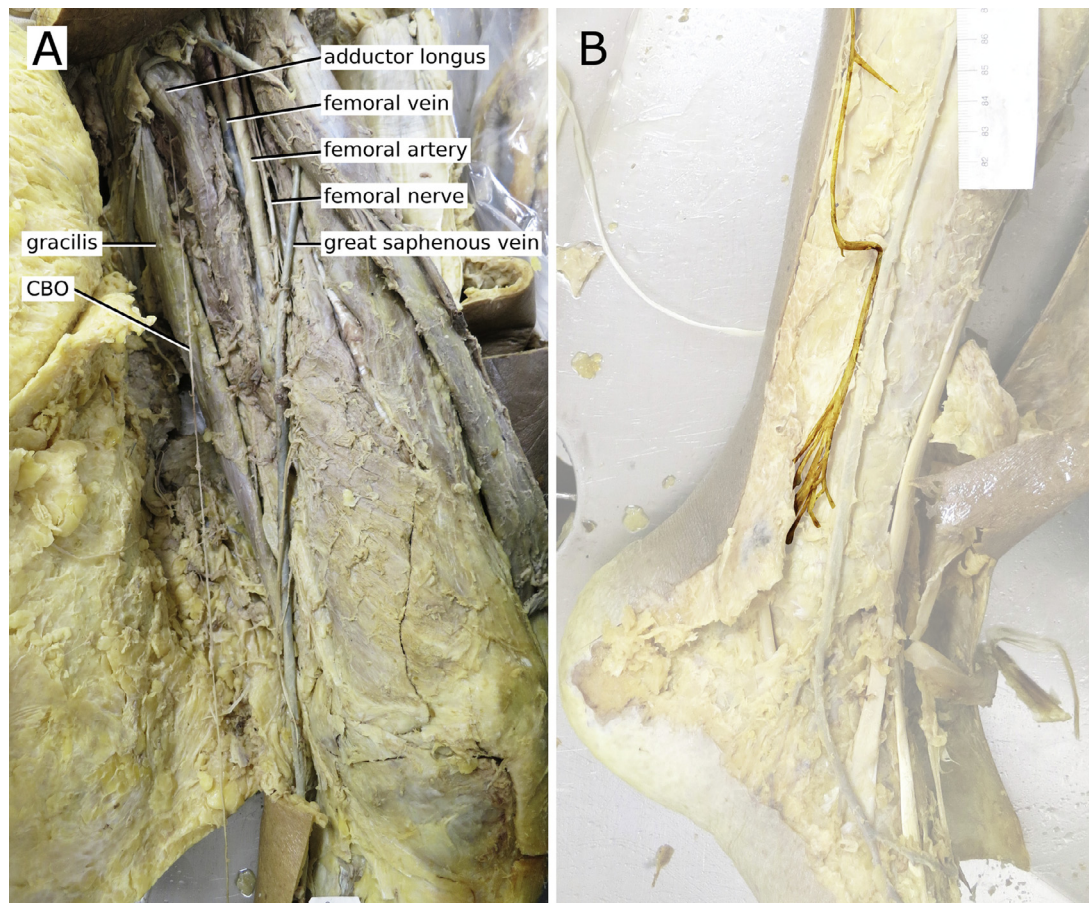


Fig. 2. The cutaneous branch of the obturator nerve (CBO) in the 2013 case. (A) The nerve emerging proximally from behind the adductor longus. (B) Terminal branches coursing over and posterior to the medial malleolus.

The discovery that the CBO can reach the ankle and medial foot raises 3 questions:

1. How common is this variant, and how did it escape detection before now?
2. How does this variation form developmentally?
3. What are the clinical implications, if any?

The 2013 example was discovered in 1 lower extremity of 1 individual, of 31 cadaveric specimens in the course (3.2% of individuals). The 2014 case was the only one we found in a sample of 14 cadaveric specimens in the smaller summer anatomy course (7.1%).

Frequency of occurrence and mode of discovery are related. It is likely that the 2014 example was spotted and documented because one of us (M.W.) was alerted to the possibility of anomalously long CBOs by the 2013 case, and had in turn alerted the students to be on the lookout for more examples. To some degree, observations are limited by expectations. This is a typical occurrence when one applies the method of processing information commonly known as heuristics. This method of decision making uses rules of thumb, which are often beneficial, but can also lead to error. One heuristic type is blind obedience, wherein we place undue reliance on expert opinion. Given that most entry-level anatomy texts do not report long CBOs as a possibility, we had no reason to suspect that the variant existed. However, as we identified in 2013, this variant does exist, and armed with that information, within 1 year we identified the variant a second time.

In every year since 2013, one of us (M.W.) has cautioned the medical and podiatric students at WesternU to be on the lookout for further

examples of anomalously long CBOs, but no more have come to light, of a cumulative cadaveric sample of 255 individuals as of this writing. So the frequency of the variant CBOs in cadaveric specimens that have specifically been examined for its presence is 2 of 255, or 0.78%. It seems that we were lucky in finding the variant twice in 2 years, either because it is genuinely rare, or because it is so delicate that it is almost impossible to recognize and preserve in dissection (which is consistent with the comments of Bardeen [1]).

We suspect that anomalously long CBOs like those documented here fall into a perceptual blind spot. Recognizing a long CBO minimally requires 2 things: first, that the CBO survive the process of skinning or surgical access, and second, that the connection of the CBO to the rest of the obturator nerve be traced. These factors are dependent on medical students and surgeons, the 2 groups most likely to encounter an anomalously long CBO. Medical students in gross anatomy labs typically skin the entire lower extremity, which gives them the opportunity to find a long CBO and trace its connection to the rest of the obturator nerve. However, cutaneous nerves are often accidentally cut during skinning, and even if they are not, their small size, variable courses, and complicated relationships with subcutaneous fascia make them difficult to trace. This is particularly true of the CBO, as recognized by Bardeen (1), who wrote (p. 285): “How constant the cutaneous branch of the obturator may be I have been unable satisfactorily to determine. Students dissecting frequently fail to find it. Owing to the fact that this may often be due to its small size the negative records cannot safely be used in making up statistics.” This means that medical students have the anatomic access necessary to discover long CBOs, but in many cases they may not yet have the skill required to preserve the nerve along its entire course.

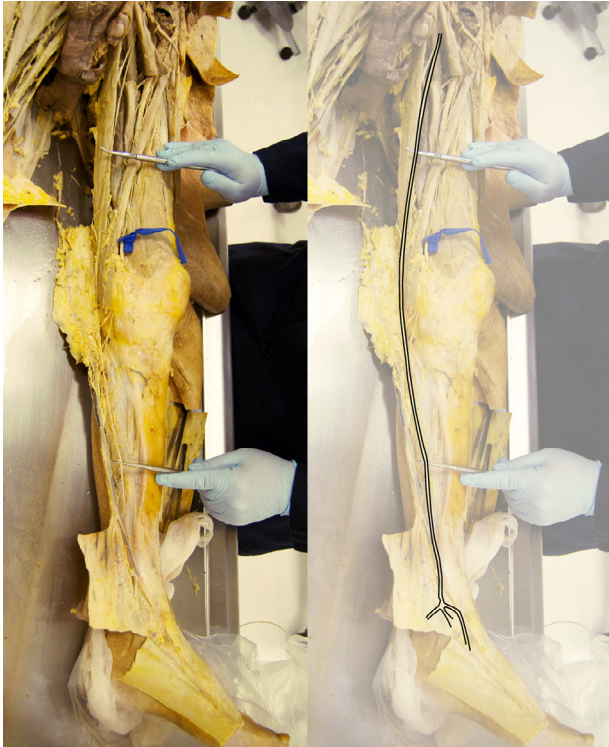

Fig. 3. A second case of an anomalously long cutaneous branch of the obturator nerve, this time in a 71-year-old male, discovered in the summer of 2014.

In contrast, surgeons have the skill to recognize and preserve the CBO, but few surgeons have the opportunity to identify the long CBO as a branch of the obturator nerve. Wilmot and Evans (14) found that in a

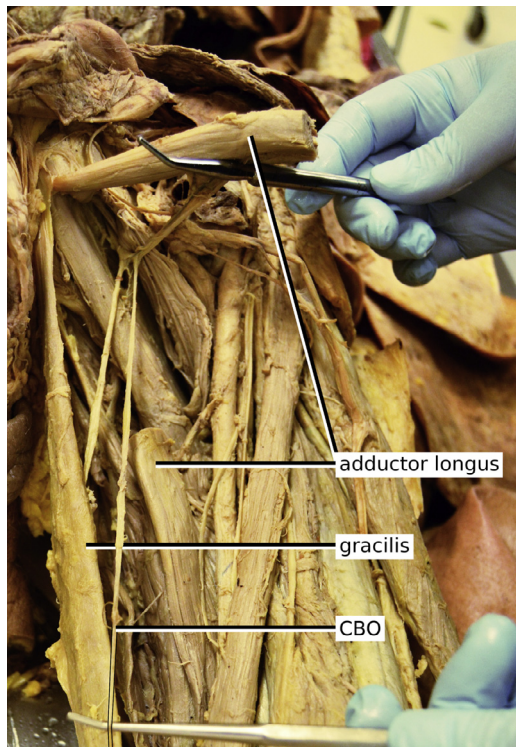


Fig. 4. Proximal origin of the cutaneous branch of the obturator nerve (CBO) in the 2014 case (adductor longus is cut and partially reflected here).

majority of cases, the saphenous nerve was split into 2 branches that coursed anteriorly and posteriorly to the great saphenous vein; a similar division of the saphenous nerve was described by Bardeen (1). In both of the cases described here, the long CBO was located immediately posterior to the great saphenous vein, and the saphenous nerve was located immediately anterior to the vein. Without tracing the nerves back to their proximal sources, it would be impossible to know if a nerve running just posterior to the great saphenous vein was in fact a branch of the saphenous nerve or a long CBO—and very few saphenous cutdowns run all the way from the mid thigh to the ankle. Therefore, the opposite situation holds true for surgeons: they have the skill to recognize long CBOs, but few opportunities to discover them.

Typically, the only nerve that runs with the great saphenous vein is the saphenous nerve, the terminal cutaneous branch of the femoral nerve (although Bardeen [1] noted that the medial cutaneous nerve of the thigh could occasionally send branches as far distally as the ankle). As described above, in most cases the saphenous nerve divides into anterior and posterior branches that run just in front of and behind the great saphenous vein (1,14). In both of the cases described here, the posterior branch of the saphenous nerve was absent, and its place was taken by the long CBO. So we can recognize that long CBOs, when they occur, represent a “replaced” posterior branch of the saphenous nerve, in which the nerve that runs posterior to the great saphenous vein forms as a branch of the obturator nerve instead of the femoral nerve (Fig. 6A, B).

Distal to the knee, the distribution of the saphenous nerve matches almost exactly the distribution of the L4 dermatome (Fig. 6C; also see figures 79.17 and 79.19 in 7, and 15). In most cases, the saphenous nerve could be said to embody the L4 dermatome past the knee. We hypothesize that a long CBO serves as a functional replacement for the posterior branch of the saphenous nerve, and therefore some L4 sensory fibers that would typically be part of the femoral nerve become incorporated into the obturator nerve instead.

Because of its course along the saphenous vein, obturator nerve variations can result in challenges to obtaining adequate regional anesthesia for lower-extremity surgery. When performing specific nerve blocks, knowledge of the potential for obturator nerve variants can aid in ensuring adequate anesthesia. Meanwhile, these variations are less relevant when performing an ankle block or other infiltrative nerve blocks, since the ring of anesthetic solution across all tissue planes impacts any nerves potentially innervating tissues in the operative field (16–18). However, this method requires more local anesthesia than specific nerve blocks and can lead to vasodilatation.

Additionally, variations of the obturator nerve could have clinical significance for coronary artery bypass graft (CABG) procedures. Although the use of arterial conduits in CABGs is increasing, the great saphenous vein is still commonly harvested. Complications including numbness, pain, and neuralgia at the donor site are common after harvesting of the saphenous vein for CABGs (19). In a postoperative survey study, Garland et al. (20) found that 61% of patients reported numbness or tingling related to the saphenous donor site wound, and 46% reported pain. After 2 years, 41% of patients still experienced paresthesia, and 10% reported ongoing pain.

In conclusion, as discussed above, numerous prior authors have described CBOs extending distal to the knee. Our descriptions of 2 instances of CBOs passing the medial malleolus appear to be the first, and they bring the obturator nerve into the realm of foot and ankle surgery. Even in cases where the CBO has been acknowledged to extend past the knee, detailed descriptions of its course have been lacking. Therefore, implications of long CBOs for regional anesthesia for foot and ankle surgery, and saphenous vein donor site morbidity, are unexplored. Our findings suggest that further study of the variation of the obturator nerve could help reduce accidental nerve damage secondary to venous harvesting. We hope that this report leads to further

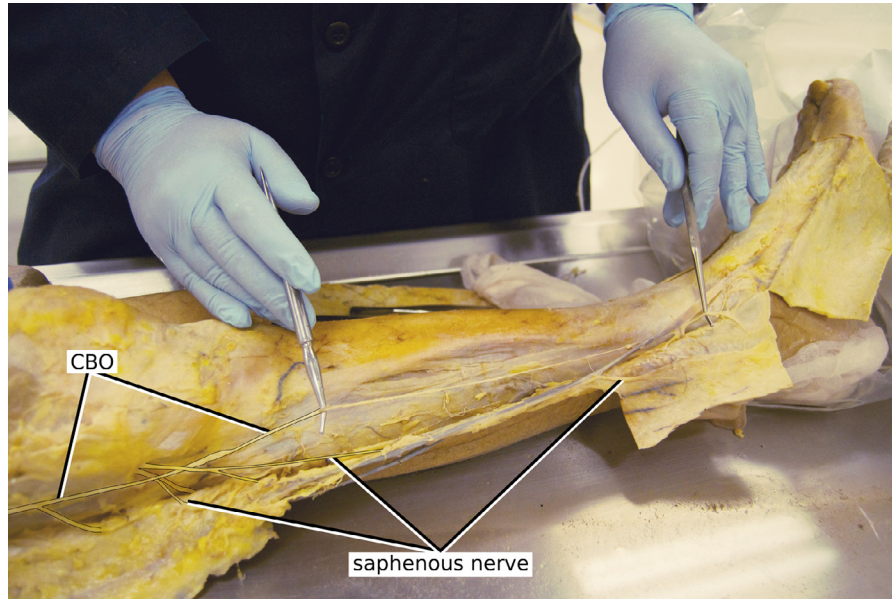


Fig. 5. The course of the cutaneous branch of the obturator nerve (CBO) in the leg in the 2014 case. Note that the skin has been reflected away from the distal leg, so the saphenous nerve appears to lie posterior to the great saphenous vein, when in fact it is anterior to the vein.

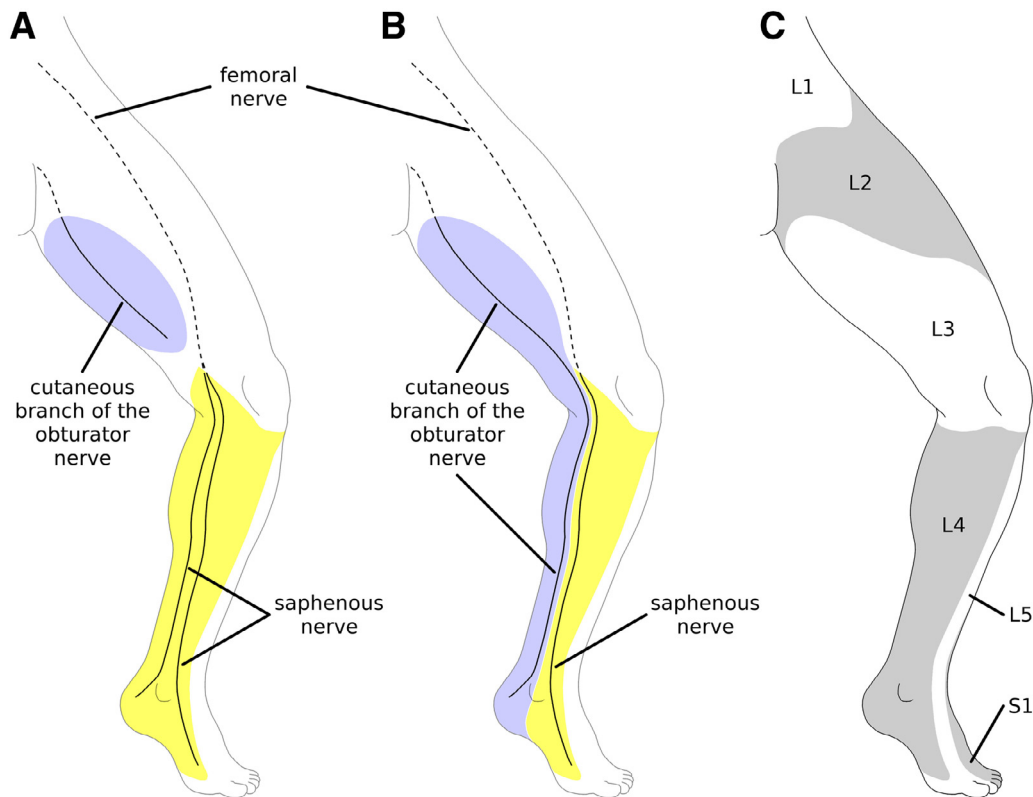


Fig. 6. The left lower extremity in anteromedial view, illustrating variations in cutaneous nerves and their relations to dermatomes. (A) The most common pattern, in which the cutaneous branch of the obturator nerve does not extend past the knee, and the skin over the anteromedial leg is innervated by branches of the saphenous nerve (see Wilmot and Evans [14] for other saphenous nerve variants). (B) The variant pattern identified in the 2013 and 2014 cases described herein, in which the posterior branch of the saphenous nerve was replaced by a long cutaneous branch of the obturator nerve. (C) Lower-extremity dermatomes, based on previously published data (7,15). Boundaries are approximate and variable, with considerable overlap. The L4 dermatome is typically innervated entirely by the saphenous nerve, but in some cases the cutaneous branch of the obturator nerve also contributes, as described by previous authors (1-3) and as shown in the cases described herein.

discoveries of long CBOs, and ultimately to improved knowledge of obturator nerve distribution in the leg and foot.

Acknowledgments

Janelle Green, DPM, Craig Kuehn, PhD, Kathleen Satterfield, DPM, Jarrod Shapiro, DPM, David Shofler, DPM, and Jacqueline Truong, DPM, read early drafts of this manuscript and provided helpful comments. We thank editor D.S. Malay and an anonymous reviewer for constructive suggestions that improved the quality of this paper.

References

1. Bardeen CR. Development and variation of the nerves and the musculature of the inferior extremity and of the neighboring regions of the trunk in man. *Dev Dyn* 1906;6:259–390.
2. Sunderland S. *Nerves and Nerve Injuries*. Churchill Livingstone, Edinburgh, 1968;992–998.
3. Rouvière H, Delmas A. *Anatomie Humaine, Descriptive, Topographique et Fonctionnelle: Tome 3—Membres-Système Nerveux Central*. pp 473–491, 11th ed, Masson, Paris, 1973.
4. Hirasawa Y, Okajima S, Ohta M, Tokioka T. Nerve distribution to the human knee joint: anatomical and immunohistochemical study. *Int Orthop* 2000;24:1–4.
5. Kennedy JC, Alexander JJ, Hayes KC. Nerve supply of the human knee and its functional importance. *Am J Sports Med* 1982;10:329–335.
6. Gray H, Lewis WH. *Anatomy of the Human Body*. pp 765–767, 20th ed, Lea & Febiger, Philadelphia, 1918.
7. Standring S, ed. *Gray's Anatomy: The Anatomical Basis of Clinical Practice*, p 1383, 41st ed, London: Elsevier Health Sciences, 2015.
8. Rohen JW, Yokochi C, Lutjen-Drecoll E. *Color Atlas of Anatomy: A Photographic Study of the Human Body*. Lippincott, Williams, and Wilkins, Philadelphia, 2006.
9. Drake RL, Vogl W, Mitchell AWM. *Gray's Anatomy for Students*. p 574, 2nd ed, Churchill Livingstone, London, 2009.
10. Moore KL, Dalley AF, Agur AM. *Clinically Oriented Anatomy*. 6th ed, Lippincott, Williams, and Wilkins, Philadelphia, 2010.
11. Agur AM, Dalley AF. *Grant's Atlas of Anatomy*. 13th ed, Lippincott, Williams, and Wilkins, Philadelphia, 2013.
12. Gilroy AM. *Anatomy: An Essential Textbook*. Thieme Medical Publishers, New York, 2013.
13. Bouaziz H, Vial F, Jochum D, Macalou D, Heck M, Meuret P, Braun M, Laxenaire MC. An evaluation of the cutaneous distribution after obturator nerve block. *Anesth Analg* 2002;94:445–449.
14. Wilmot VV, Evans DJR. Categorizing the distribution of the saphenous nerve in relation to the great saphenous vein. *Clin Anat* 2013;26:531–536.
15. Lee MWL, McPhee RW, Stringer MD. An evidence-based approach to human dermatomes. *Clin Anat* 2008;21:363–373.
16. Donohue CM, Goss LR, Metz S, Weingarten MS, Dyal LB Jr. Combined popliteal and saphenous nerve blocks at the knee: an underused alternative to general or spinal anesthesia for foot and ankle surgery. *J Am Podiatr Med Assoc* 2004;94:368–374.
17. Wang J, Liu GT, Mayo HG, Joshi GP. Pain management for elective foot and ankle surgery: a systematic review of randomized controlled trials. *J Foot Ankle Surg* 2015;54:625–635.
18. Fraser TW, Doty JF. Peripheral nerve blocks in foot and ankle surgery. *Orthop Clin* 2017;48:507–515.
19. Morrison C, Dalsing MC. Signs and symptoms of saphenous nerve injury after greater saphenous vein stripping: prevalence, severity, and relevance for modern practice. *J Vasc Surg* 2003;38:886–890.
20. Garland R, Frizelle FA, Dobbs BR, Singh H. A retrospective audit of long-term lower limb complications following leg vein harvesting for coronary artery bypass grafting. *Eur J Cardiothorac Surg* 2003;23:950–955.