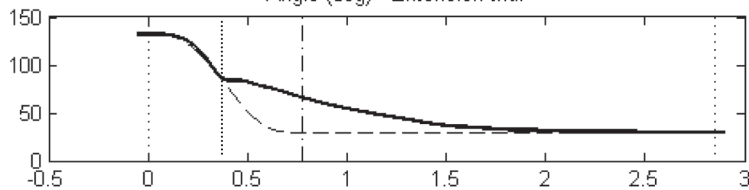
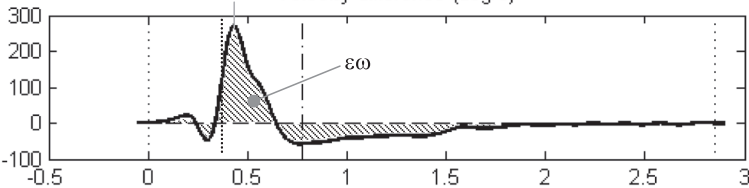
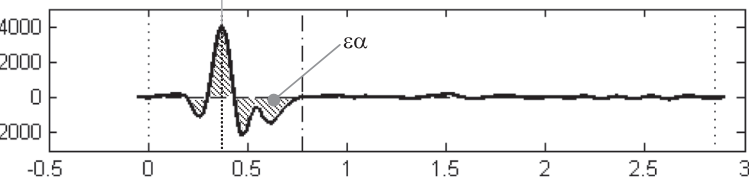


41 yr old ABI patient-high tone (MAS=3)

Angle (deg) - Extension trial

 $\Delta\omega$ Velocity difference (deg/s) $\Delta\alpha$ Acceleration difference (deg/s²)

Antagonist EMG - Raw (biased removed)

