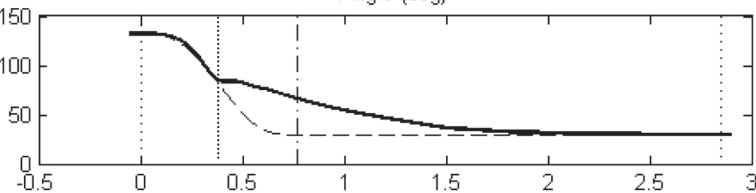
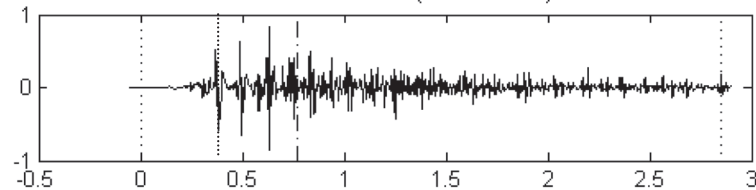


41 yr old ABI patient-high tone (MAS=3)

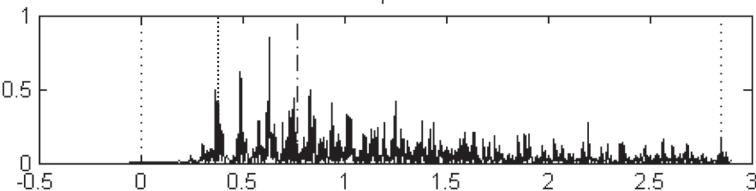
Angle (deg)



Flexor EMG - Raw (bias removed)



Flexor EMG - Band-pass filtered & rectified



Flexor EMG - Low pass filtered

