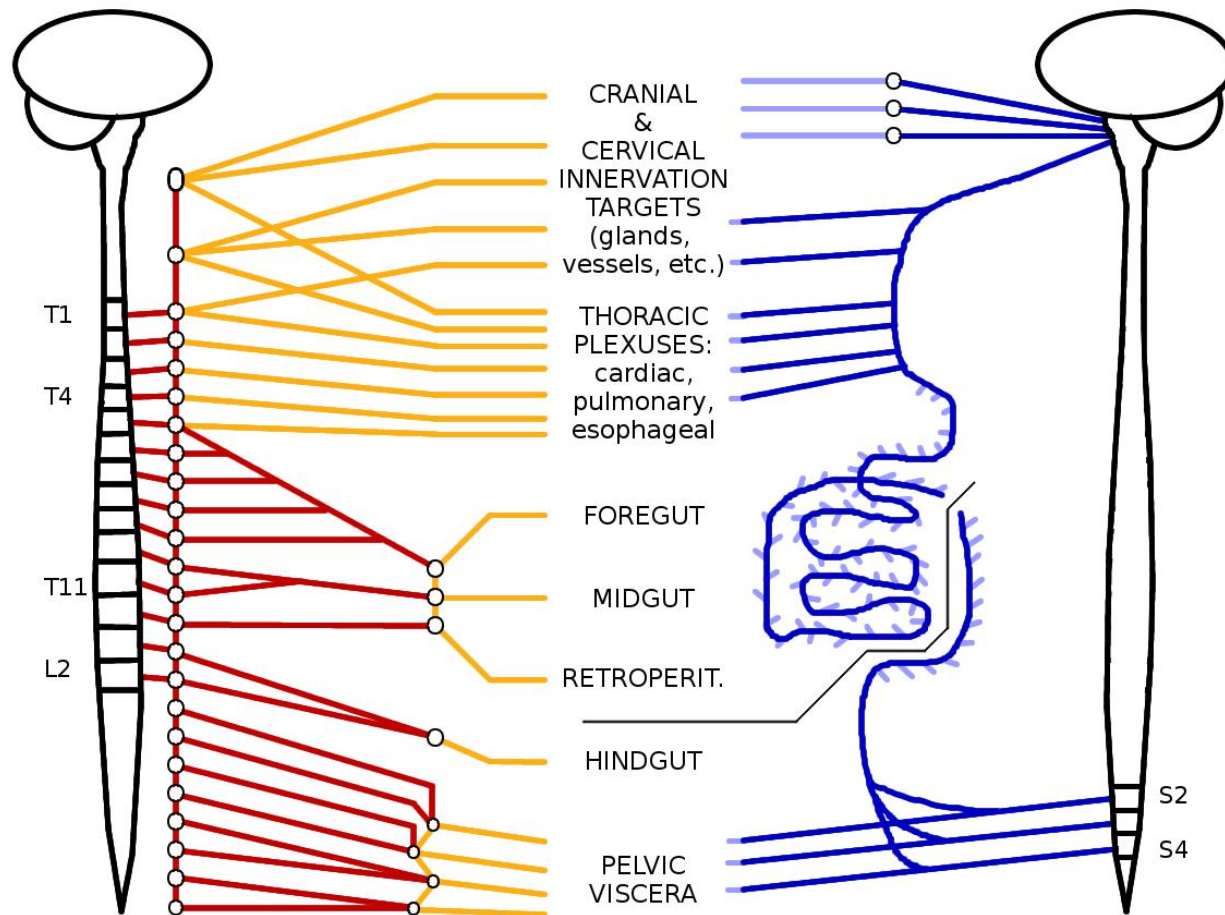


# Review of Thoracic and Abdominal Autonomics - Sept 2015

SYMPATHETICS

Matt Wedel, PhD

PARASYMP.



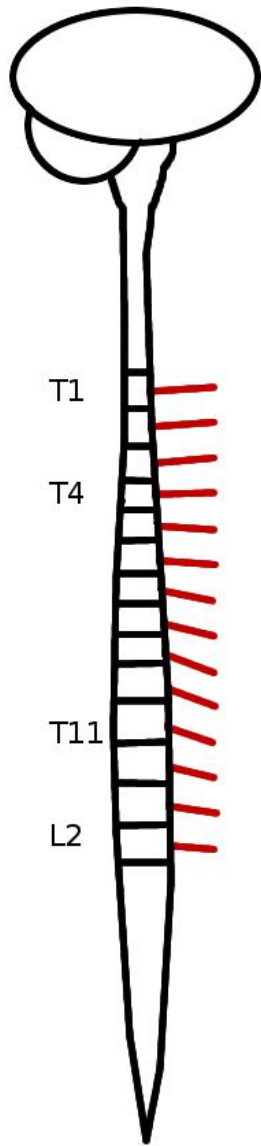
Presynaptic fibers ———

Postsynaptic fibers ———

Presynaptic fibers ———

Postsynaptic fibers ———

# SYMPATHETICS



Presynaptic fibers ———

Keep in mind that the nervous system includes 3 fundamental types of neurons:

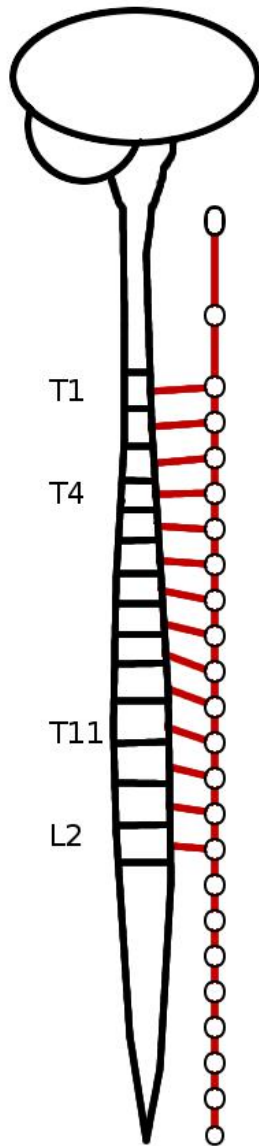
1. Sensory (**afferent**) neurons that connect to sensory receptors;
2. Motor (**efferent**) neurons that connect to effector organs (muscles and glands)
3. Interneurons that connect other neurons together.

Sensory and motor neurons can be further divided into **somatic** neurons that go to the body wall and limbs and are mainly responsible for conscious phenomena, and **visceral** neurons that go to internal organs, blood vessels, and the glands and hairs of our skin, which are responsible for involuntary phenomena.

Our autonomic nervous system is **visceral** (involuntary) and **efferent** (motor). The two types of autonomic pathways are sympathetic (“fight or flight”) and parasympathetic (“feed and breed”).

We'll start with sympathetic pathways. The presynaptic fibers emerge from the spinal cord between the T1 and L2 levels.

# SYMPATHETICS



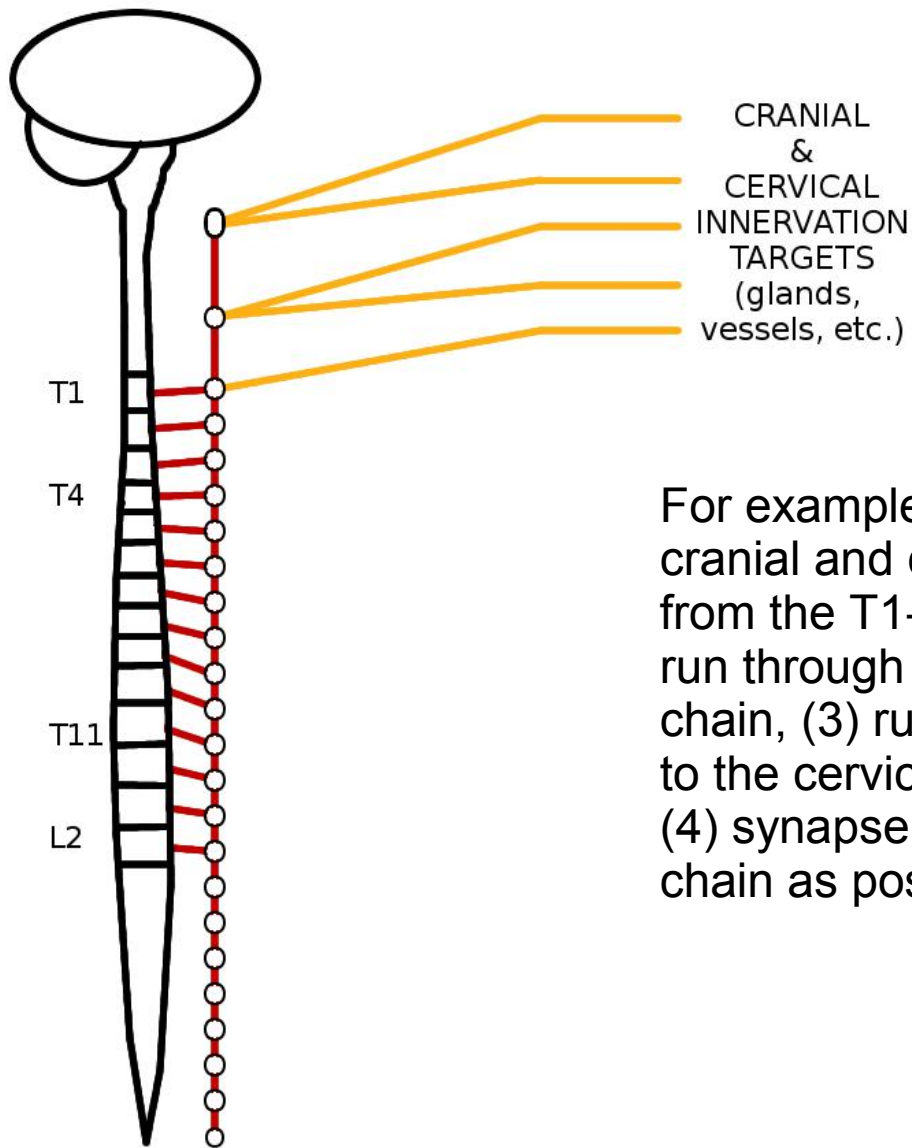
The presynaptic fibers run from the spinal cord into the sympathetic chain, a line of *paravertebral* (= adjacent to the vertebrae) ganglia connected by vertical pathways—the sympathetic trunk. White rami communicantes connect the sympathetic chain to the spinal nerves—axons pass through these rami to get into the chain.

The chain runs from just below the skull to just in front of the S5 vertebra, with a pair of ganglia at almost every vertebral level (fewer in the neck).

Once in the chain, axons may ascend or descend vertically through the trunk before they exit. This is absolutely required for those axons going to cranial, cervical, and pelvic structures.

Presynaptic fibers —————

# SYMPATHETICS



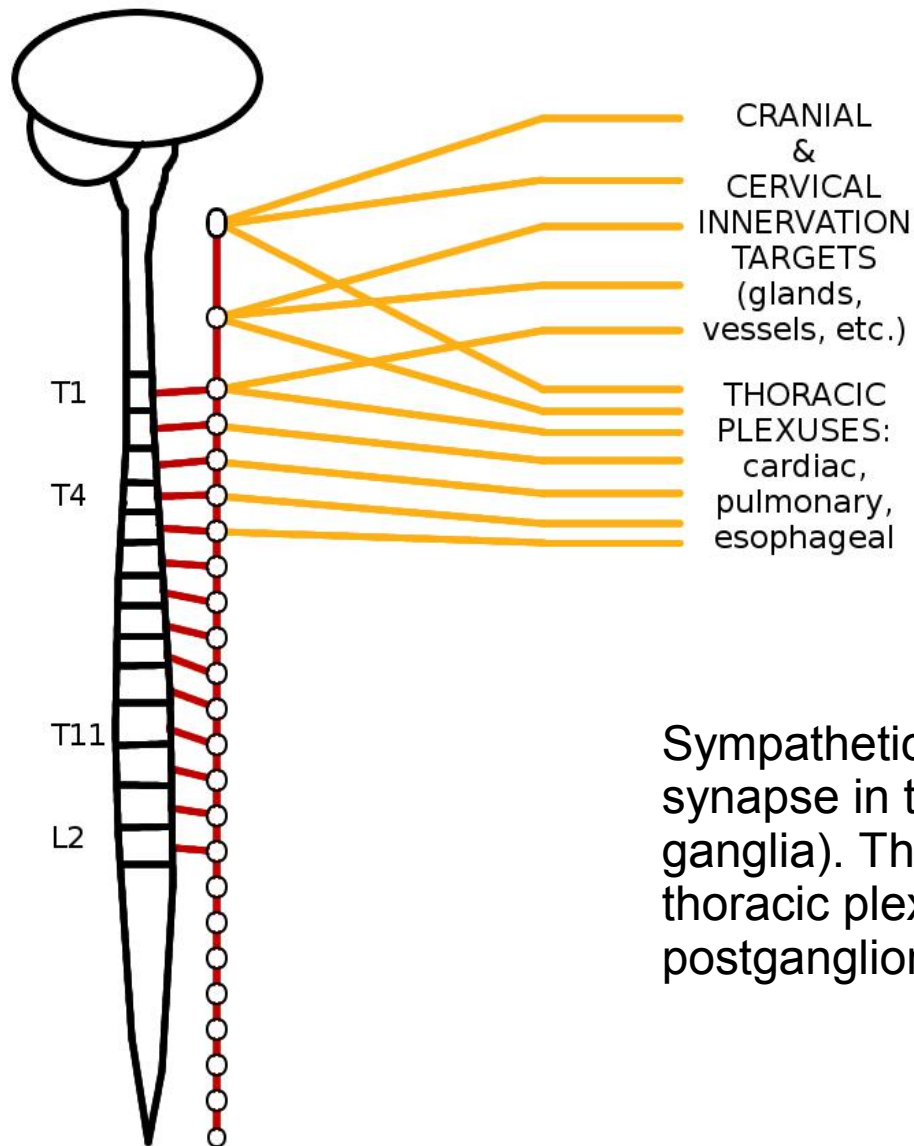
CRANIAL  
&  
CERVICAL  
INNERVATION  
TARGETS  
(glands,  
vessels, etc.)

For example, sympathetic pathways to cranial and cervical targets (1) originate from the T1-T4 levels of the spinal cord, (2) run through white rami into the sympathetic chain, (3) run superiorly through the trunk to the cervical sympathetic chain ganglia, (4) synapse there, and (5) run out of the chain as postsynaptic fibers.

Presynaptic fibers ———

Postsynaptic fibers ———

# SYMPATHETICS

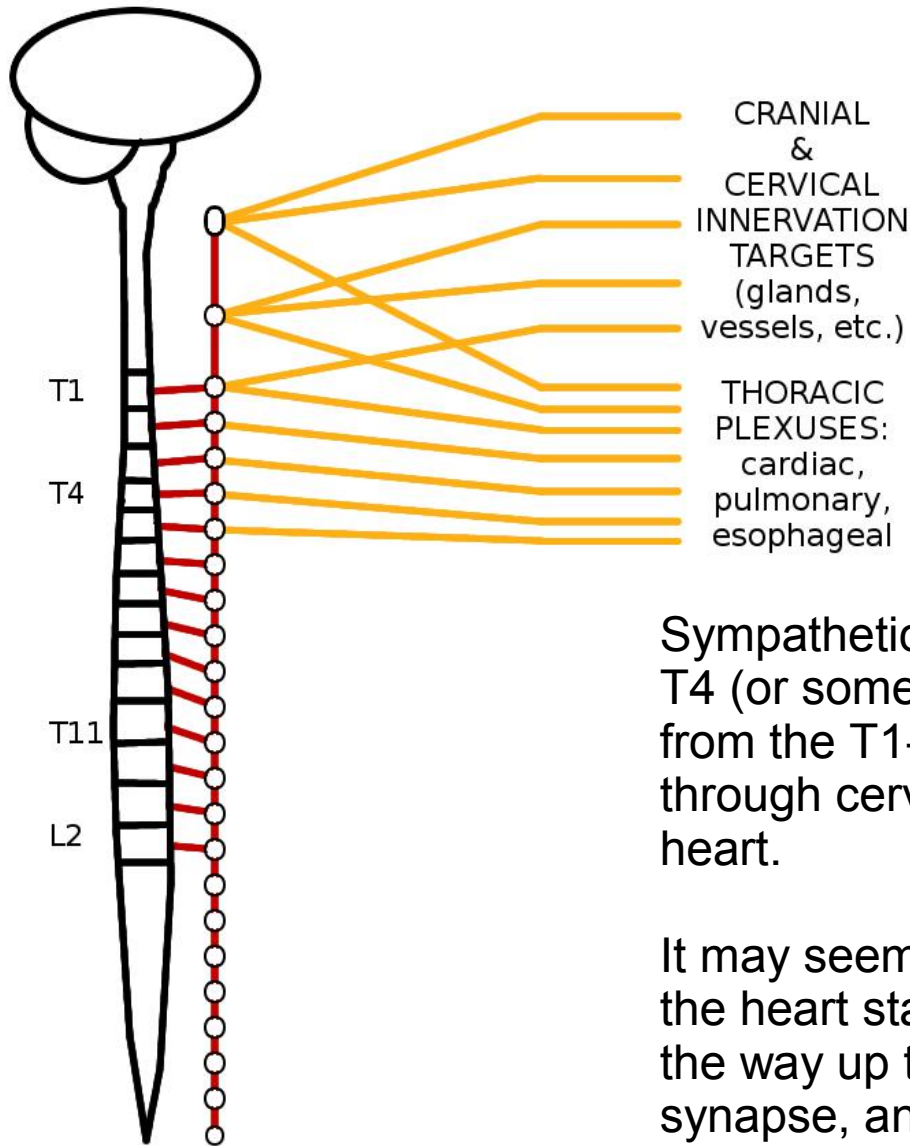


Sympathetic pathways to thoracic viscera also synapse in the sympathetic chain (paravertebral ganglia). The sympathetic fibers that run in the thoracic plexuses are postsynaptic (= postganglionic).

Presynaptic fibers ———

Postsynaptic fibers ———

# SYMPATHETICS



CRANIAL & CERVICAL INNERVATION TARGETS (glands, vessels, etc.)

THORACIC PLEXUSES: cardiac, pulmonary, esophageal

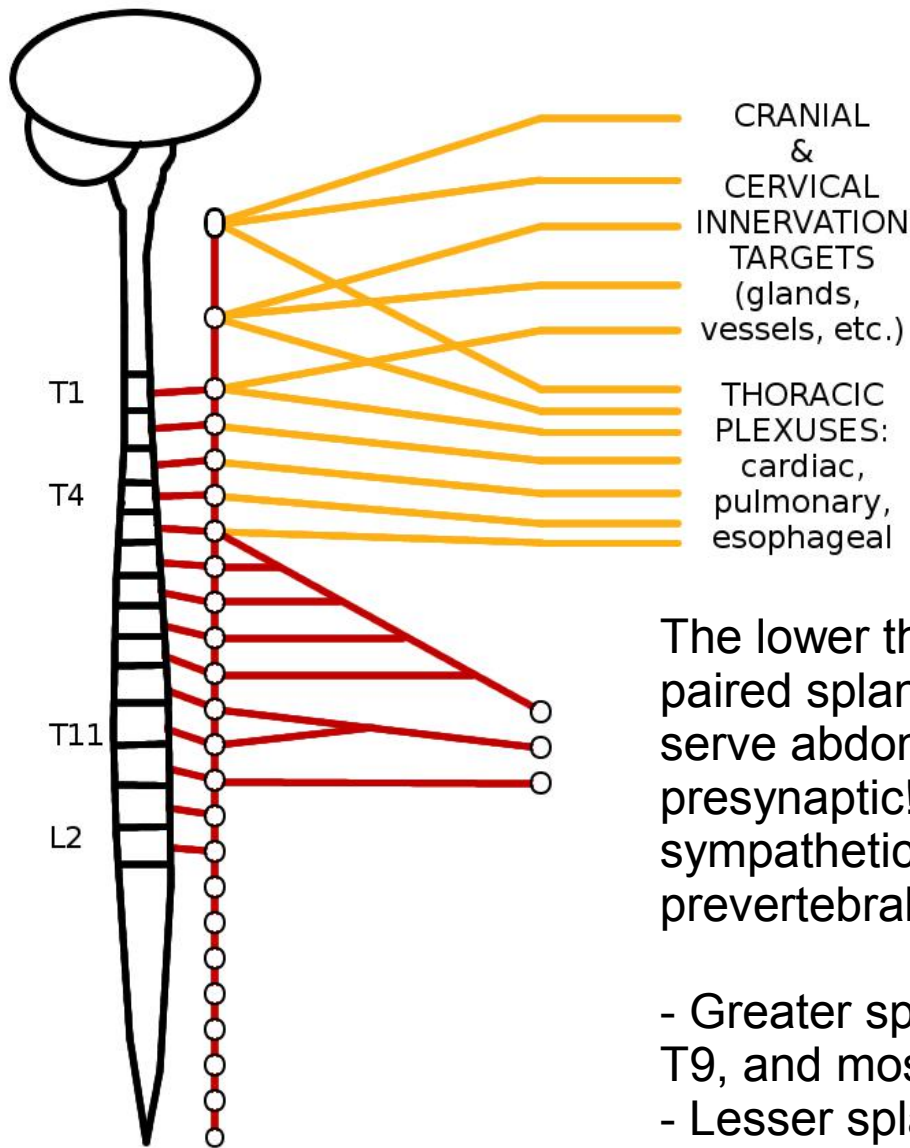
Sympathetics to the heart originate from the T1-T4 (or sometimes T5) spinal levels, but not only from the T1-T4 chain ganglia—some pass through cervical ganglia on their way to the heart.

It may seem odd that some of the pathways to the heart start in the thoracic spinal cord, run all the way up to the superior cervical ganglion, synapse, and then descend again into the thorax. This is a holdover from when the heart was tucked up underneath the brain in early embryonic development—like the course of the recurrent laryngeal nerve, but in reverse.

Presynaptic fibers ———

Postsynaptic fibers ———

# SYMPATHETICS



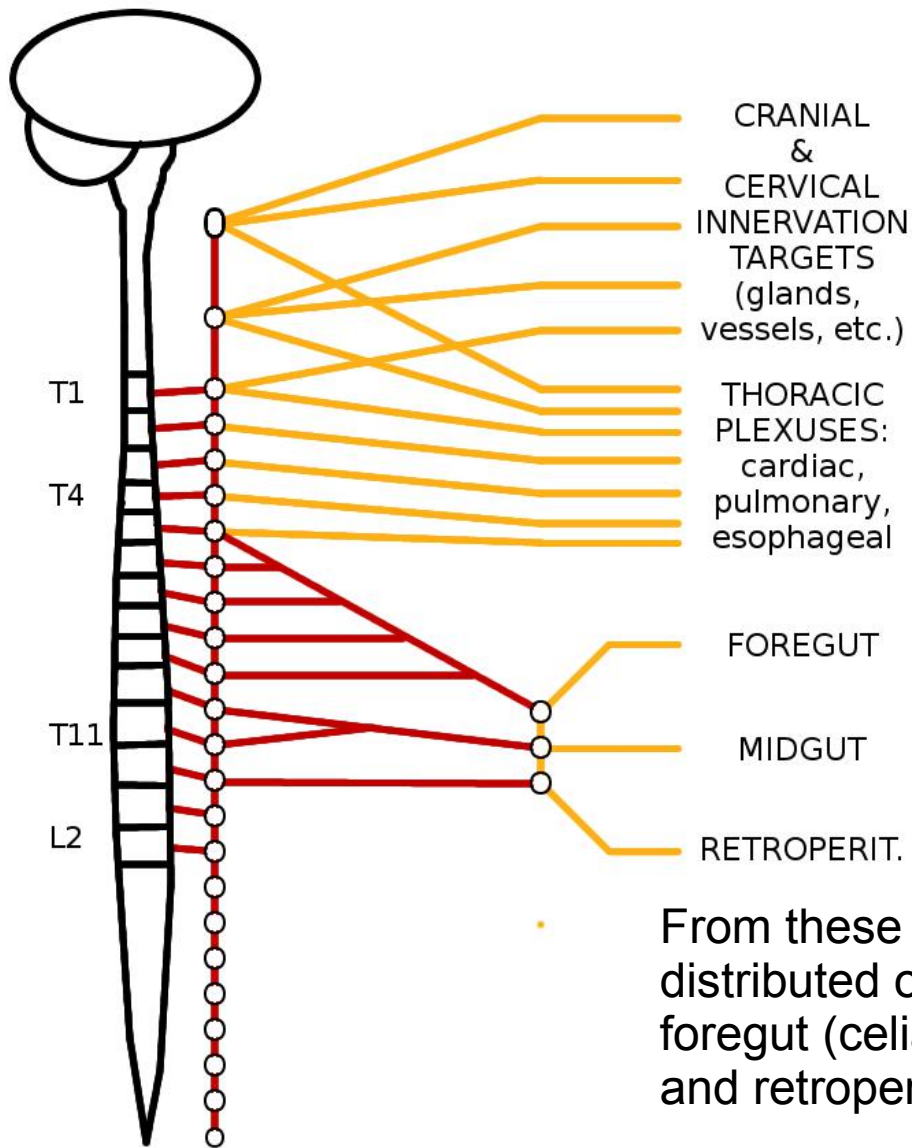
Presynaptic fibers ————

Postsynaptic fibers ————

The lower thoracic levels also give rise to paired splanchnic nerves that are going to serve abdominal viscera. These nerves are presynaptic! They did not synapse in the sympathetic chain. Instead they synapse in prevertebral ganglia (= preaortic ganglia).

- Greater splanchnic nerves originate from T5-T9, and mostly synapse in the **celiac ganglion**;
- Lesser splanchnic nerves come from T10-T11, and mostly synapse in the **superior mesenteric ganglion**;
- Least splanchnic nerves from T12, and mostly synapse in the paired **aorticorenal ganglia**.

# SYMPATHETICS



Presynaptic fibers ————

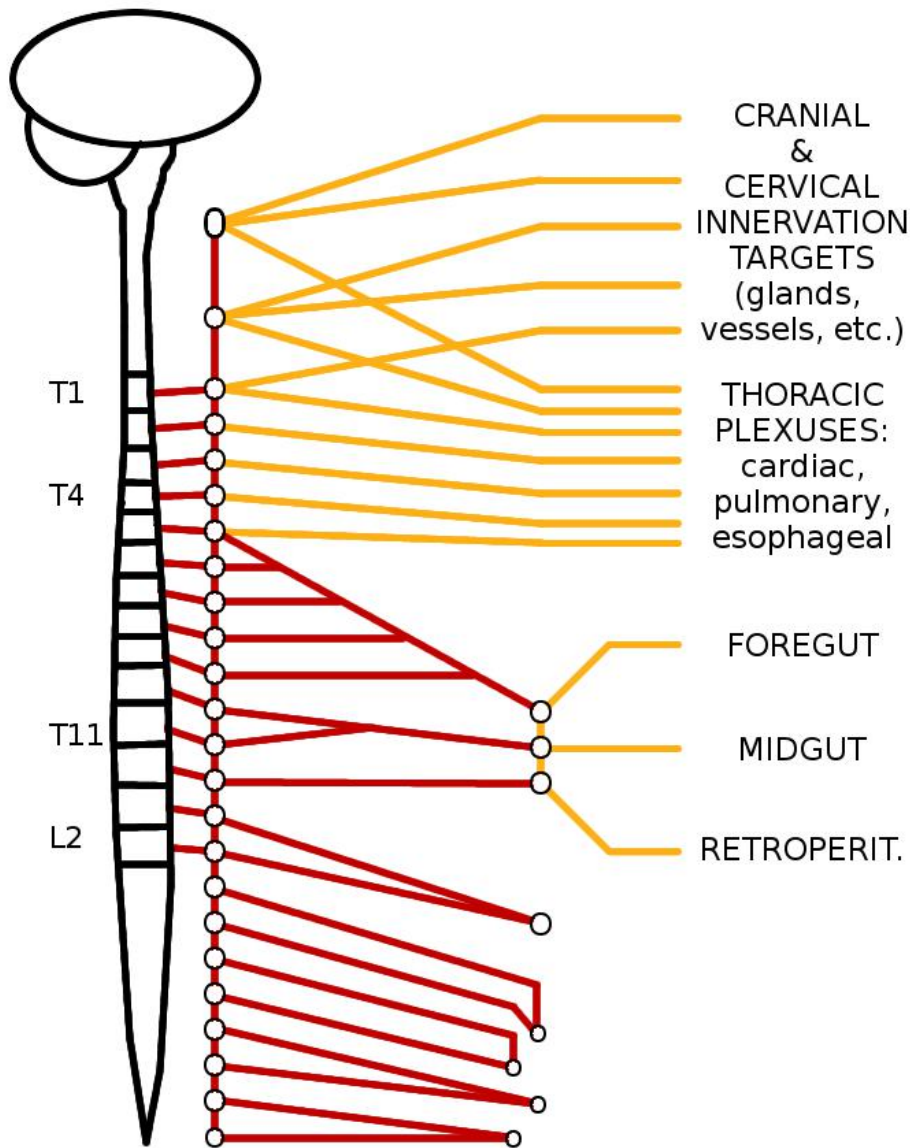
Postsynaptic fibers ————

From these ganglia, postsynaptic fibers are distributed on the major arteries to targets in the foregut (celiac), midgut (superior mesenteric), and retroperitoneal (aorticorenal) viscera.

These vascular pathways can be quite long so the general rule that sympathetics have short presynaptic fibers and long postsynaptic ones is still mostly true.



# SYMPATHETICS



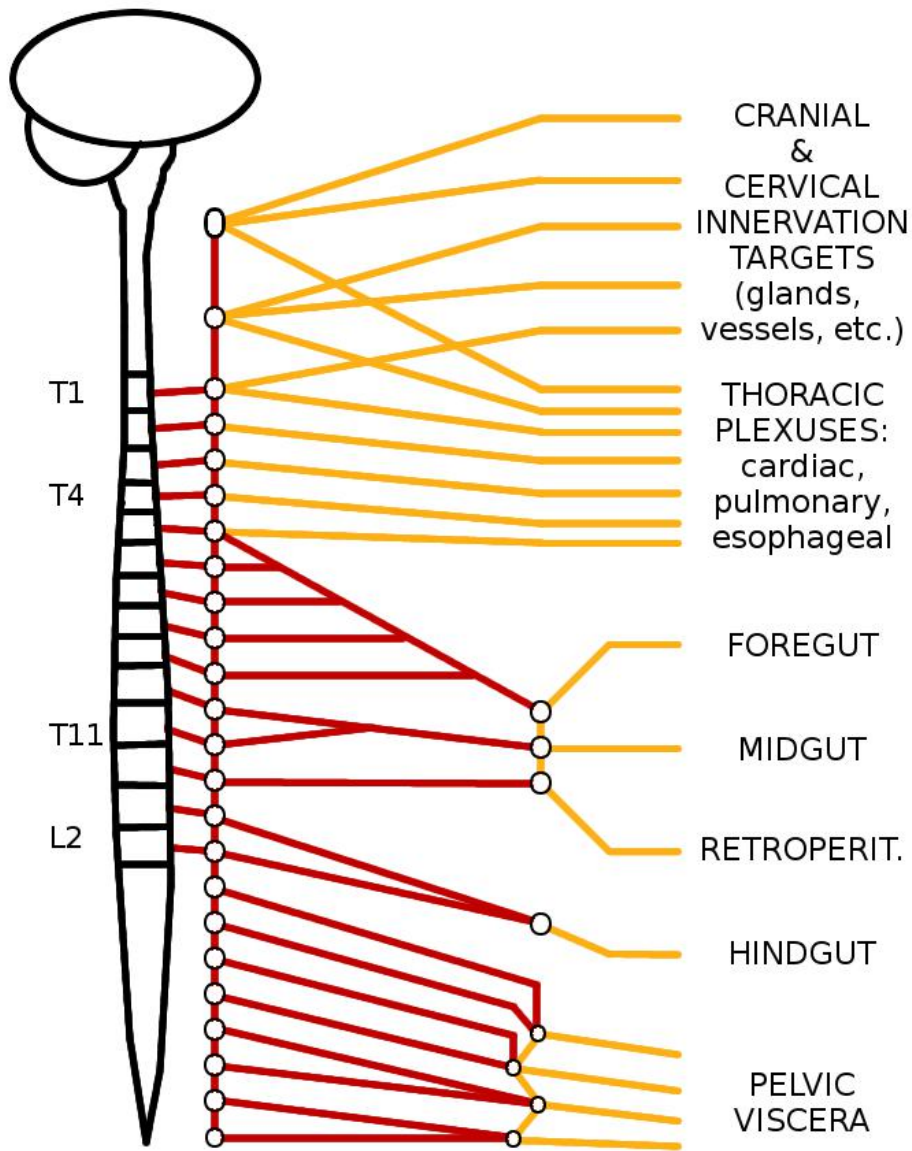
Presynaptic fibers ————

Postsynaptic fibers ————

The lumbar and sacral parts of the chain also give rise to splanchnic nerves. The upper lumbar splanchnics (L1-L2 especially) travel to the **inferior mesenteric ganglion**, whereas the lower lumbar and sacral splanchnic nerves travel to groups of tiny **pelvic ganglia** embedded in the inferior hypogastric plexus, down inside the bowl of the pelvis.

Like the thoracic splanchnic nerves, these lumbar and sacral splanchnic nerves are still presynaptic.

# SYMPATHETICS

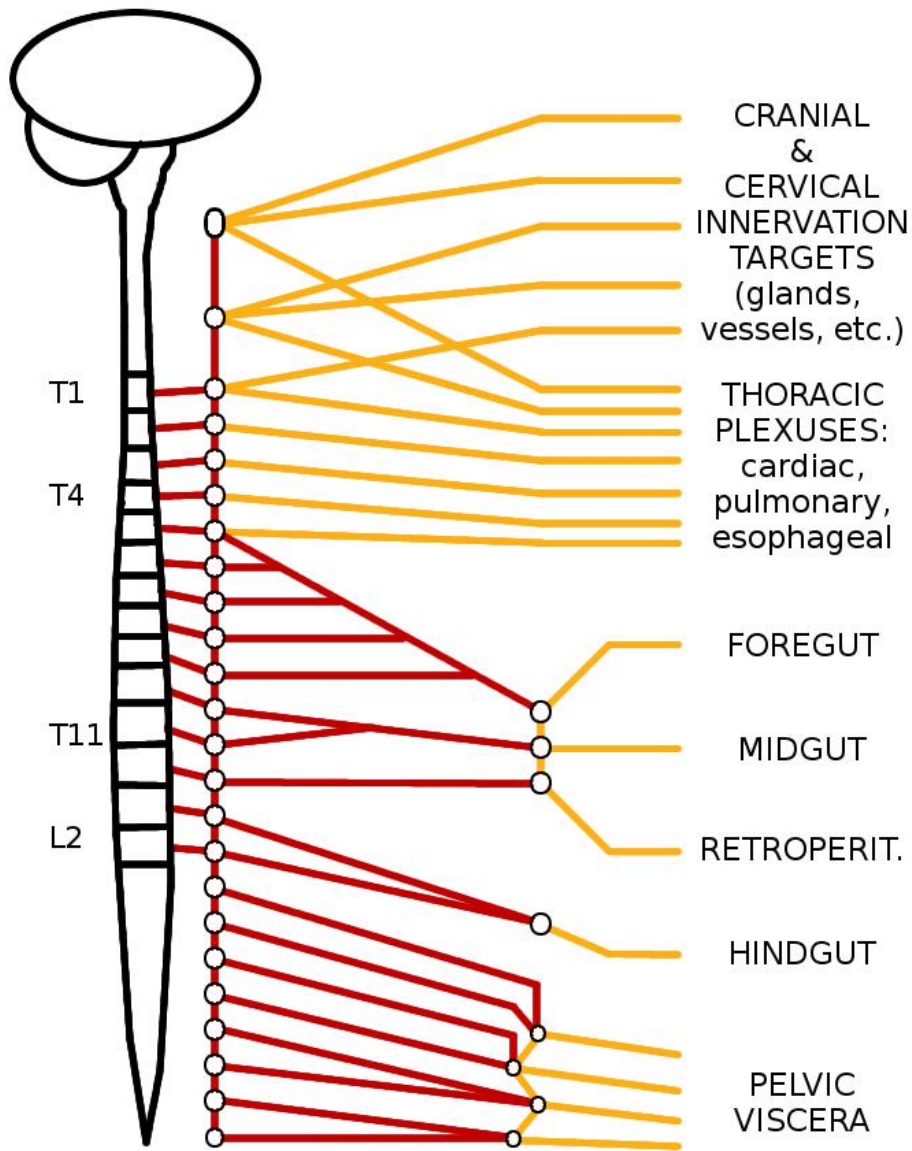


Presynaptic fibers ———

Postsynaptic fibers ———

As with the sympathetic pathways going through the thoracic splanchnic nerves, the postganglionic fibers are distributed from the prevertebral ganglia along vascular pathways to their target organs.

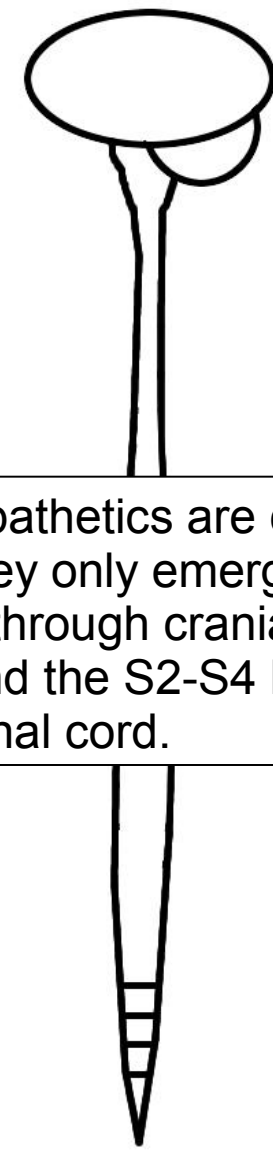
# SYMPATHETICS



Presynaptic fibers ———

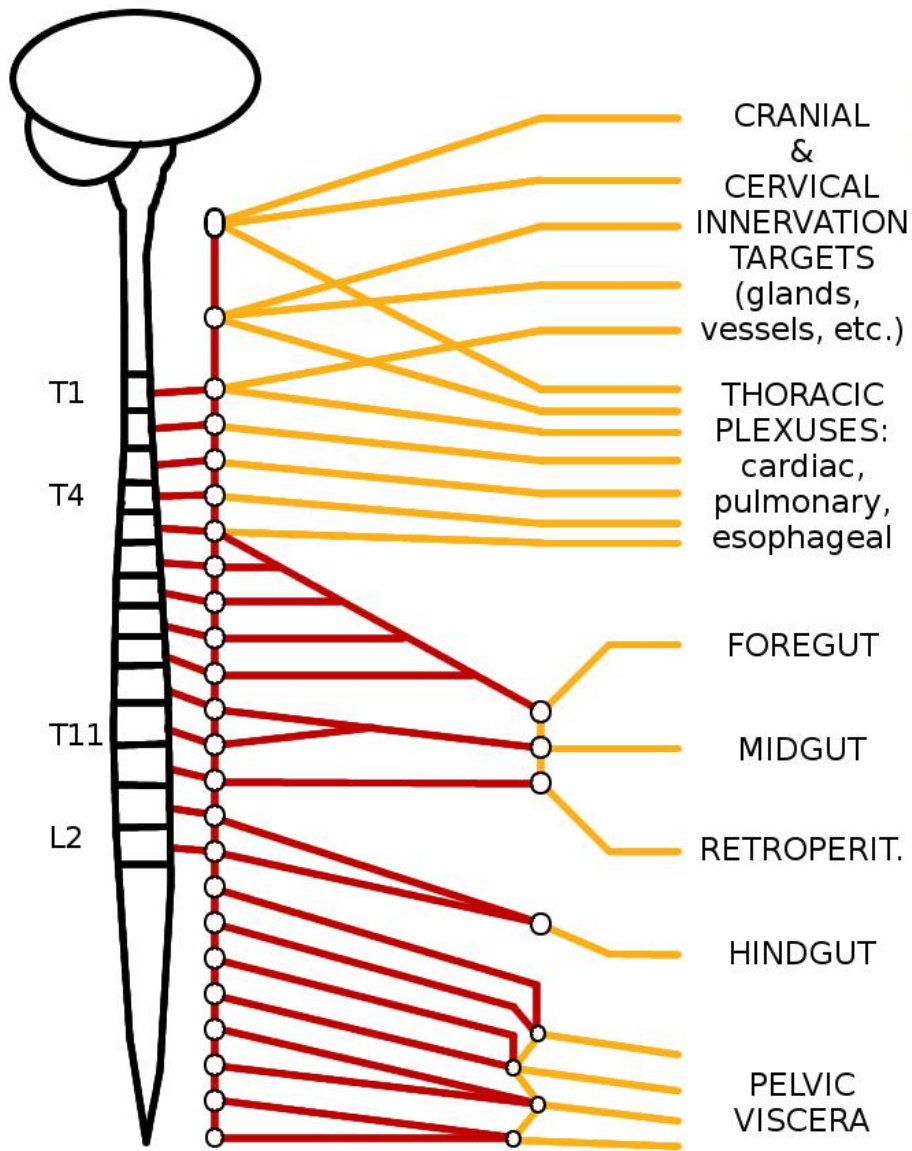
Postsynaptic fibers ———

# PARASYMP.



——— Presynaptic fibers

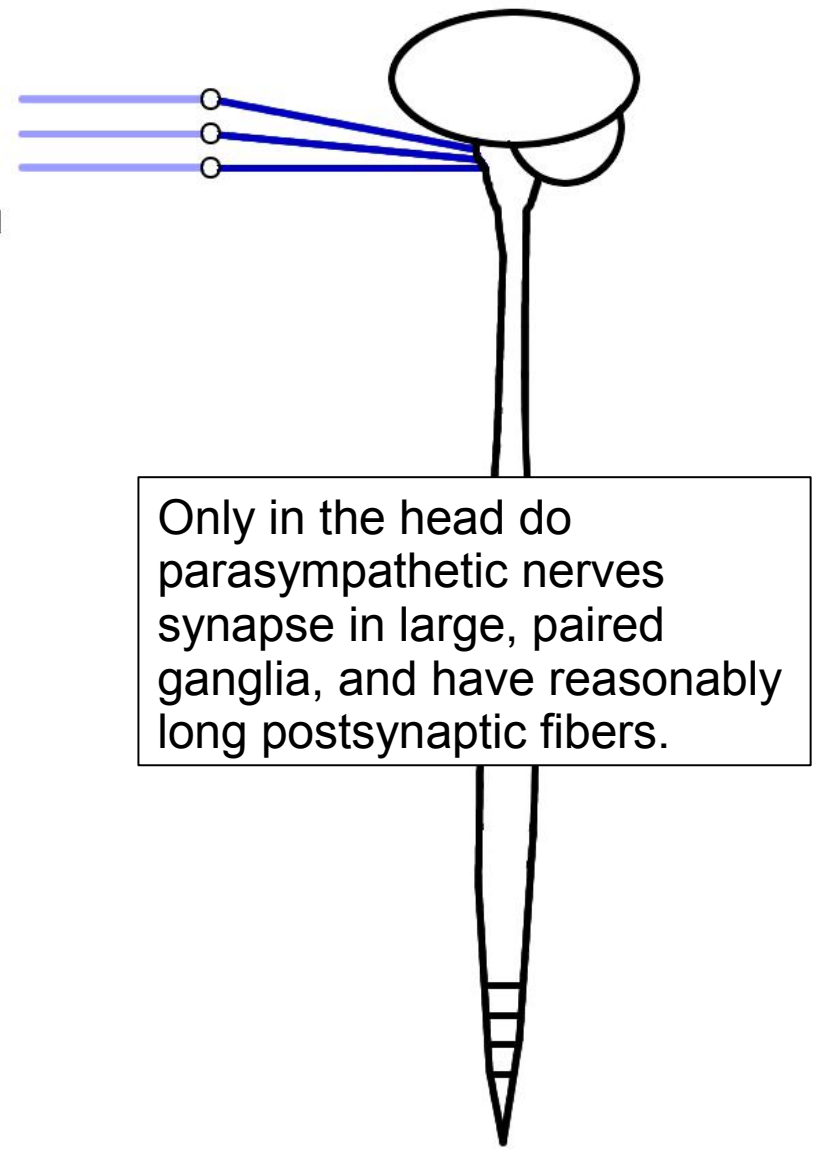
# SYMPATHETICS



Presynaptic fibers ————

Postsynaptic fibers ————

# PARASYMP.



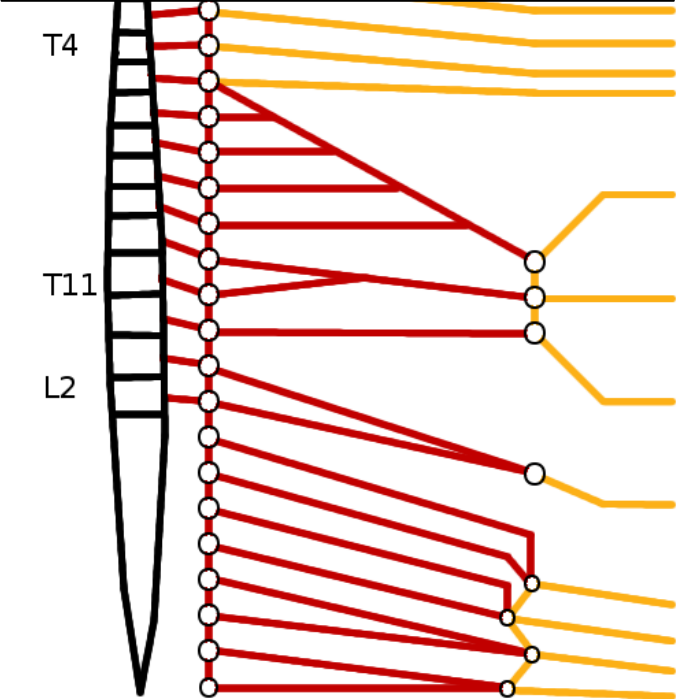
Presynaptic fibers ————

Postsynaptic fibers ————

# SYMPATHETICS

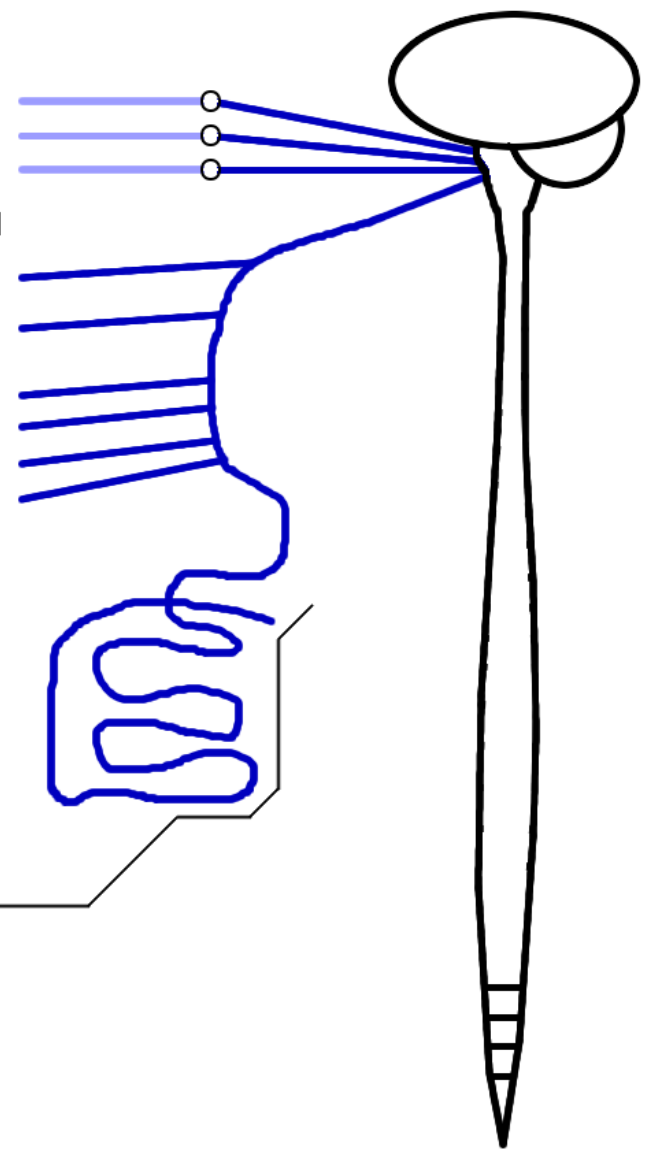
# PARASYMP.

Part of the neck, all of the thoracic viscera, and most of the abdominal viscera are served by the vagus nerves, which run down to the midgut/hindgut division and also innervate the gonads (not shown).



- CRANIAL & CERVICAL INNERVATION TARGETS (glands, vessels, etc.)
- THORACIC PLEXUSES: cardiac, pulmonary, esophageal
- FOREGUT
- MIDGUT
- RETROPERIT.
- HINDGUT
- PELVIC VISCERA

Presynaptic fibers ————  
 Postsynaptic fibers ————



Presynaptic fibers ————  
 Postsynaptic fibers ————

# SYMPATHETICS

# PARASYMP.

The hindgut, pelvic viscera, and perineum (minus the testes) are served by pelvic splanchnic nerves.

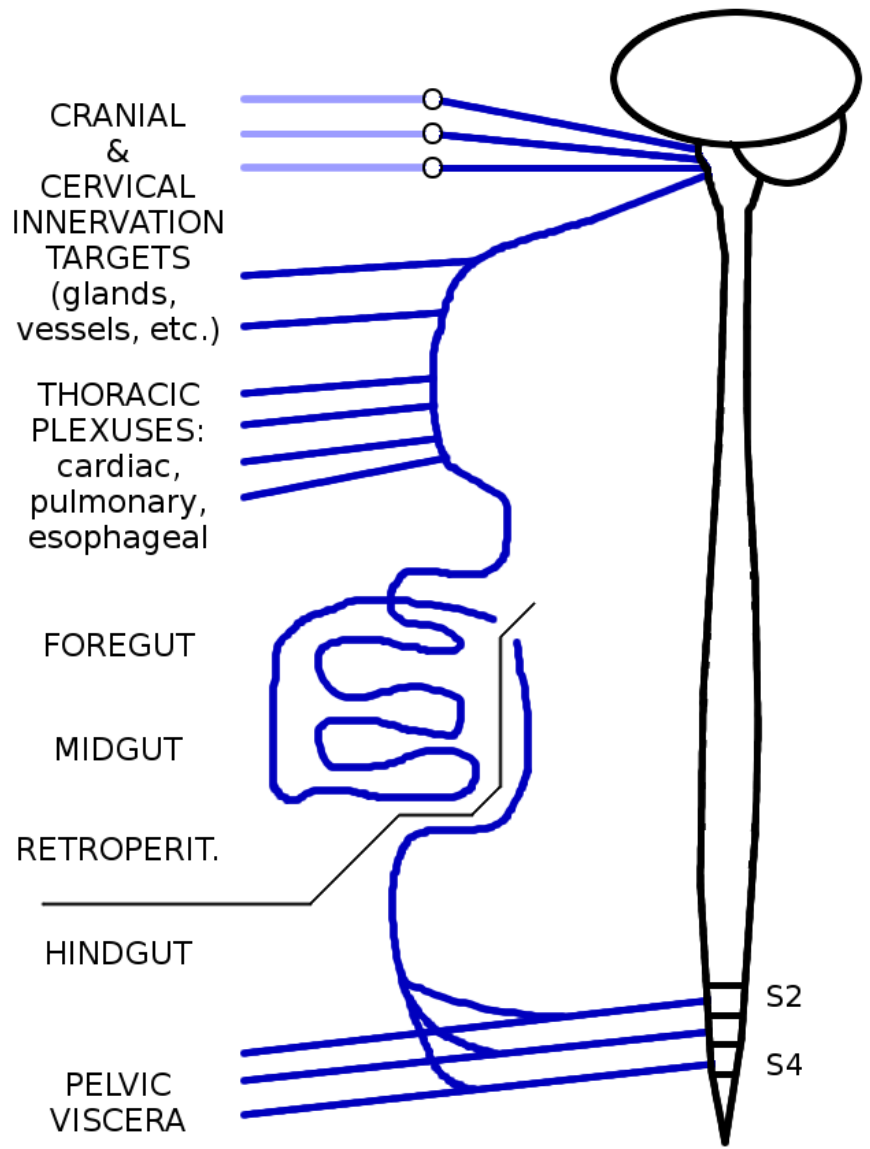
A useful trick is to remember that **S**acral splanchnics are **S**ympathetic, and **P**elvic splanchnics are **P**arasympathetic.

Oddly enough, some branches of the pelvic splanchnic nerves have to run *up* the superior hypogastric plexus to reach the upper parts of the hindgut (descending and sigmoid colon).



Presynaptic fibers ————

Postsynaptic fibers ————



——— Presynaptic fibers

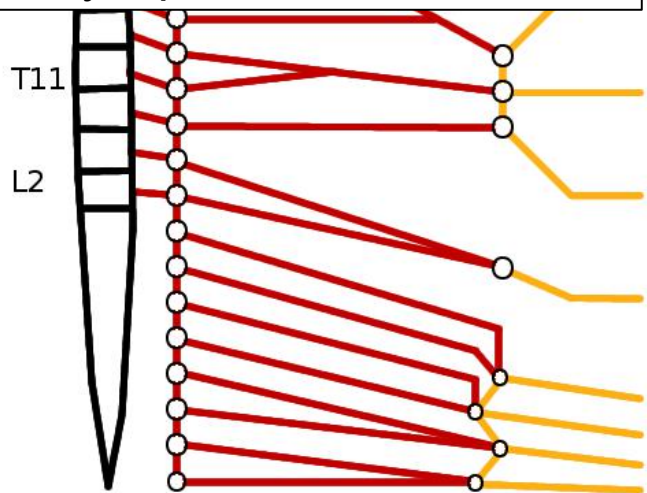
——— Postsynaptic fibers

# SYMPATHETICS

# PARASYMP.

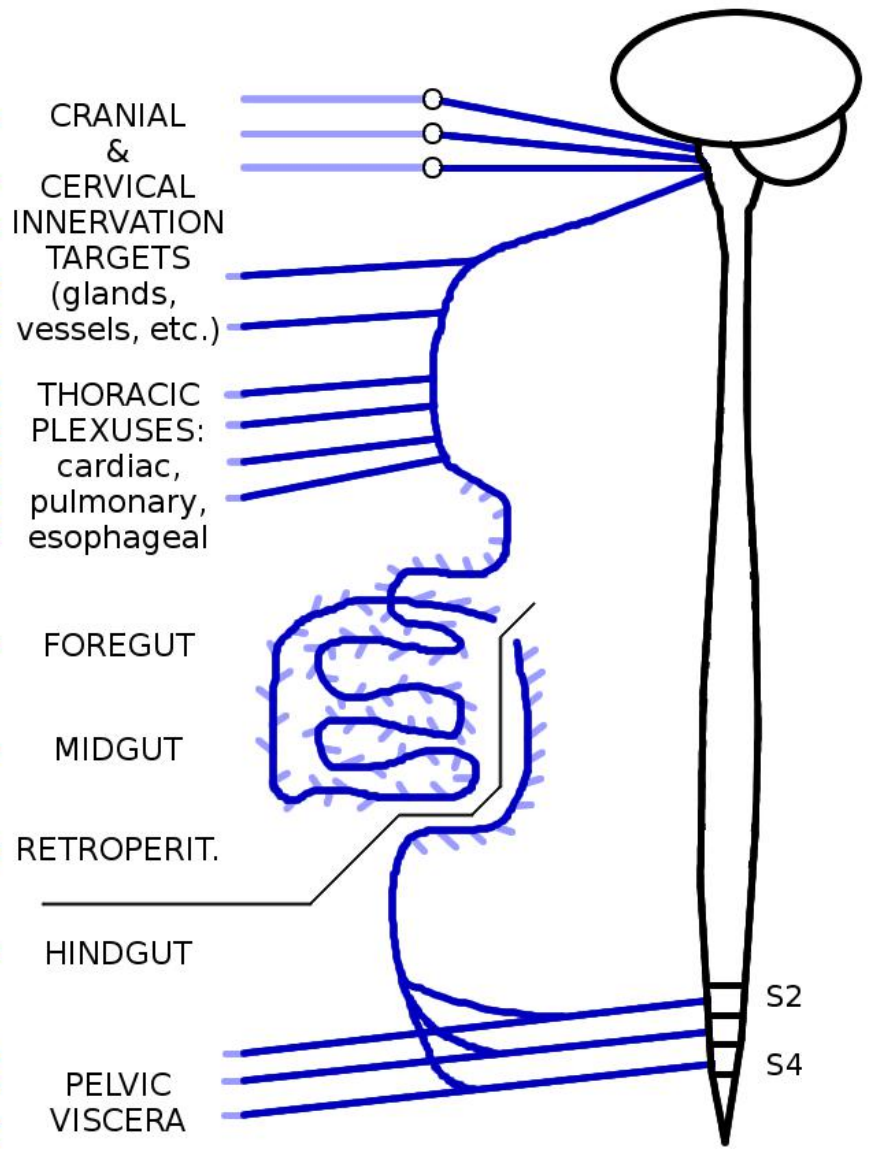
Outside the head, parasympathetic nerves synapse in tiny-to-microscopic ganglia on or near the walls of the target organs.

In other words, once you get outside the skull, if you can see a parasympathetic nerve with your naked eyes, it's presynaptic.



Presynaptic fibers ————

Postsynaptic fibers ————

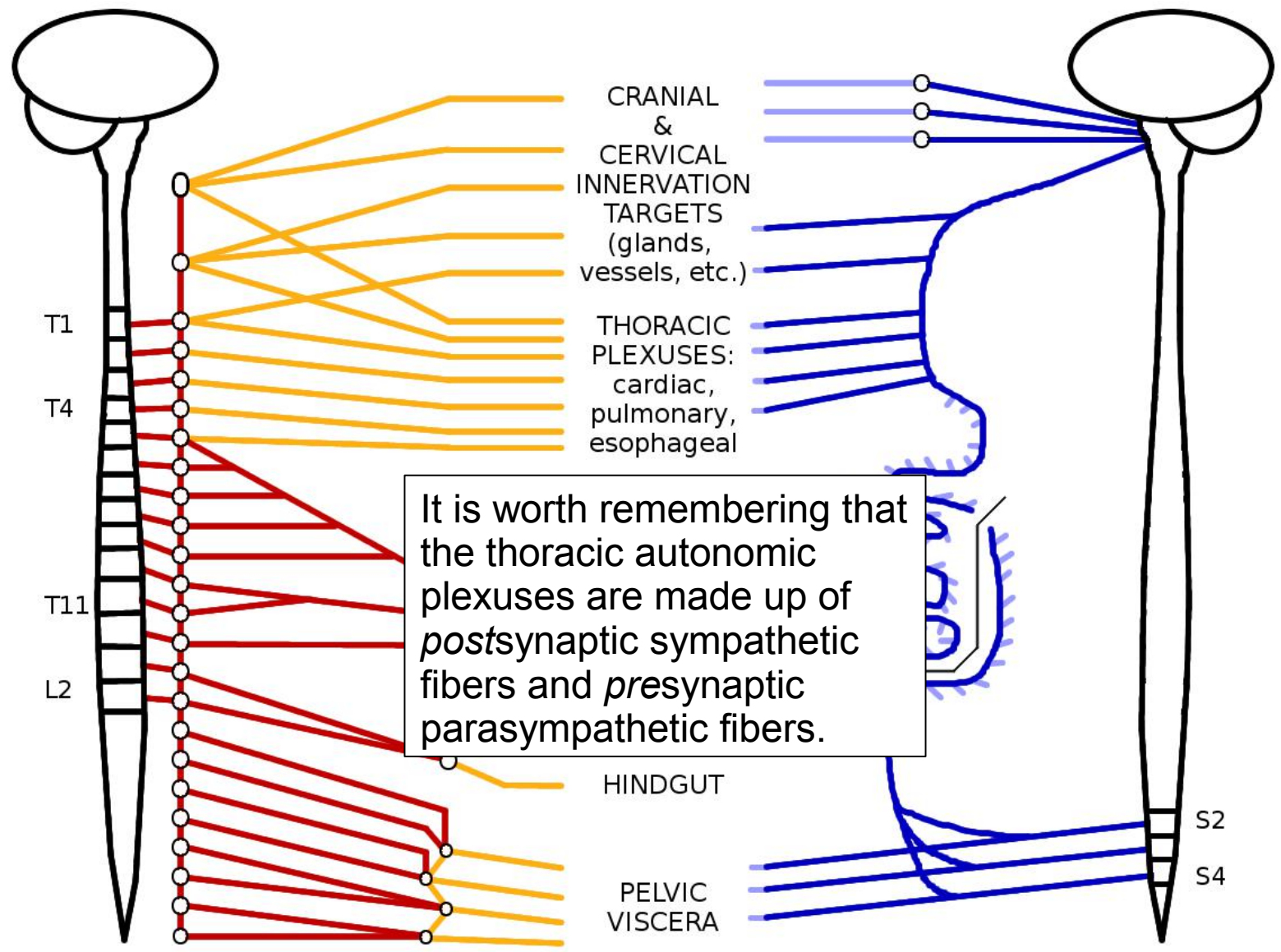


Presynaptic fibers ————

Postsynaptic fibers ————

# SYMPATHETICS

# PARASYMP.



It is worth remembering that the thoracic autonomic plexuses are made up of *postsynaptic* sympathetic fibers and *presynaptic* parasympathetic fibers.

Presynaptic fibers ———

Postsynaptic fibers ———

Presynaptic fibers ———

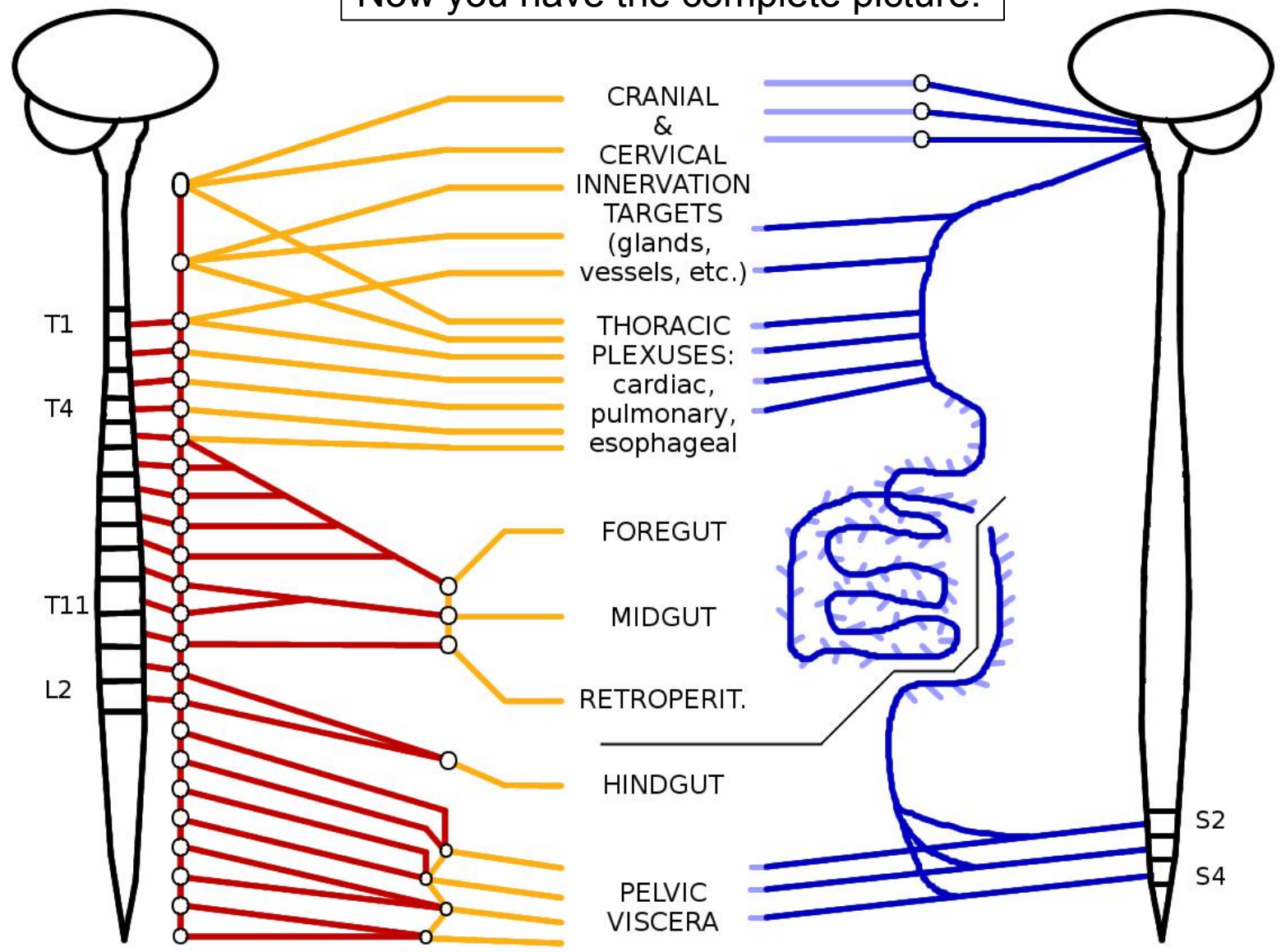
Postsynaptic fibers ———



# SYMPATHETICS

# PARASYMP.

Now you have the complete picture!



Presynaptic fibers ————

Postsynaptic fibers ————

Presynaptic fibers ————

Postsynaptic fibers ————